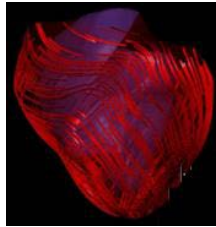


Echo Assessment of LV Function: What Are We Really Trying to Measure)



Jonathan R. Lindner, M.D.
M. Lowell Edwards Professor of Cardiology
Oregon Health & Science University
Portland, Oregon

1

Left Ventricle

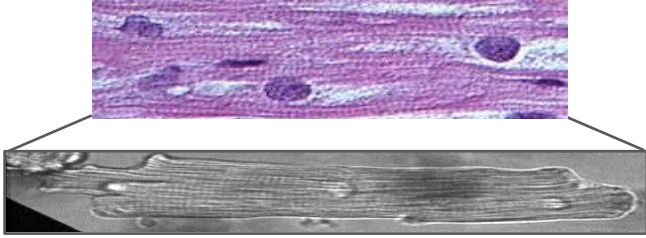


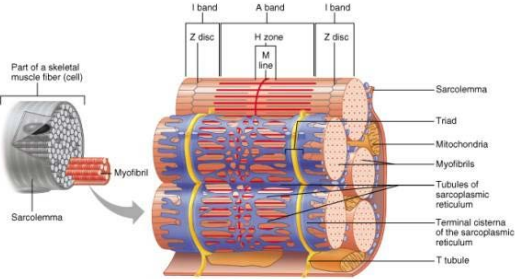
Right Ventricle



2

The Cardiomyocyte and LV Function





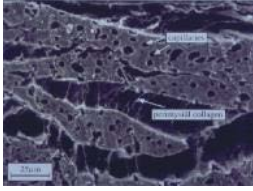

Copyright © 2001 Benjamin Cummings, an imprint of Addison Wesley Longman, Inc.



Dynamic Morphometrics

- Myocyte shortening: 15%
- Myocyte thickening: 8%
- Wall thickening: 40%
- Ejection Fraction: 60-70%

3

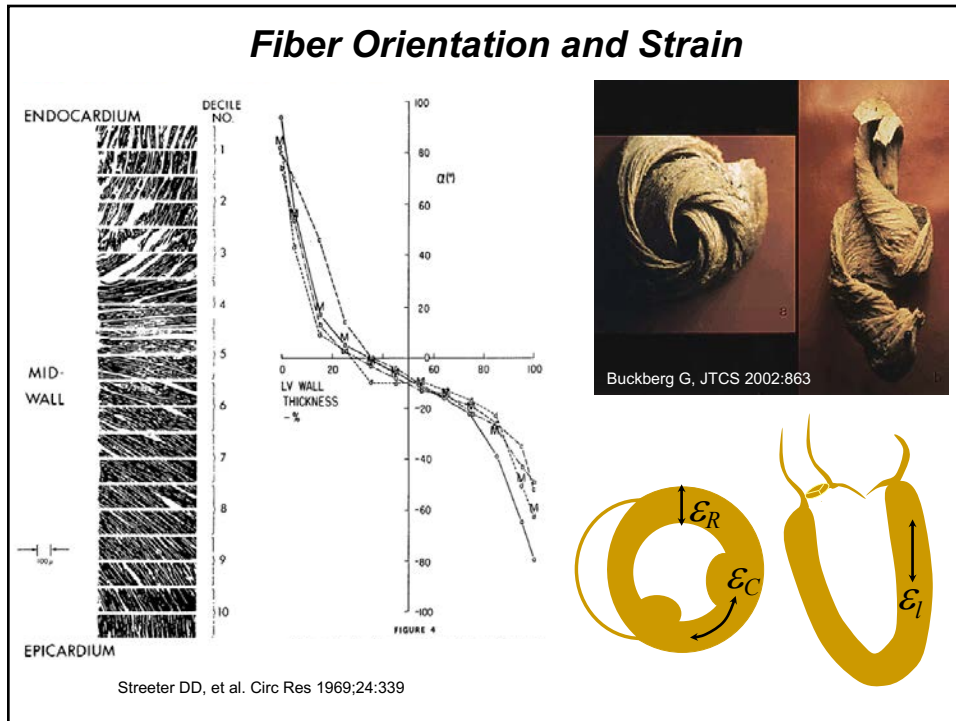
Myocardial Sheet Composition

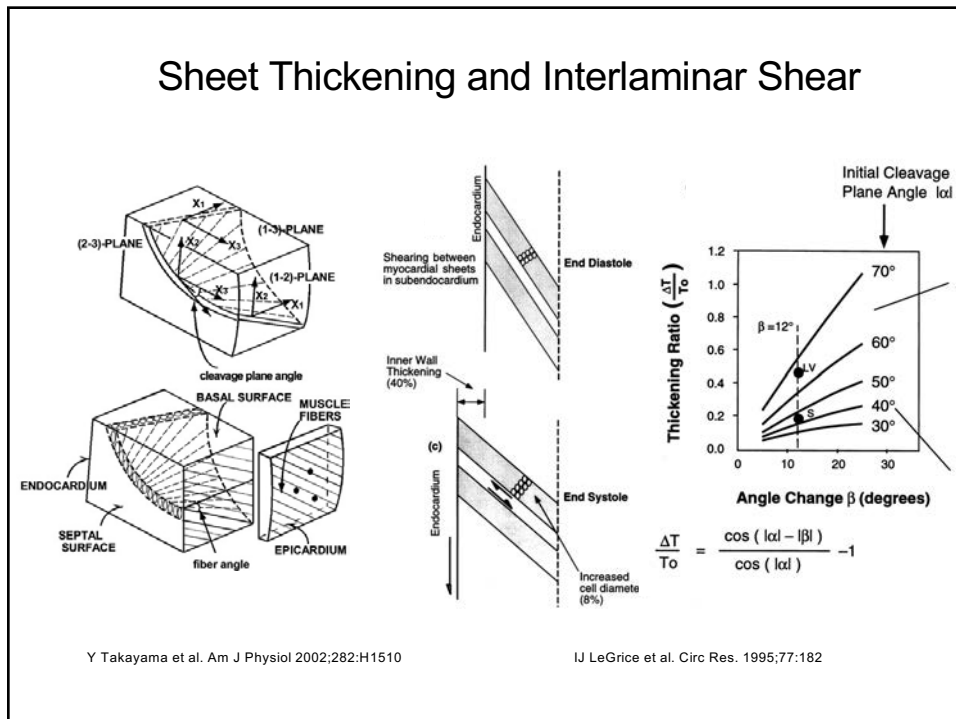



Young AA, et al., J Microsc 1998;191:131

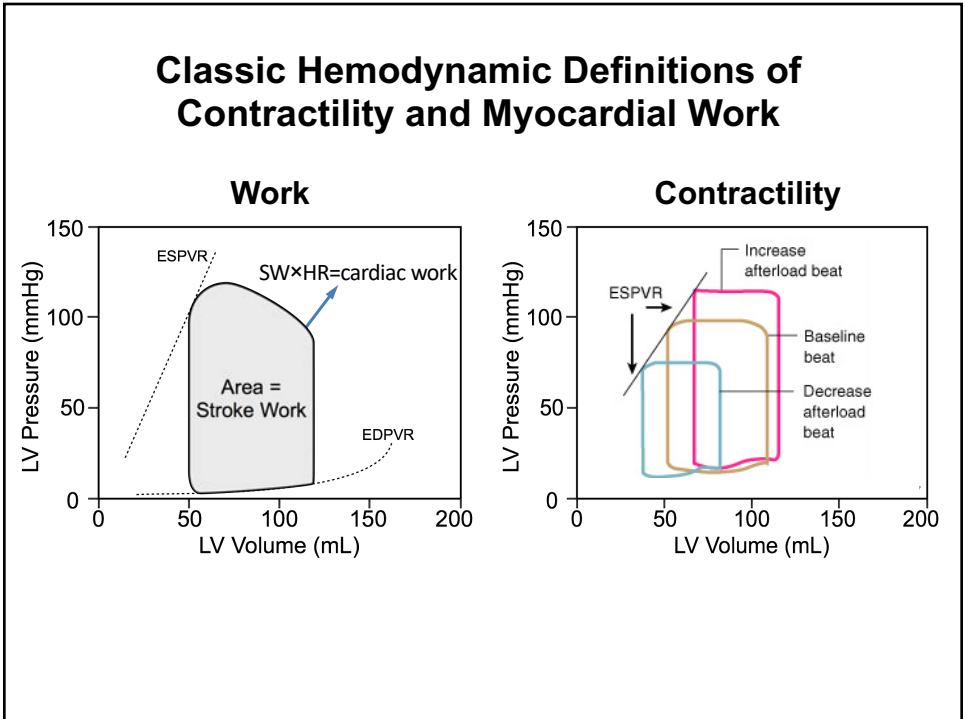
4



5



6



7

Echo Assessment of the Periodic Pump

| | |
|--|---|
| <p style="text-align: center;"><u>Muscle Squeeze</u></p> <ul style="list-style-type: none"> dp/dt Tissue Doppler VCF Strain Strain rate Isovolumic acceleration Torsion Twist | <p style="text-align: center;"><u>Volume</u></p> <ul style="list-style-type: none"> LVEF Shortening Fraction Stroke volume Stroke work (ESV-ESP relation) |
| <div style="background-color: #ffe6e6; display: inline-block; padding: 5px 20px; border: 1px solid black;"> “Myocardial work” </div> | |

8

Assessing LV Volumes and LVEF

ISSUES

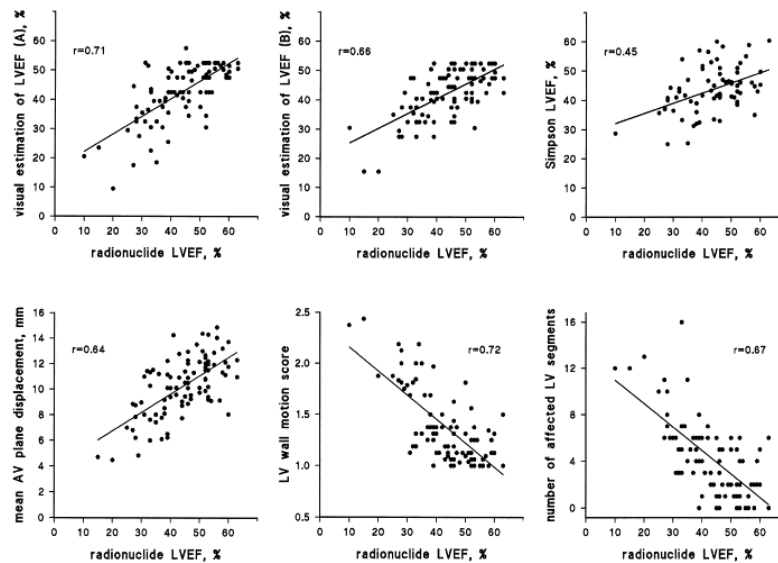
- Accuracy
- Reproducibility
- Ability to account for geometric distortions

2-D Simpson's Biplane - Limitations

- Two views only
- Foreshortening of the apex
- Endocardial definition
- Dealing with trabeculation

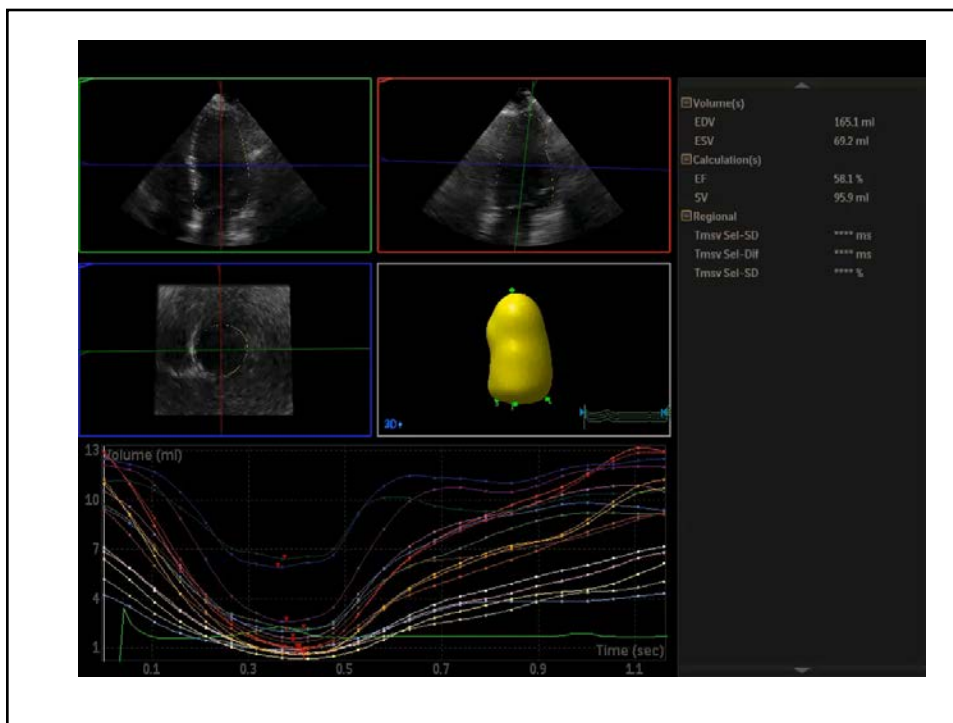
9

LVEF – A Messy Business

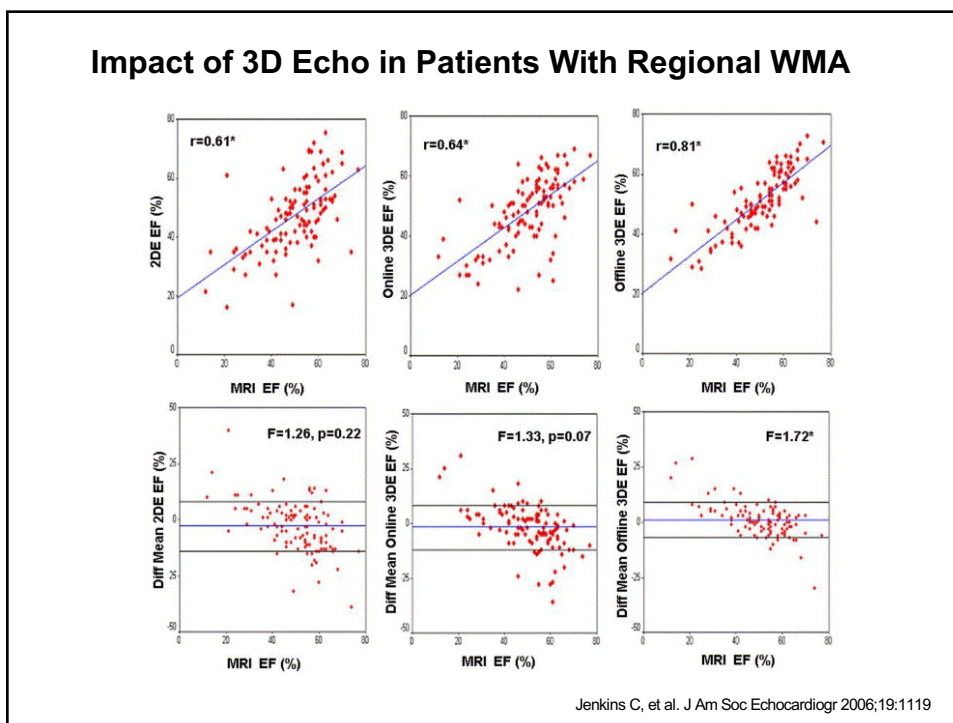


Jensen-Urstad K, et al. Am J Cardiol 1998;81:538

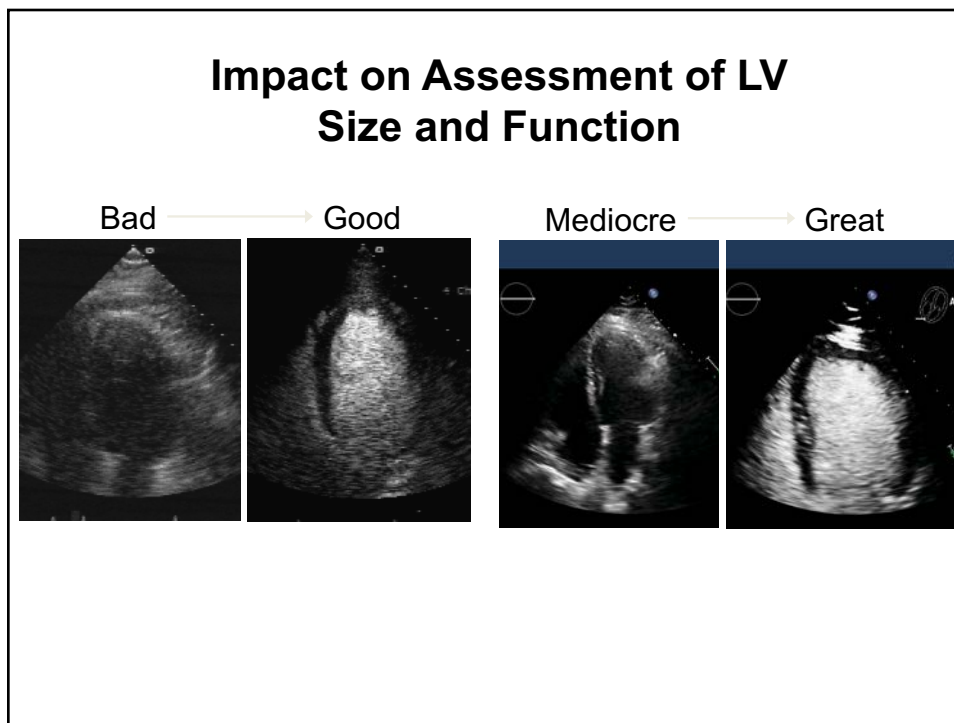
10



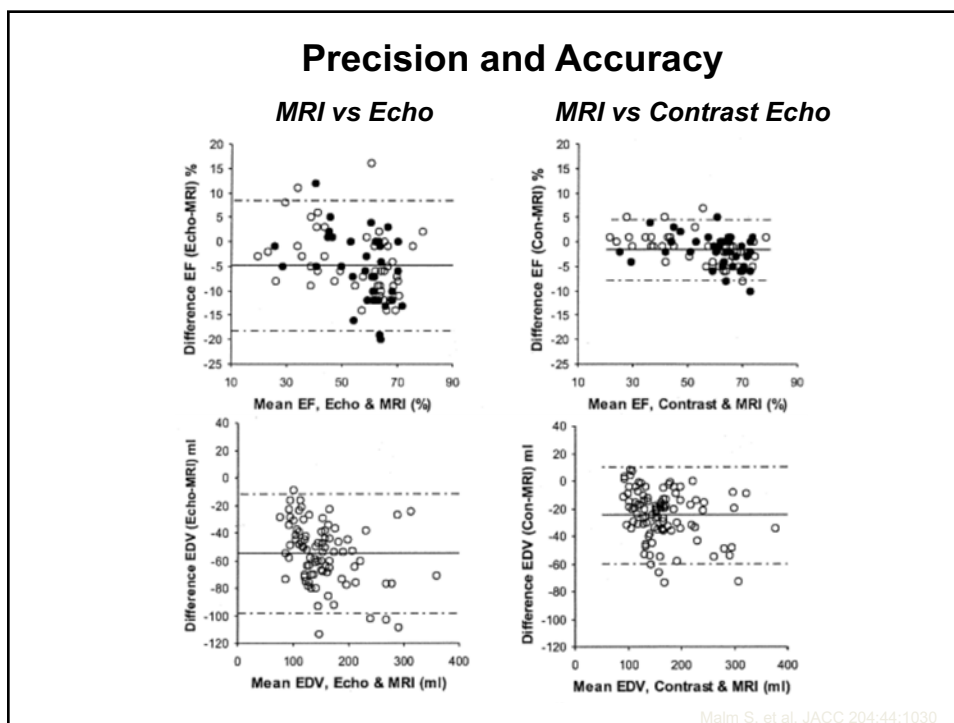
11



12



13



14

Echo Assessment of the Periodic Pump

Muscle Squeeze

dp/dt
Tissue Doppler
VCF
Strain
Strain rate
Isovolumic acceleration
Torsion
Twist

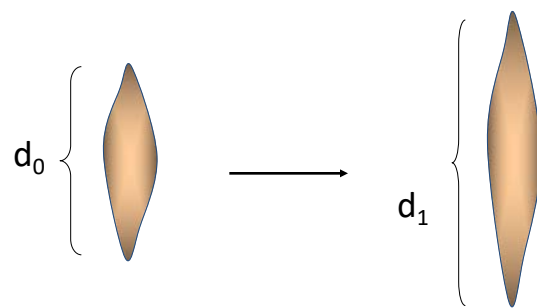
Volume

LVEF
Shortening Fraction
Stroke volume
Stroke work
(ESV-ESP relation)

“Myocardial work”

15

Strain and Strain Rate Imaging

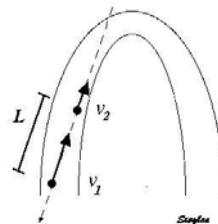
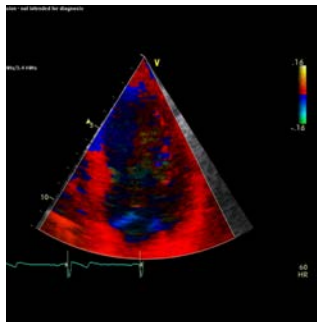
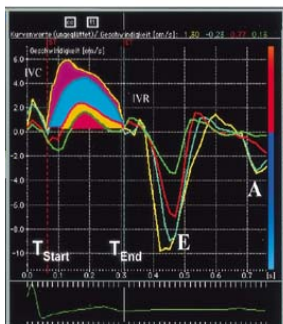


$$\text{Deformation} = d_1 - d_0 \quad \text{Strain} = \frac{d_1 - d_0}{d_0}$$

$$\text{Strain rate} = \text{strain}/\text{time}$$

16

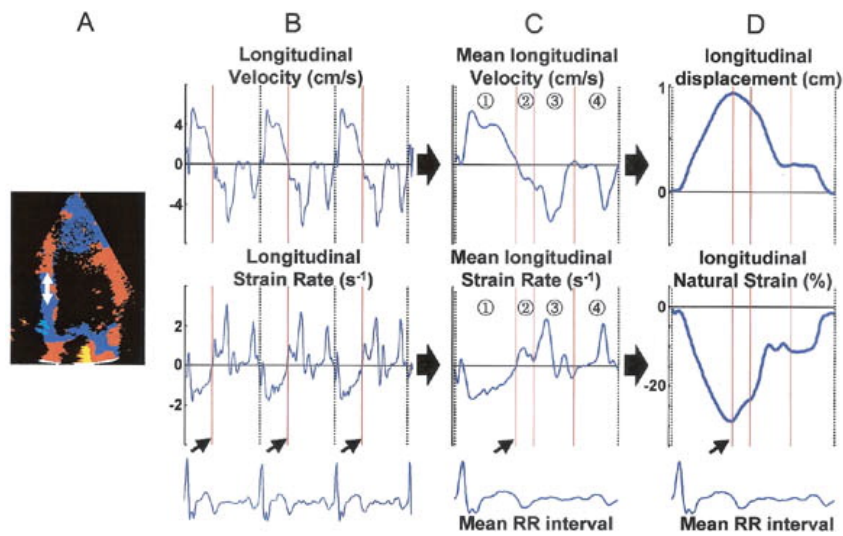
Strain Calculation Based on Tissue Doppler Data



$$SR = \frac{v_1 - v_0}{d}$$

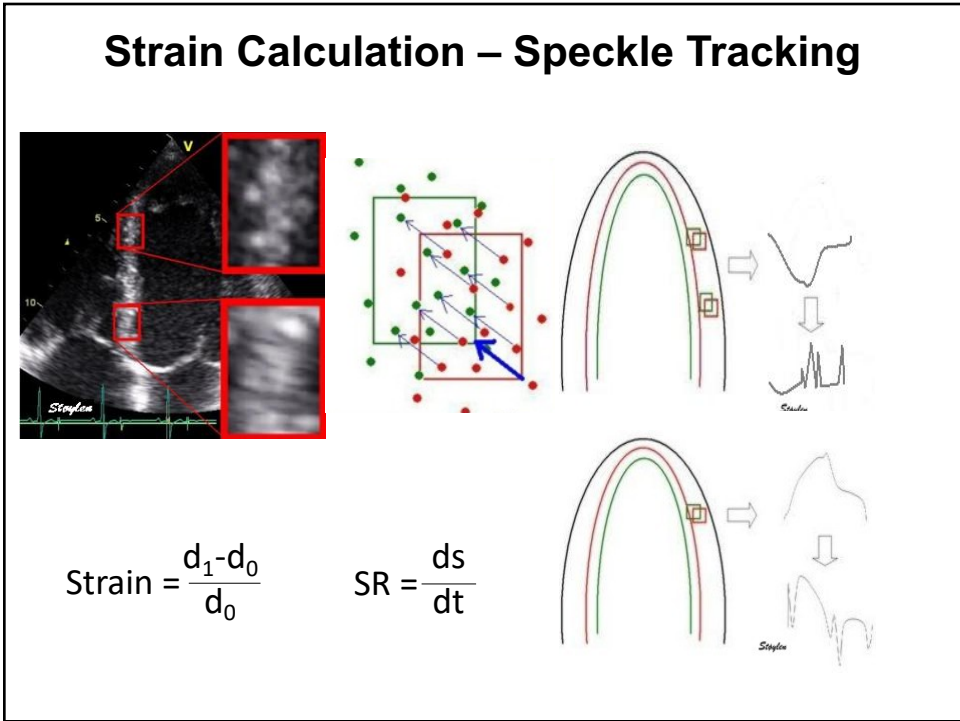
17

TDI-based Velocities and Strain Calculation

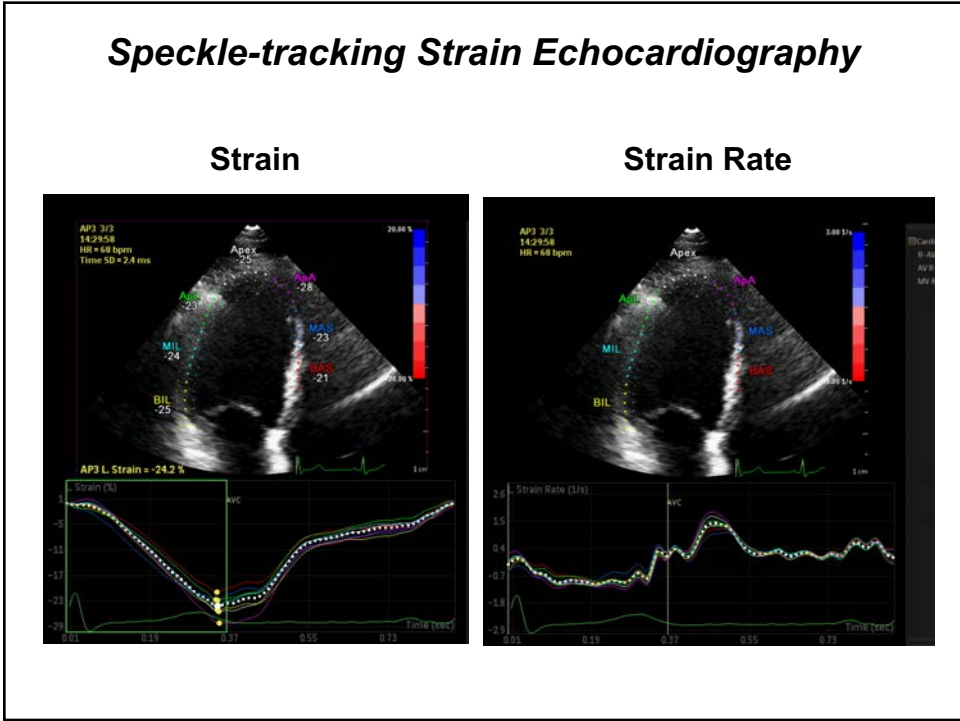


Jamal F, et al. J Am Soc Echocardiogr 2002;15:723

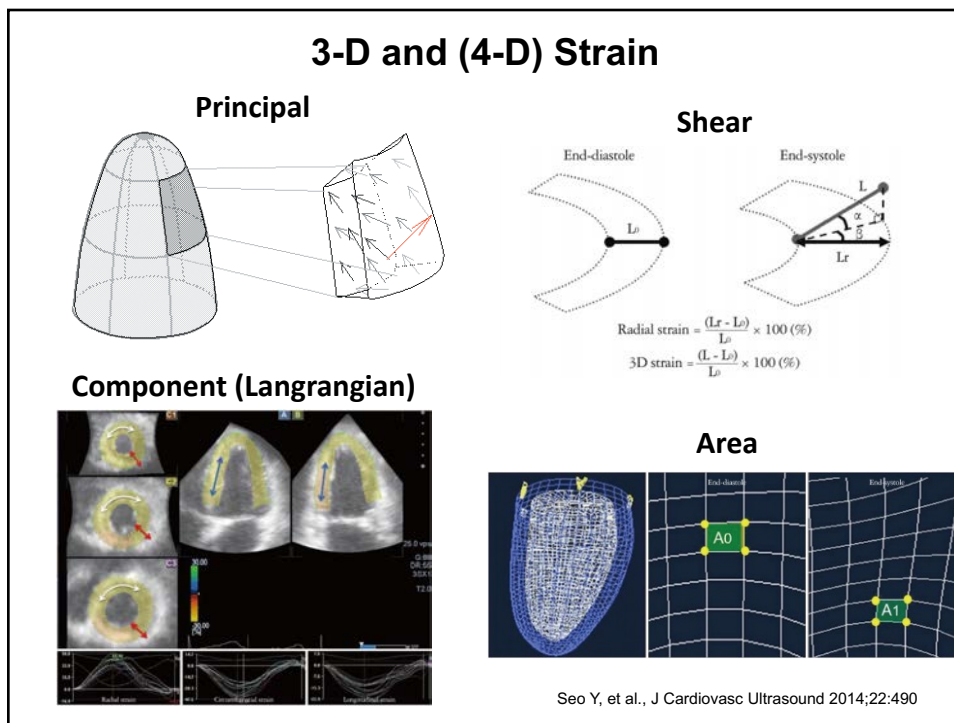
18



19



20



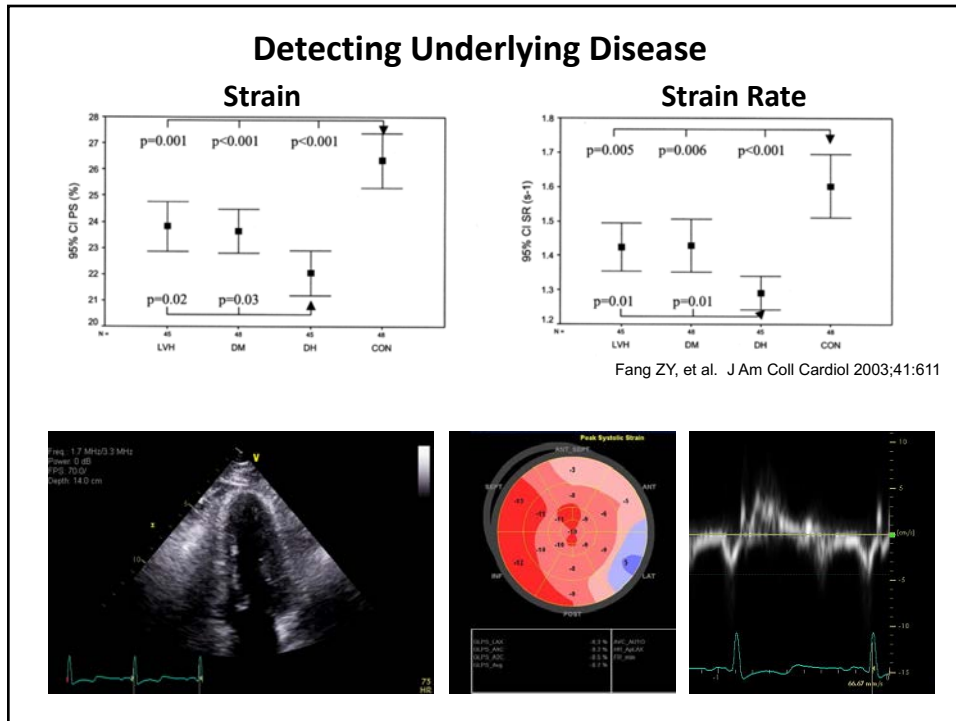
21

Velocity and Strain Echo Techniques

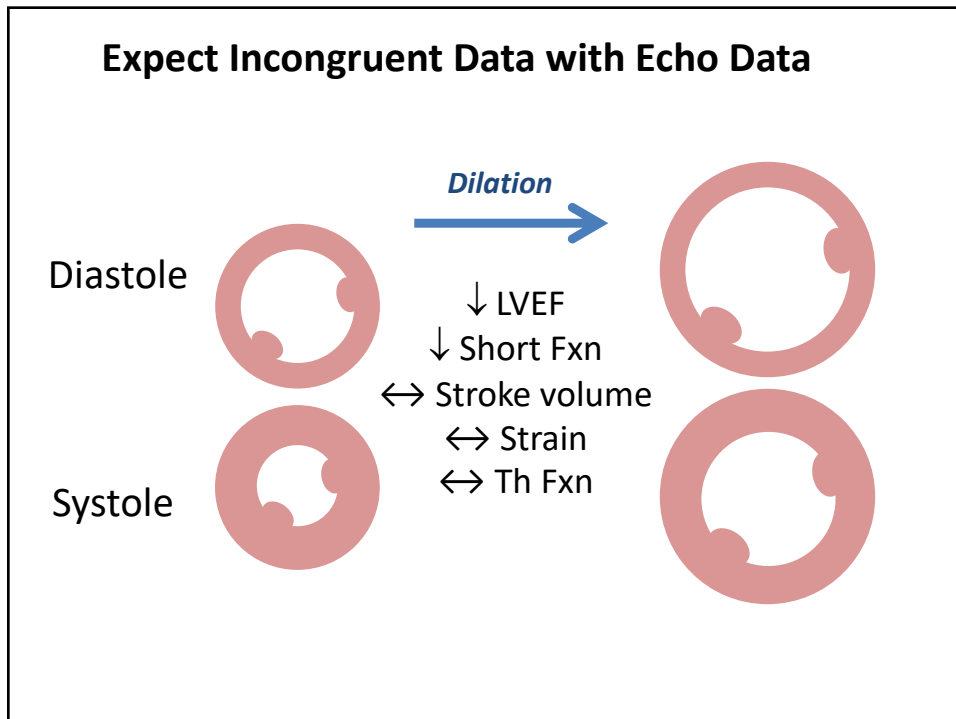
| Features | DTI | 2-D STE | 3-D STE |
|----------------------------------|-----|---------|---------|
| Feasibility | +++ | ++ | + |
| Temporal resolution | +++ | ++ | + |
| Angle independency | - | + | ++ |
| Affected by through-plane motion | +++ | + | +++ |
| Defined values (normal and dz) | +++ | +++ | + |
| Segmental uniformity | - | ++ | ++ |
| Vendor variability | ++ | + | + |

- poor, + reasonable, ++ good, +++ very good

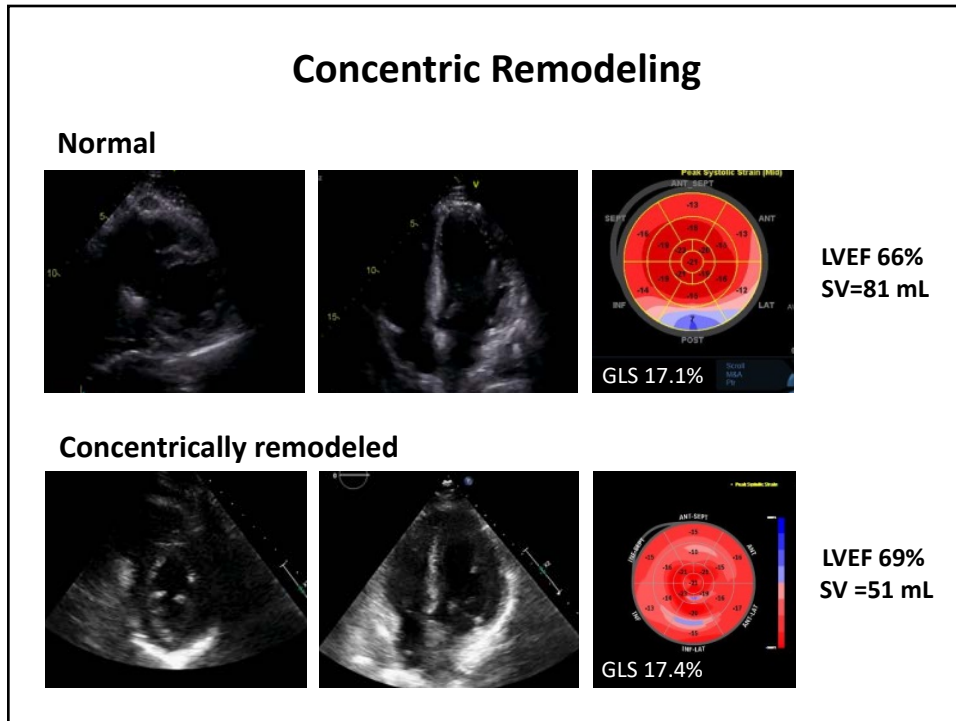
22



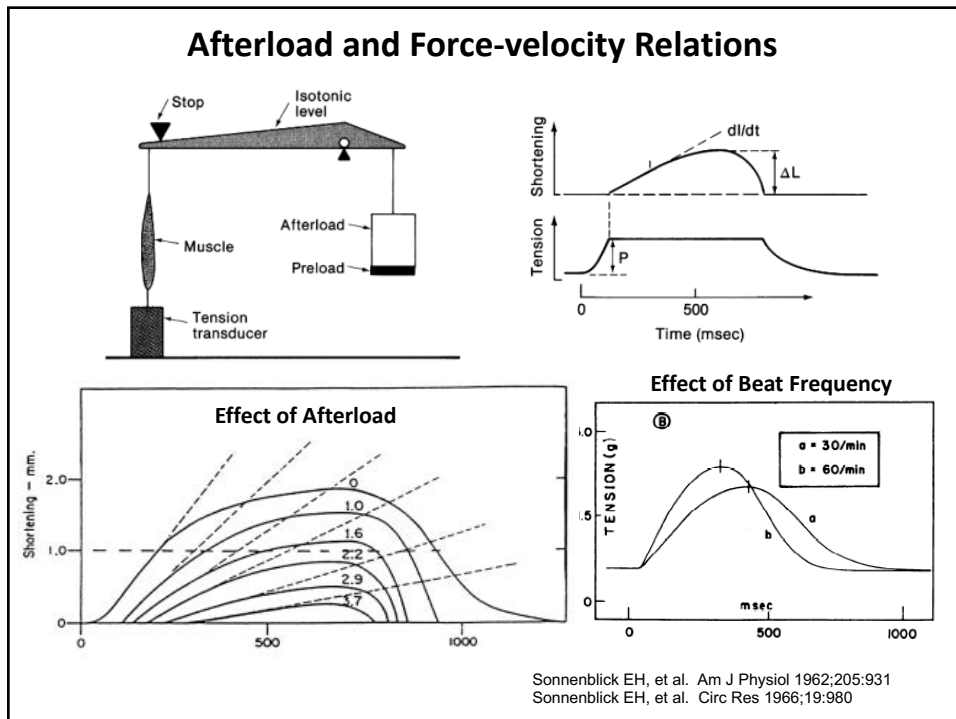
23

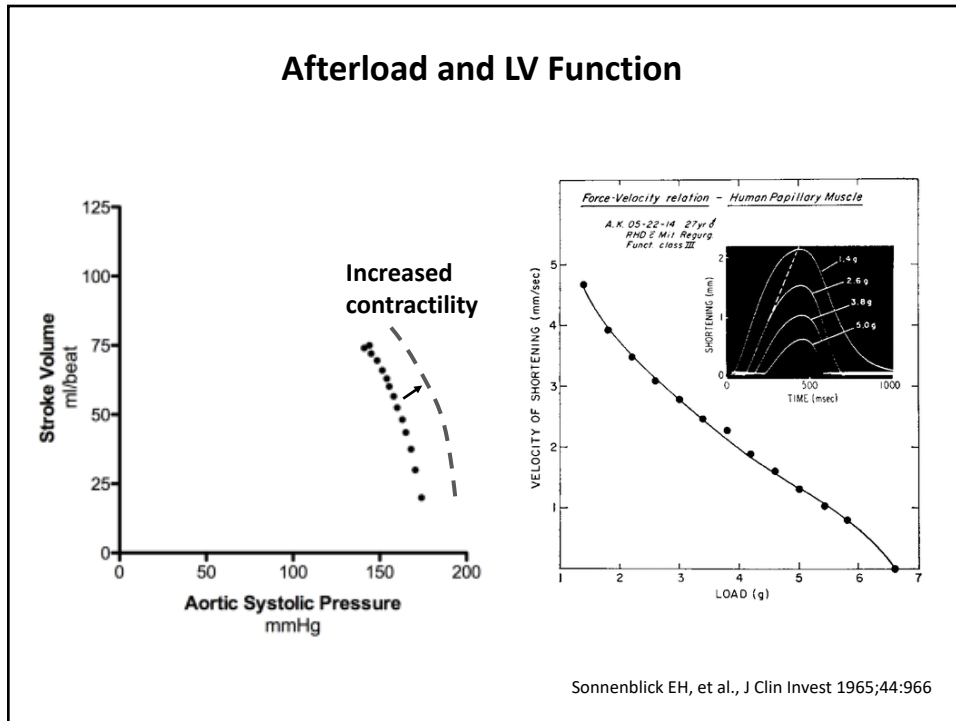


24

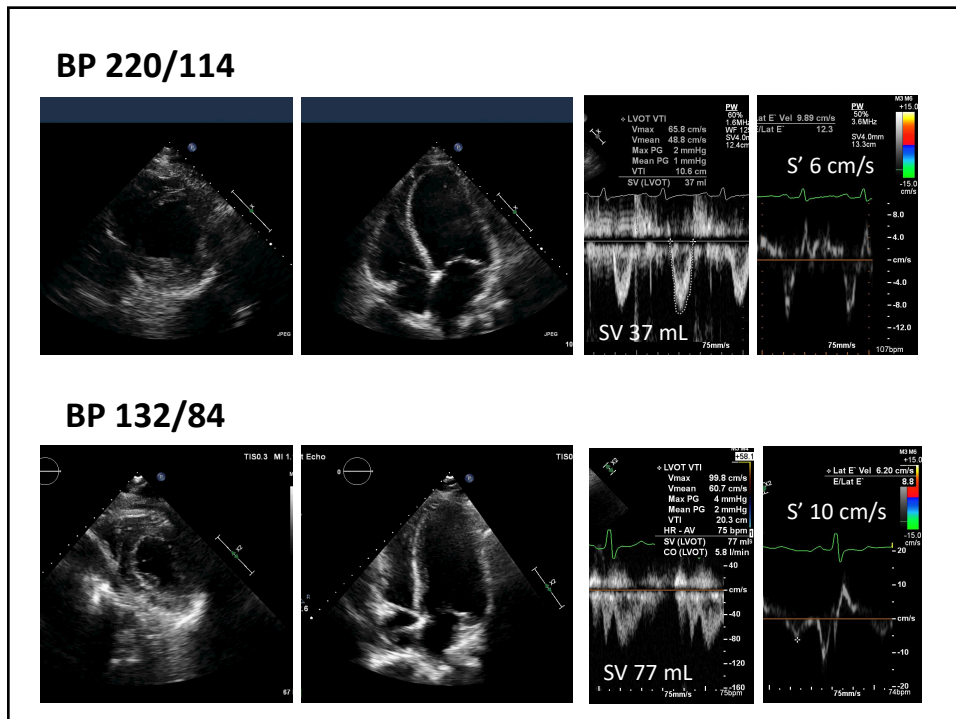


25

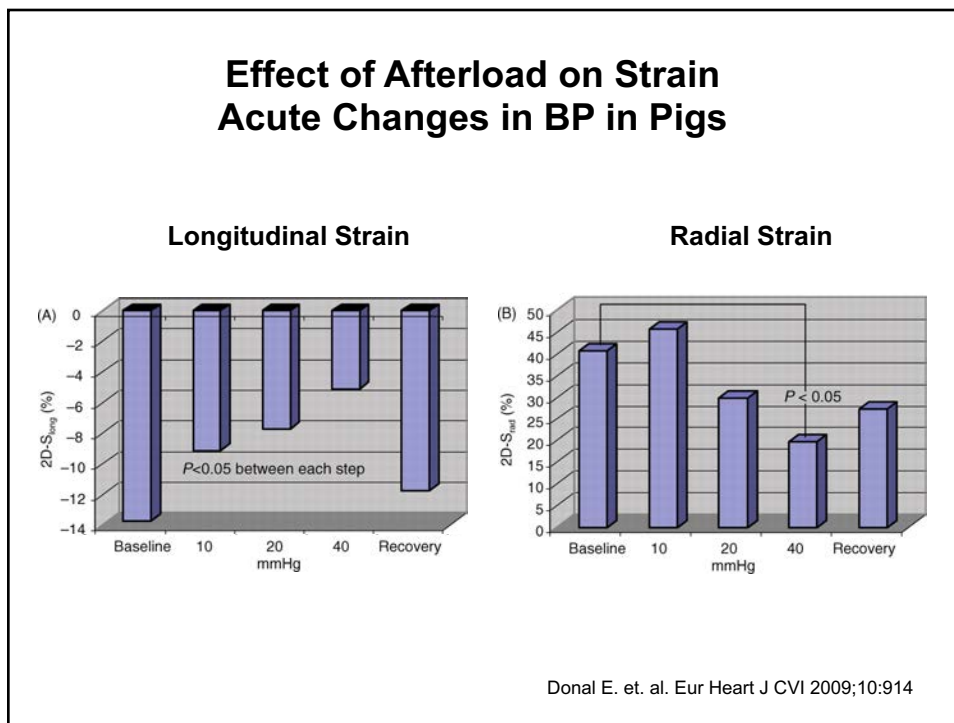




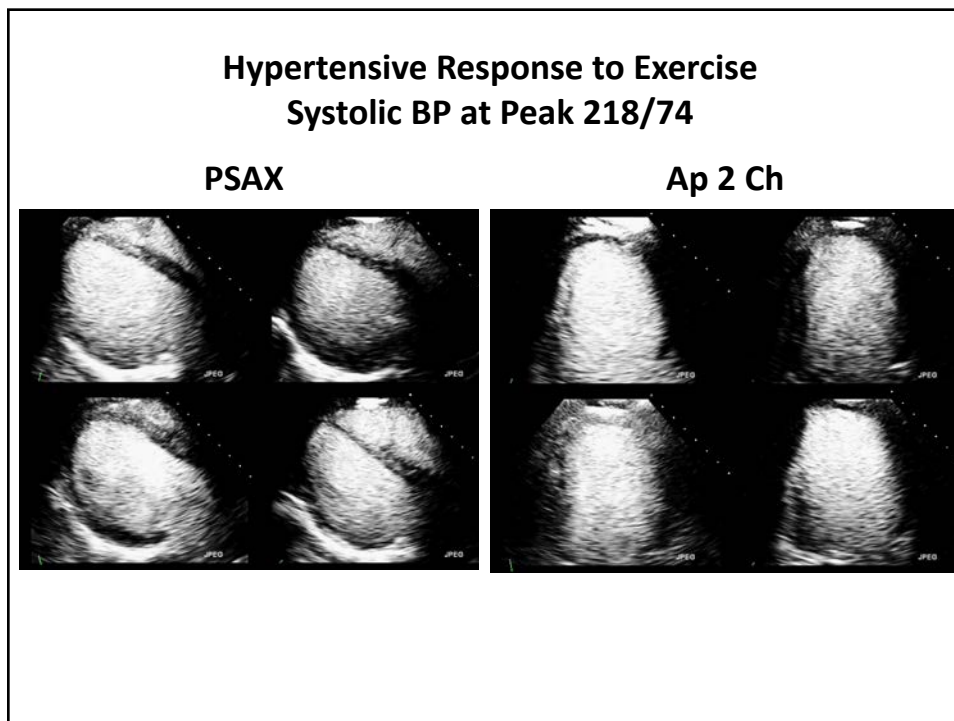
27



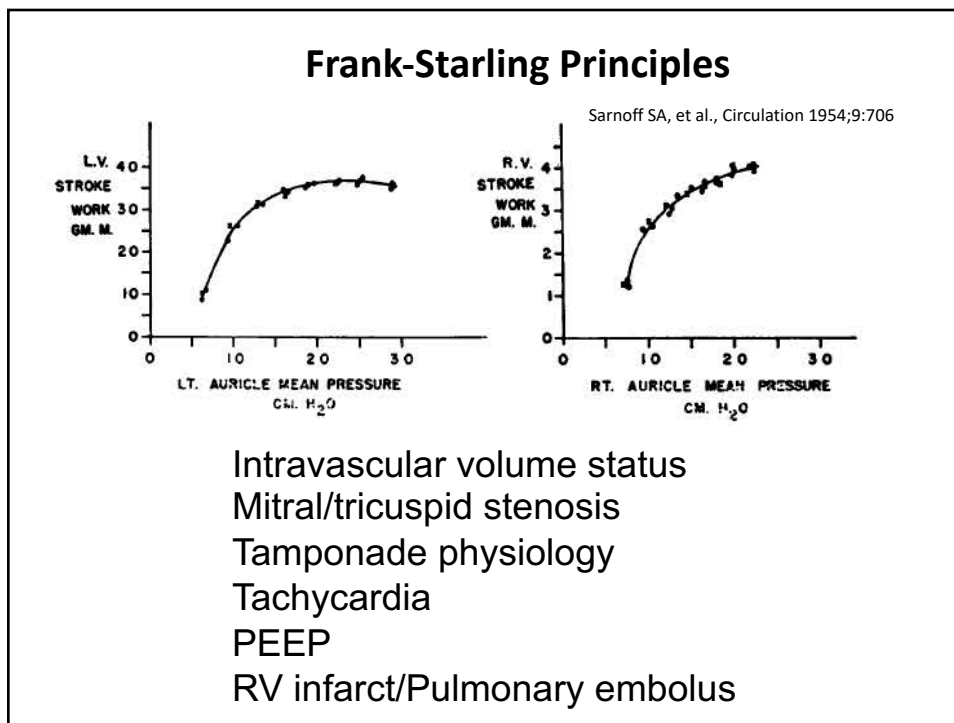
28



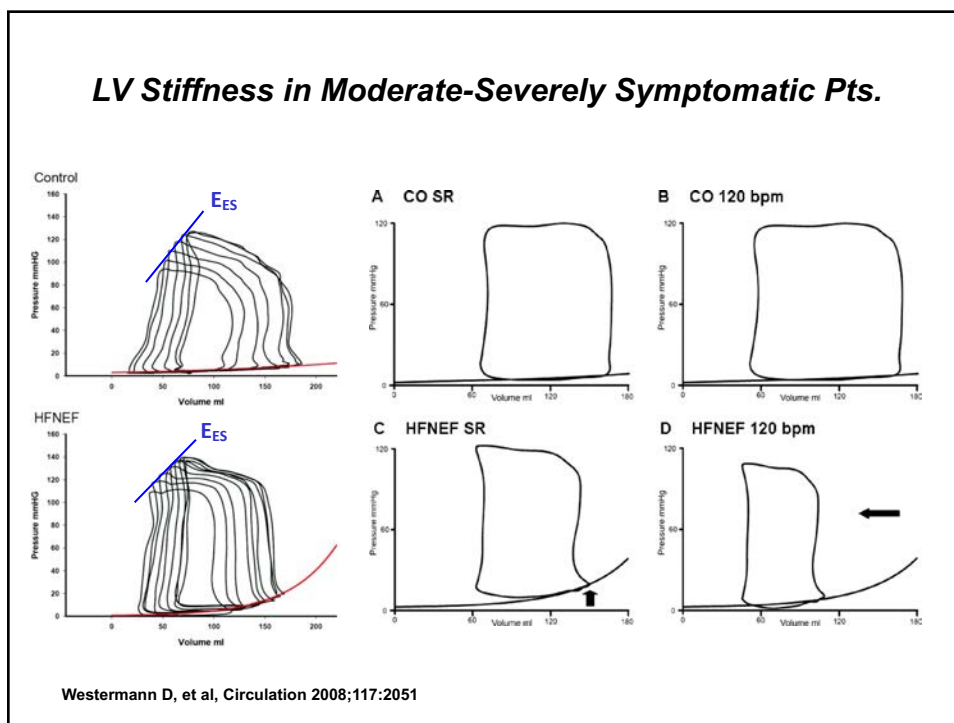
29



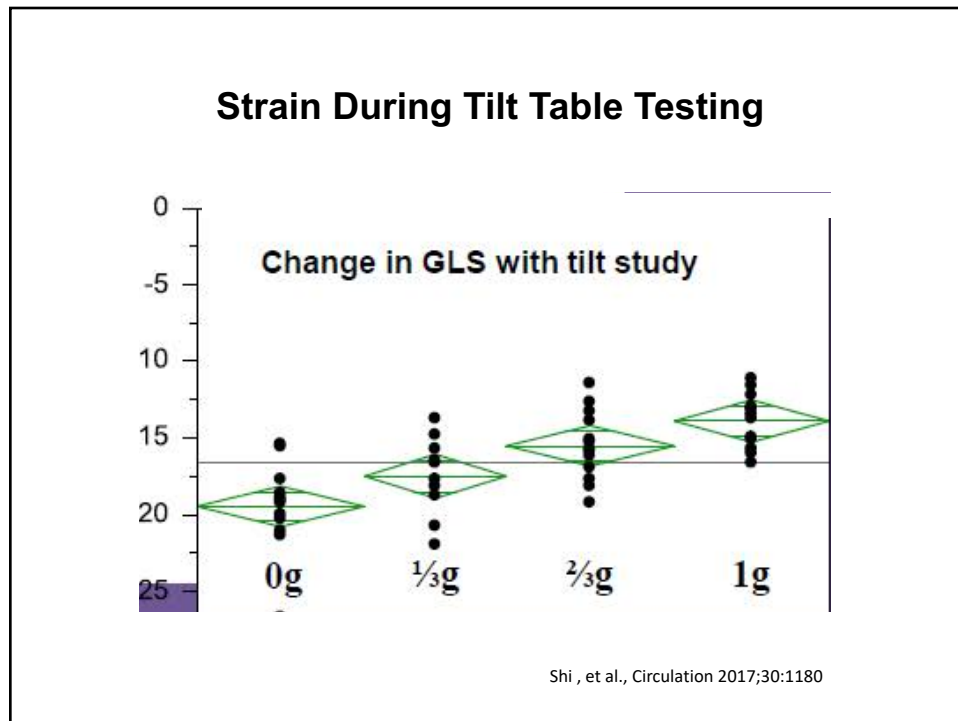
30



31



32

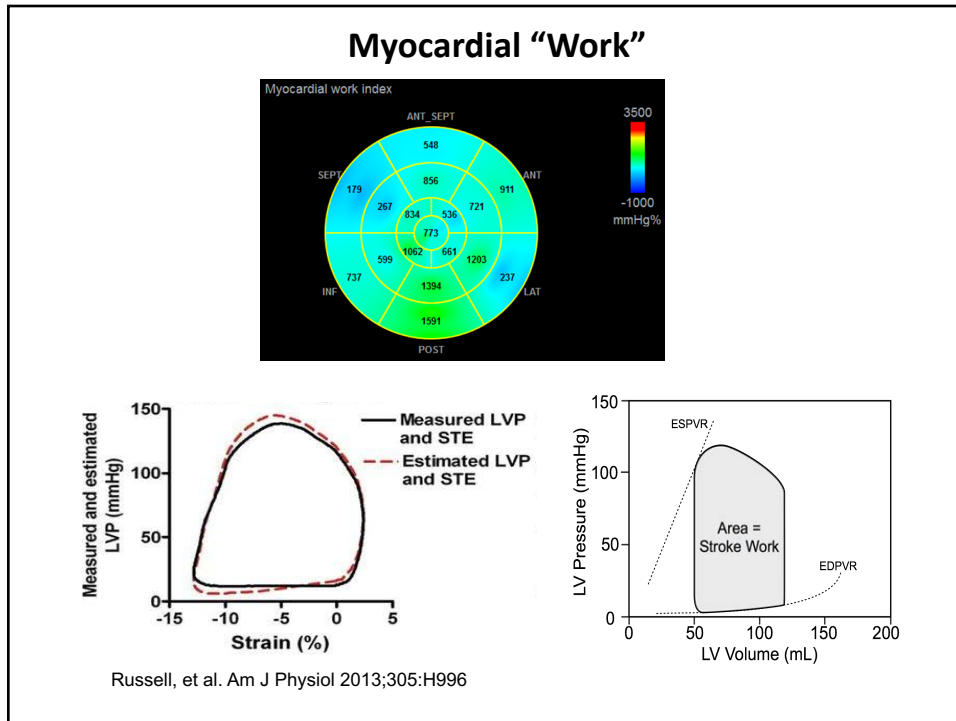


33

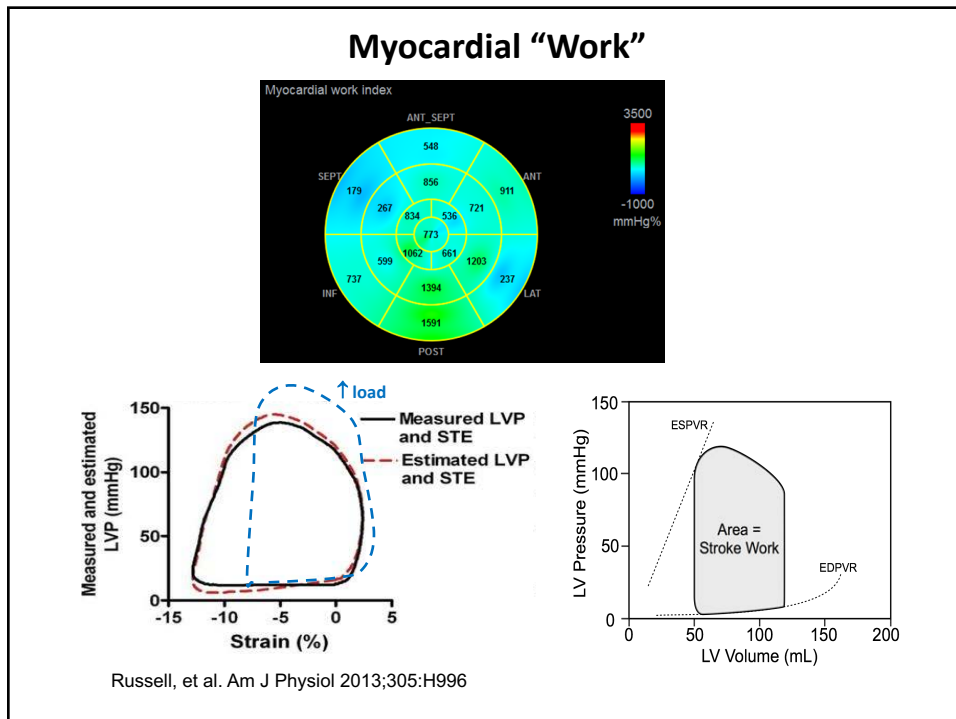
Incremental Value of Global Strain Assessment

1. Hypertensive CM
2. Amyloid
3. Infiltrative
4. Transplant rejection
5. HCM
6. Muscular dystrophy
7. Valvular CM
8. Cardiotoxic effects of drugs
9. Etc.

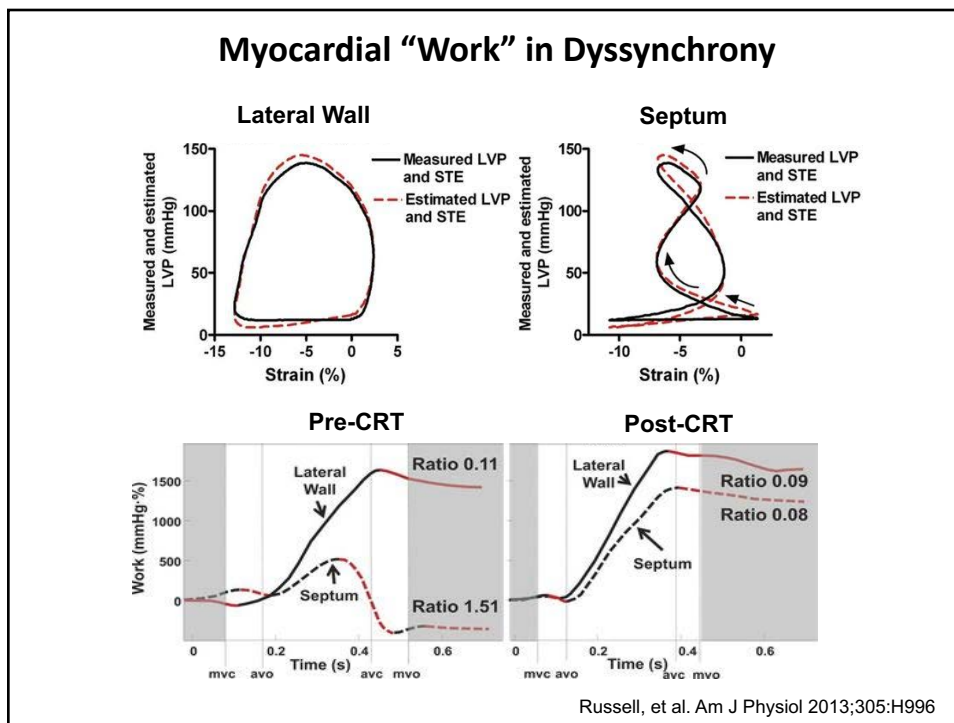
34



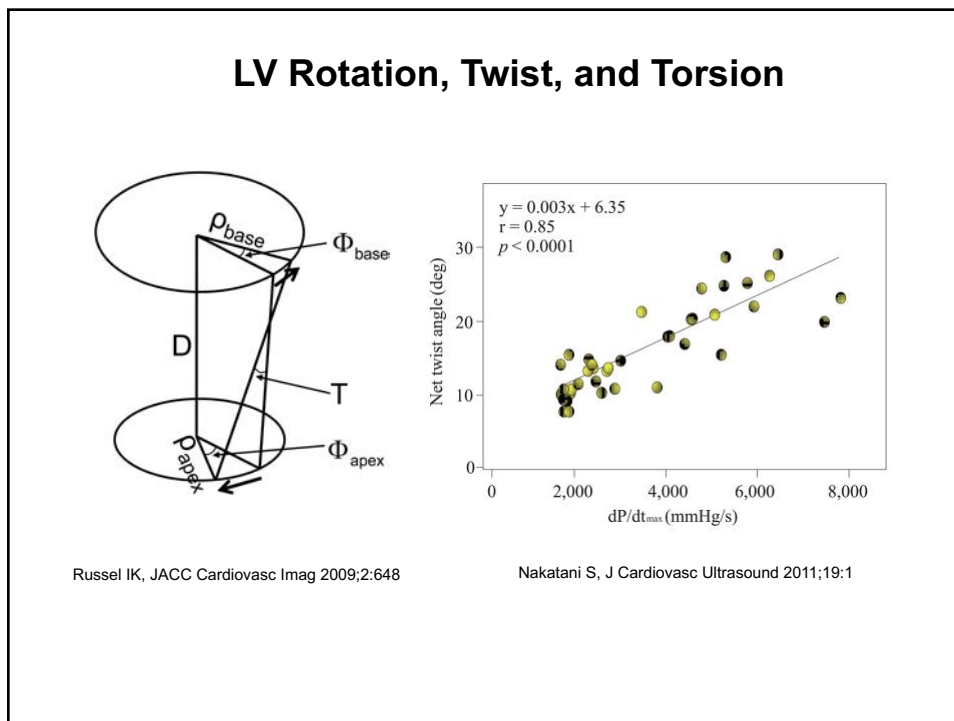
35



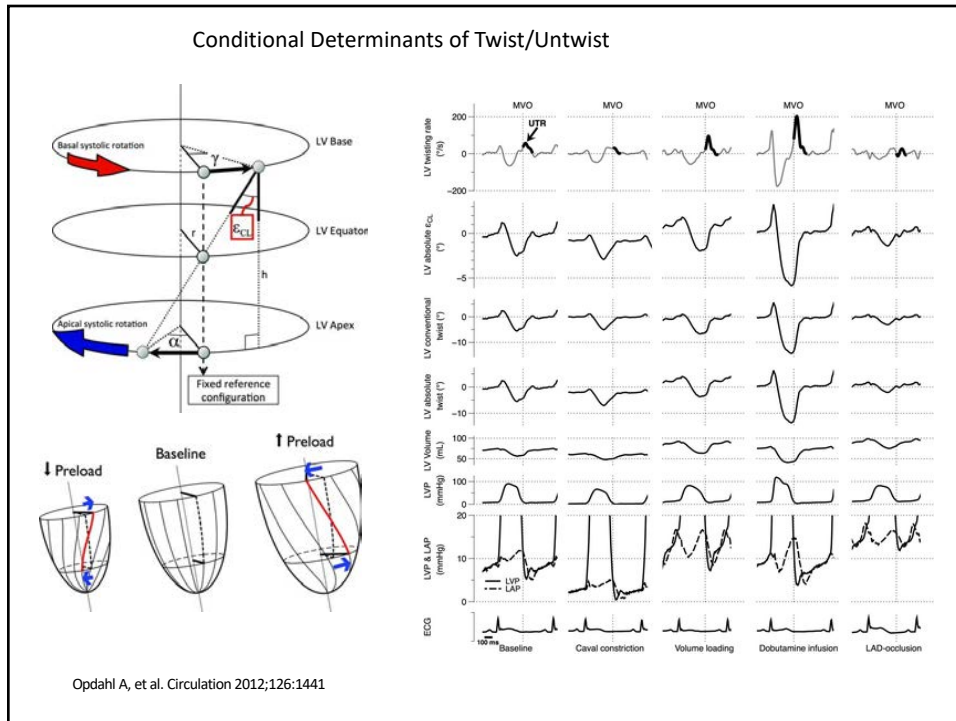
36



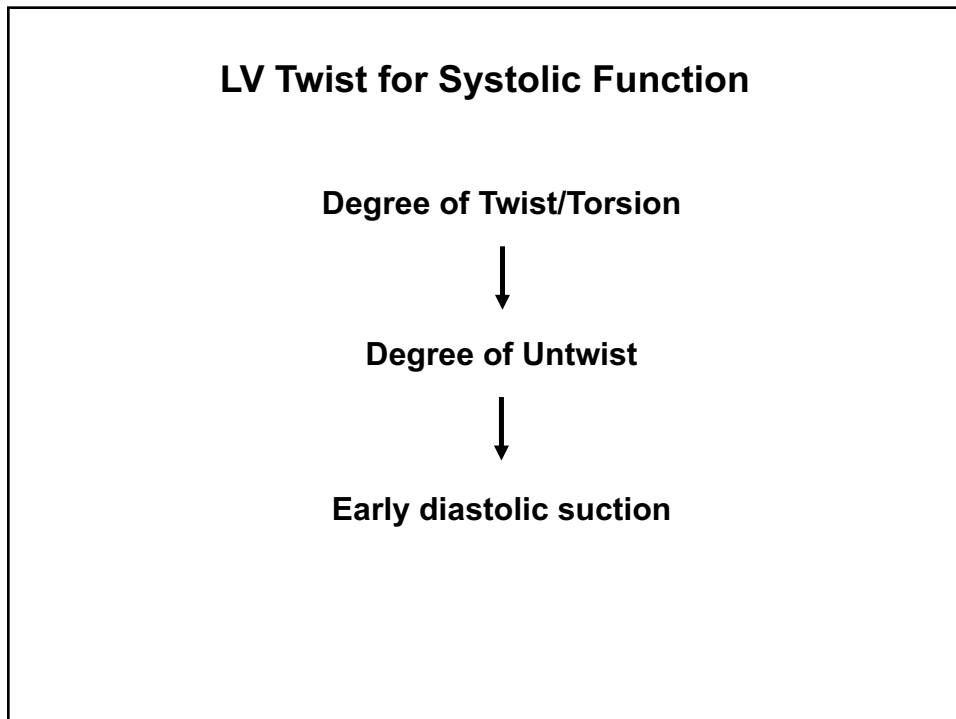
37



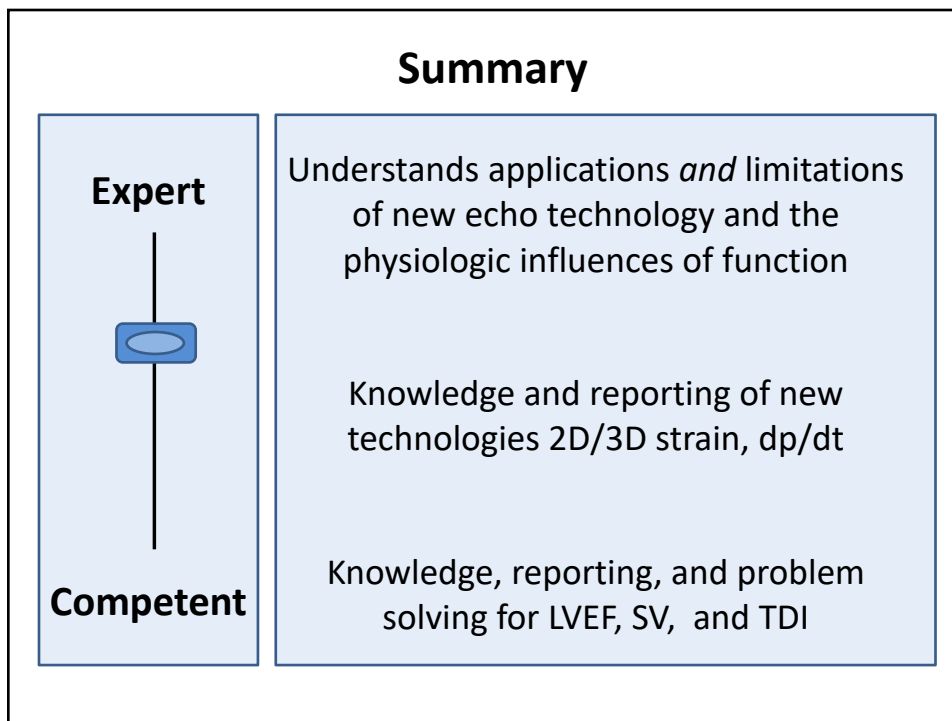
38



39



40



41