When Does 3D Echo Make A Difference?

Wendy Tsang, MD, SM
Assistant Professor, University of Toronto
Toronto General Hospital, University Health Network

GUIDELINES AND STANDARDS

EAE/ASE Recommendations for Image Acquisition and Display Using Three-Dimensional Echocardiography

Roberto M. Lang, MD, FASE,*‡ Luigi P. Badano, MD, FESC,†‡ Wendy Tsang, MD,* David H. Adams, MD,* Eustachio Agricola, MD,† Thomas Buck, MD, FESC,† Francesco F. Faletra, MD,† Andreas Franke, MD, FESC,† Judy Hung, MD, FASE,* Leopoldo Pérez de Isla, MD, PhD, FESC,† Otto Kamp, MD, PhD, FESC,† Jaroslaw D. Kasprzak, MD, FESC,† Patrizio Lancellotti, MD, PhD, FESC,† Thomas H. Marwick, MBBS, PhD,* Marti L. McCulloch, RDCS, FASE,* Mark J. Monaghan, PhD, FESC,† Petros Nihoyannopoulos, MD, FESC,† Natesa G. Pandian, MD,* Patricia A. Pellikka, MD, FASE,* Mauro Pepi, MD, FESC,† David A. Roberson, MD, FASE,* Stanton K. Shernan, MD, FASE,* Girish S. Shirali, MBBS, FASE,* Lissa Sugeng, MD,* Folkert J. Ten Cate, MD,† Mani A. Vannan, MBBS, FASE,* Jose Luis Zamorano, MD, FESC, FASE,† and William A. Zoghbi, MD, FASE*, *Chicago and Oak Lawn, Illinois; Padua and Milan, Italy; New York, New York; Essen and Hannover, Germany; Lugano, Switzerland; Boston, Massachusetts; Madrid, Spain; Amsterdam and Rotterdam, The Netherlands; Lodz, Poland; Liege, Belgium; Cleveland, Ohio; Houston, Texas; London, United Kingdom; Rochester, Minnesota; Charleston, South Carolina; New Haven, Connecticut; Morrisville, North Carolina*

(J Am Soc Echocardiogr 2012;25:3-46.)

GUIDELINES AND STANDARDS

EAE/ASE Recommendations for Image Acquisition and Display Using Three-Dimensional Echocardiography

Practical Applications of 3D Echocardiography

Recommended	Promising Clinical Trials	Areas of active Research

GUIDELINES AND STANDARDS

EAE/ASE Recommendations for Image Acquisition and Display Using Three-Dimensional Echocardiography

Recommended
LV Volumes
MV anatomy
MV Stenosis
Guidance of Transcatheter Procedures

+ Tricuspid Valve Anatomy

Techniques for Integration

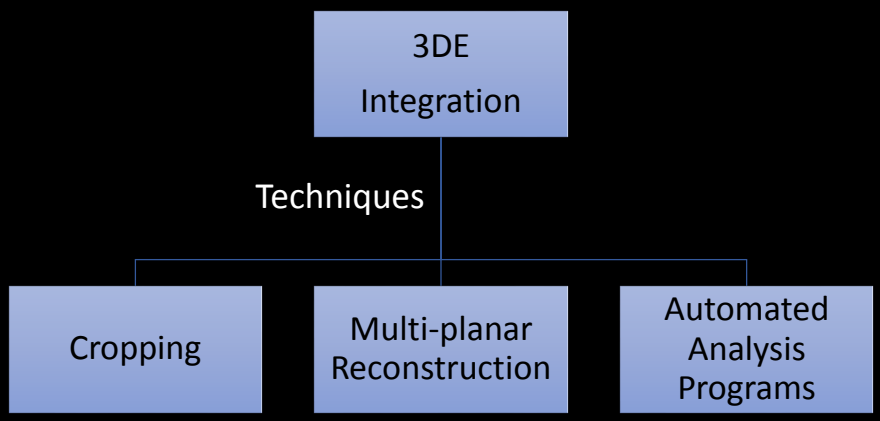

Which is a true 4-chamber view?

A B C

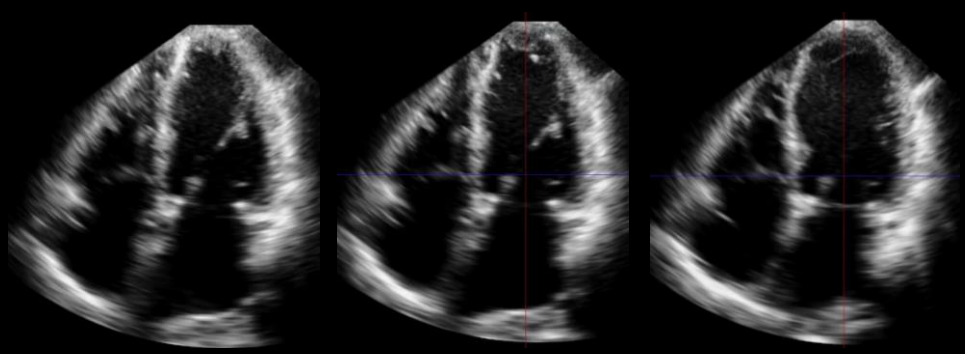

LV Function Assessment

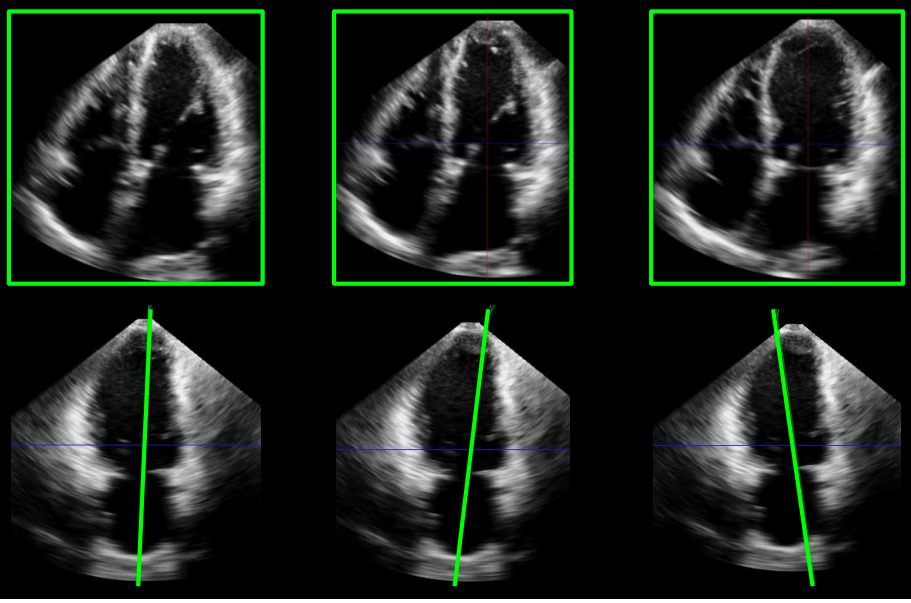

Tomographic Slices

LV Function Assessment

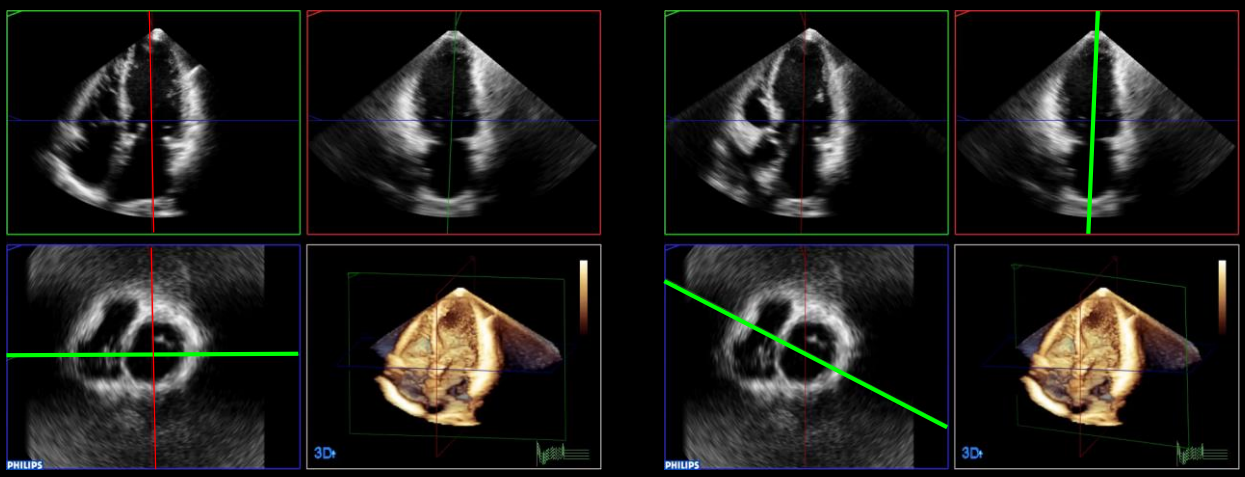

Tomographic Slices

LV Function Assessment

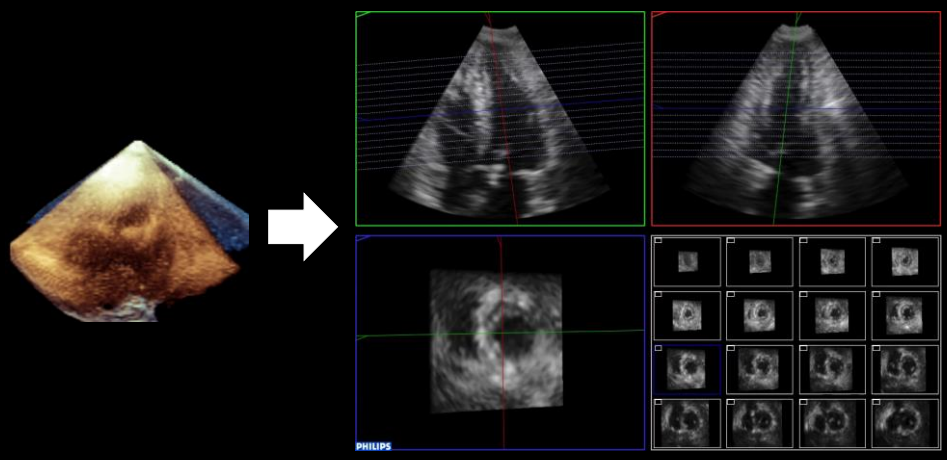

Tomographic Slices

LV Function Assessment

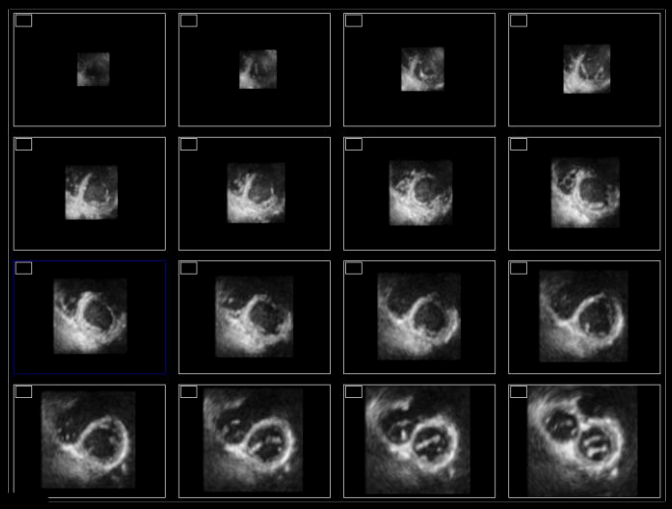

Improve Biplane LVEF Using 3D

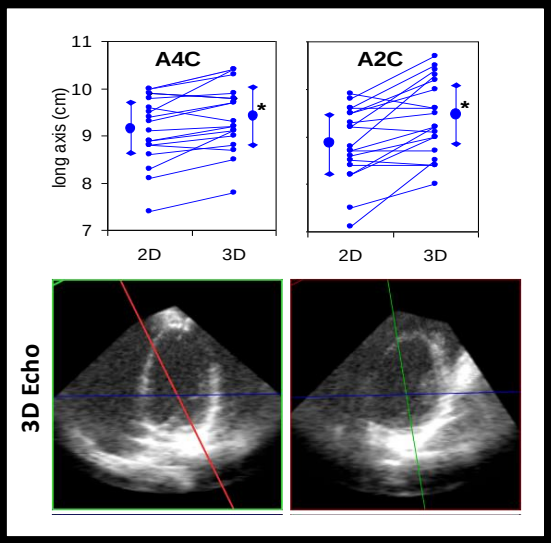

Mor-Avi V, et al. Circulation 2004. 110: 1814-1818.

True 3D LV Volumes

Increased Accuracy

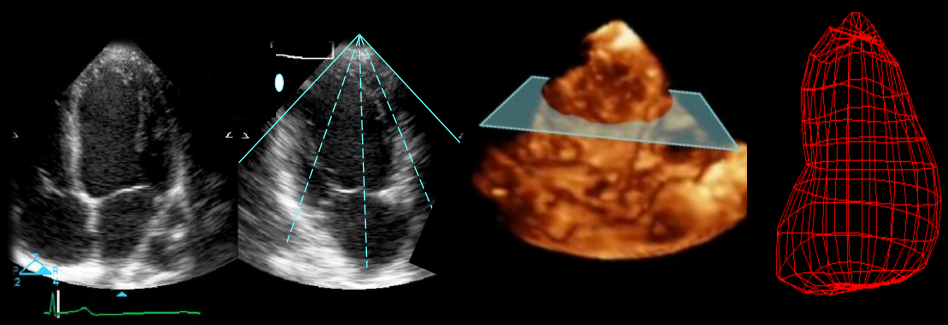

3DE Changes 2DE Categorization

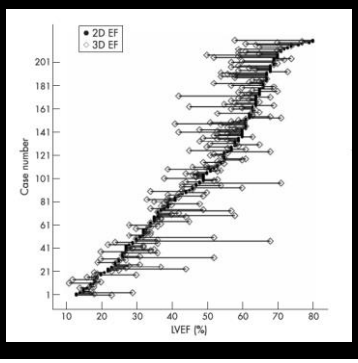

Table 1 Re-allocation to above or below ejection fraction (EF) threshold according to 2D EF

2D EF band	No of 2D patients	Re-allocation according to a threshold EF 35% (%)	Re-allocation according to a threshold EF 40% (%)
⩽25%	32	2 (6.3)	1 (3.1)
26–35%	36	14 (38.9)	5 (13.9)
36–40%	13	1 (7.7)	7 (53.9)
41–45%	10	2 (20.0)	5 (50.0)
>45%	129	0 (0)	2 (1.6)

Heart 2008;94:440–445.

ORIGINAL RESEARCH

Feasibility, Accuracy, and Reproducibility of Real-Time Full-Volume 3D Transthoracic Echocardiography in Systolic Atrial Fibrillation

A Fully Automated Method for Quantifying Left Ventricular Volumes in Sinus Rhythm and Atrial Fibrillation

Paaladines, Anna Calle, Orlando Si, Columbus,

OBJECTIVES To assess the feasibility, accuracy, and reproducibility of real-time full-volume 3-dimensional transthoracic echocardiography (3D RT-VTTE) to measure left ventricular (LV) volumes and ejection fraction (EF) using a fully automated endocardial contouring algorithm and to identify and automatically correct the contours to obtain accurate LV volumes in sinus rhythm and atrial fibrillation (AF).

BACKGROUND 3D transthoracic echocardiography is not used routinely to quantify LV volumes

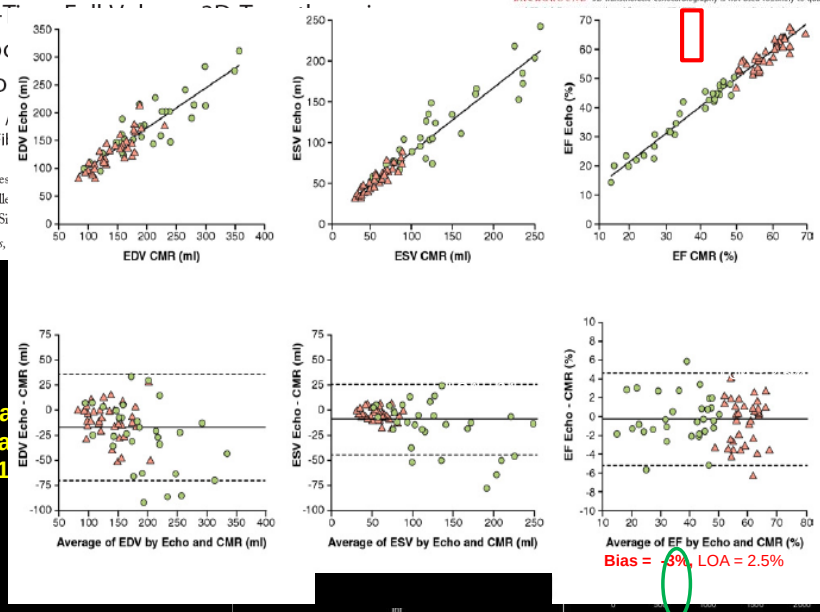

Tha
et a
201

Fully Automated Cardiac Chamber Quantification

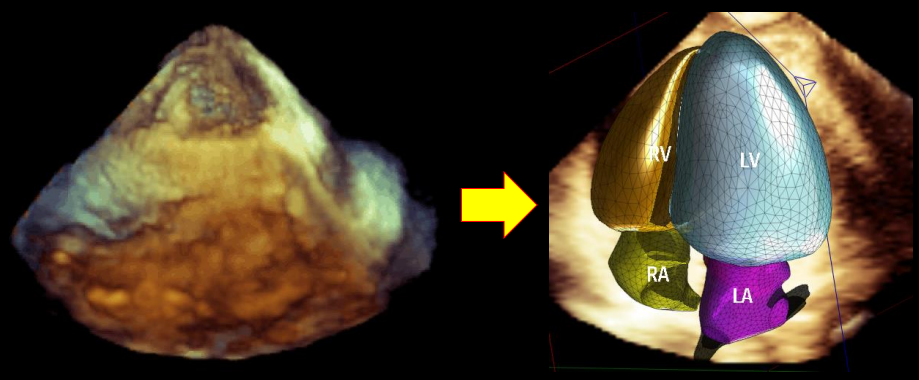

Multi-planar Reconstruction

RV Size Assessment

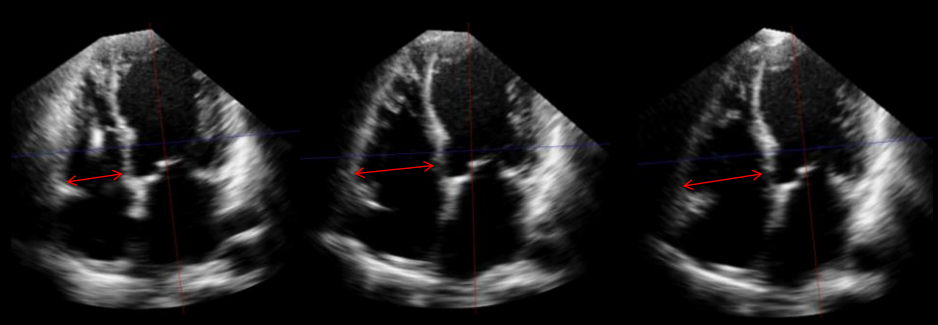

MPR RV Size Assessment

Increases Consistency

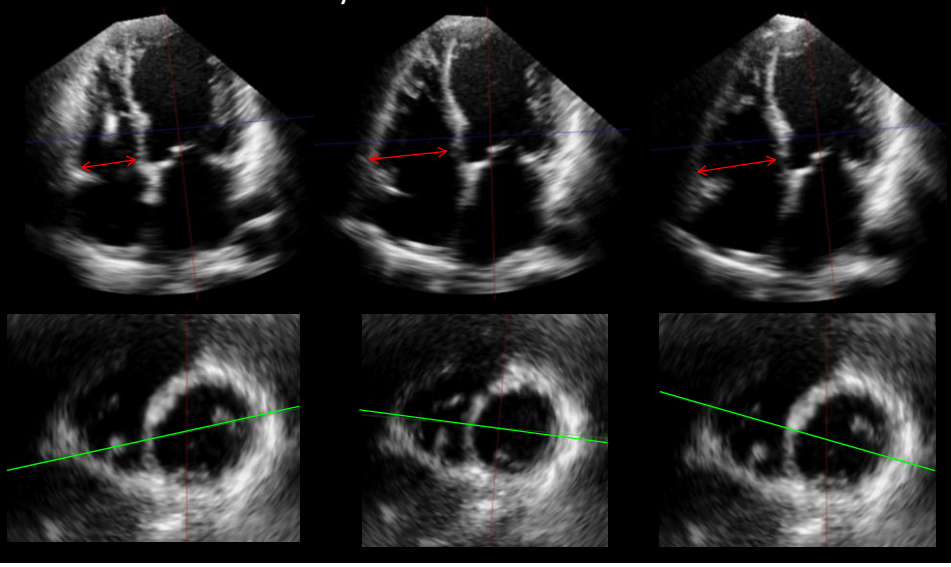

Surgeon's View of the MV

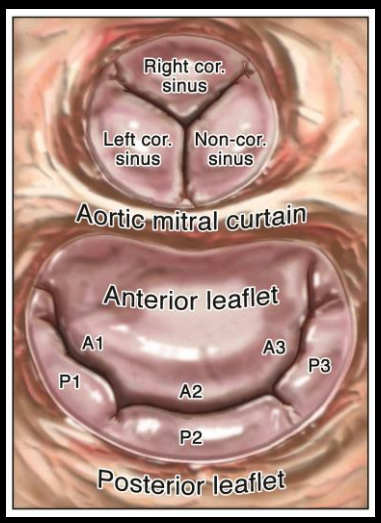

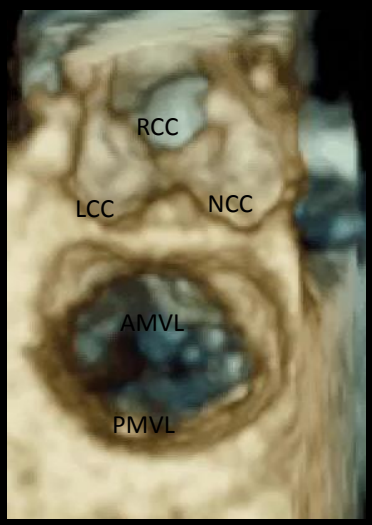

Lang RM, Tsang W, Weinert L, Mor-Avi V, Chandra S. JACC 2011 November 1;5 8(19):1933-1944.

Lesion Identification/Repair Complexity

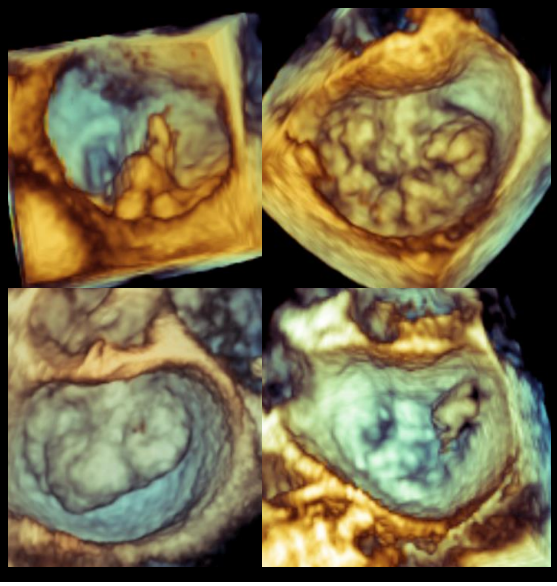

MPR Localization

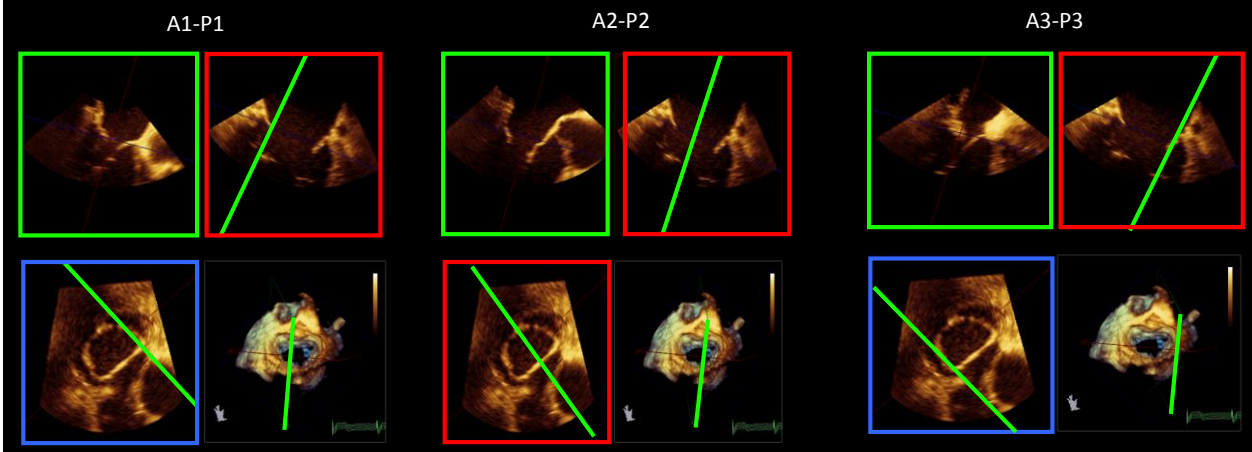

MV Quantification

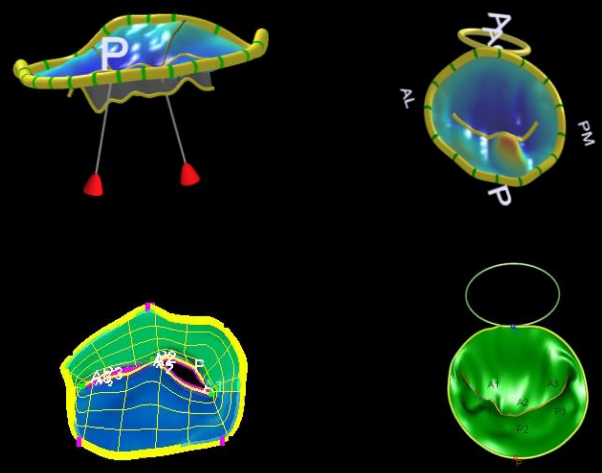

What MVA would you report?

A

2D 1.66 cm^2

B

3D 1.44 cm^2

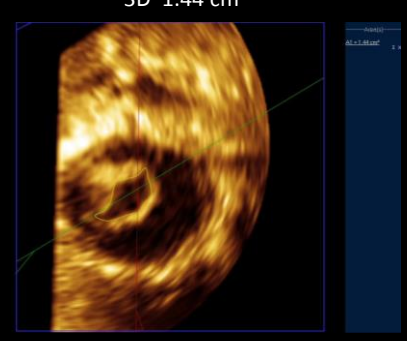

Rheumatic Mitral Stenosis

LA Perspective LV Perspective

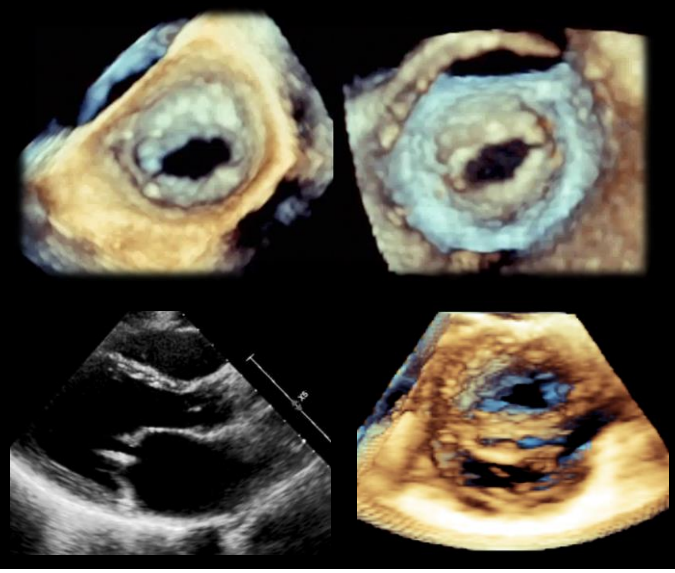

MVA Planimetry by MPR

Transthoracic

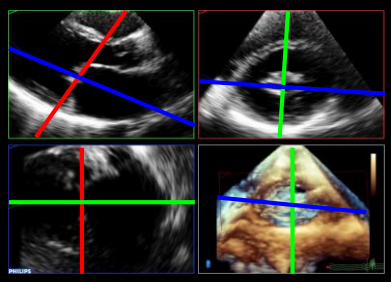

- 2D echo planimetry overestimates MVA
- 3D echo improves identification of the narrowest part of the MV orifice due to better alignment of the image plane at the mitral tips

Transesophageal

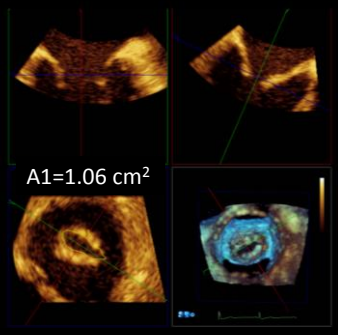

Wunderlich, NC. JACC: Cardiovasc Imag. 2013;6(11):1191-205.

Mitral Valve Quantification

Mitral Valvuloplasty Scoring

Wilkins ≤8

Item	Rating	Value
Leaflet Mobility	Highly mobile	1
	Reduced mobility	2
	Basal leaflet motion only	3
	Minimal motion	4
Valve Thickening	Near normal (4-5 mm)	1
	Thickened tips	2
	Entire leaflet thickened (5-8 mm)	3
	Marked leaflet thickening (>8-10 mm)	4
Calcification	Single area of brightness	1
	Scattered areas at leaflet margins	2
	Brightness extends to mid leaflets	3
	Extensive leaflet brightness	4
Subvalvular Thickening	Minimal chordal thickening	1
	Chordal thickening up to 1/3	2
	Distal third of chordae thickening	3
	Extensive thickening to pap muscle	4

- Semi-quantitative
- Subject to observer variability
- Less reliable in classifying patients with scores within the mid-range
- Fibrosis vs calcification
- Uneven distribution of pathology
- Underestimates subvalve disease

http://www.csecho.ca/wp-content/themes/twentyeleven-csecho/cardiomath/?eqnHD=echo&eqnDisp=mvsmgh

Mitral Valvuloplasty Scoring

- Commissural morphology not assess
  - Post-procedural MR
  - important predictor of long-term outcome

Validation of a New Score for the Assessment of Mitral Stenosis Using Real-Time Three-Dimensional Echocardiography

Table 1 RT3DE score of MV

	Anterior leaflet			Posterior leaflet		
	A1	A2	A3	P1	P2	P3
Thickness (0-6) (0 = normal, 1 = thickened)*	0-1	0-1	0-1	0-1	0-1	0-1
Mobility (0-6) (0 = normal, 1 = limited)*	0-1	0-1	0-1	0-1	0-1	0-1
Calcification (0-10) (0 = no, 1-2 = calcified)†	0-2	0-1	0-2	0-2	0-1	0-2
	Subvalvular apparatus†					
	Proximal third		Middle third		Distal third	
Thickness (0-3) (0 = normal, 1 = thickened)	0-1		0-1		0-1	
Separation (0-6) (0 = normal, 1 = partial, 2 = no)	0, 1, 2		0, 1, 2		0, 1, 2	

*Normal = 0, mild = 1 to 2, moderate = 3 to 4, severe ≥ 5.
†Normal = 0, mild = 1 to 2, moderate = 3 to 5, severe ≥ 6.

3DE Score	
<8	Mild
8-13	Moderate
≥ 14	Severe

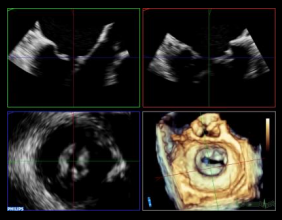

Anwar AM et al. J Am Soc Echocardiogr 2010;23:13-22.

Validation of a New Score for the Assessment of Mitral Stenosis Using Real-Time Three-Dimensional Echocardiography

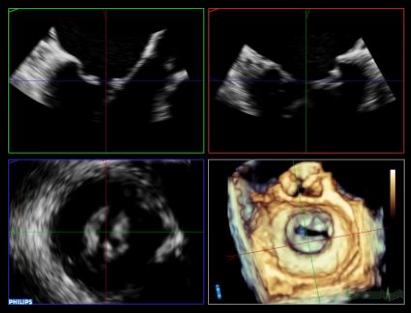

- Feasible
- Reproducible
- Good intra- and inter-observer variability
- Better detection of calcification and commissural splitting

Anwar AM et al. J Am Soc Echocardiogr 2010;23:13-22.

Subvalvular Assessment

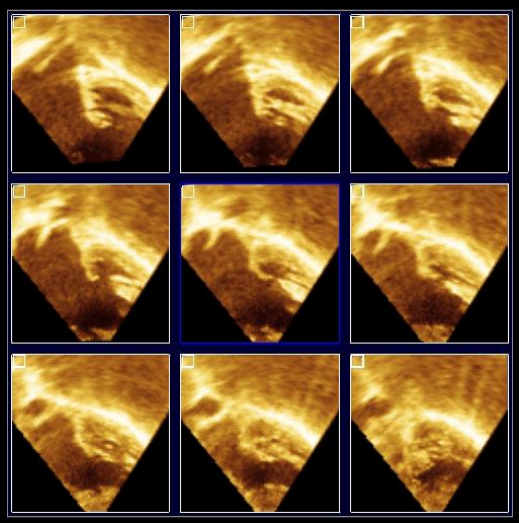

Perctaneous MV Balloon Valvuloplasty

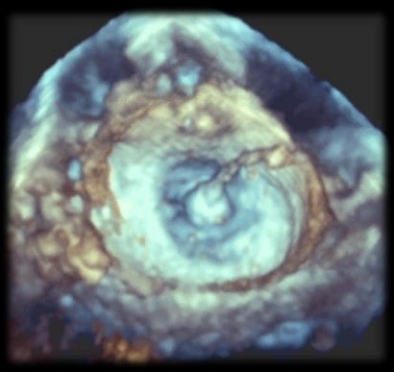

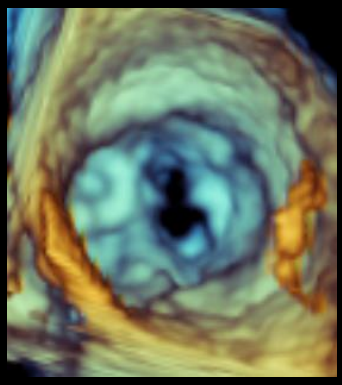

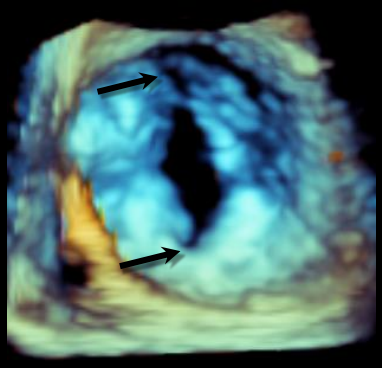

En-face Left Ventricular View

Bileaflet Mechanical Valve

LA LV

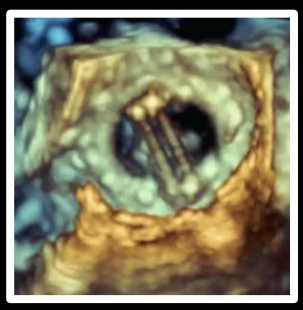

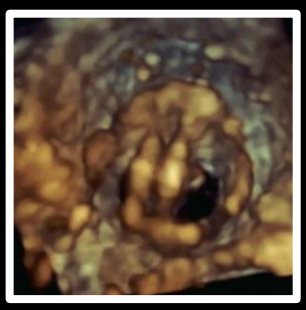

Thrombosed Mechanical Prosthesis

Location of Paravalvular Leaks

- Commonly located posteriorly because:
  1. Distal location in surgical field
  2. Protecting the circumflex artery
  3. Increase prevalence of calcium and fibrosis posteriorly
  4. Mitral fibrosa in anterior annulus tethers valve

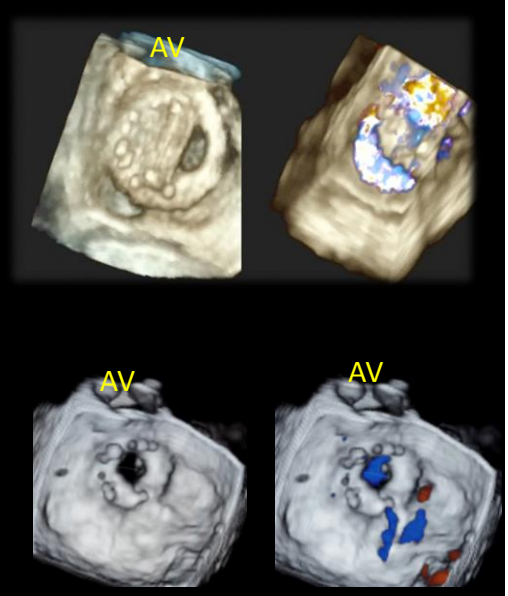

Assessment of Paravalvular Leaks

- Size of leak

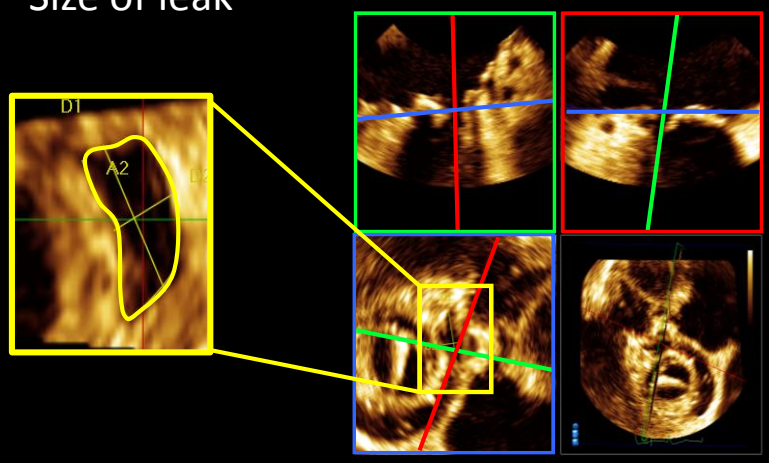

Percutaneous Repair of MV Dehiscence

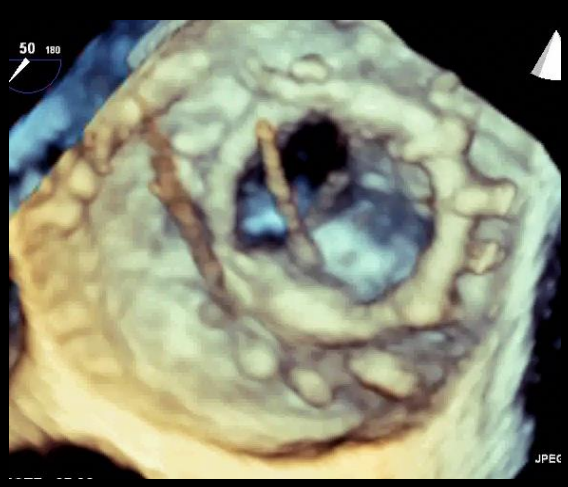

Courtesy MA Garcia Fernandez

Atrial Septal Defects

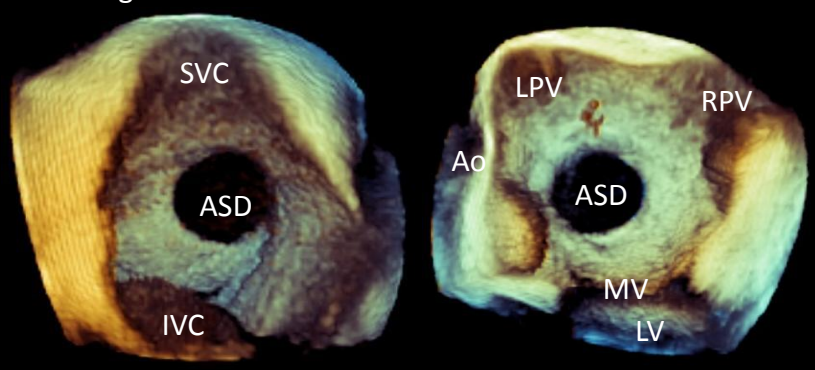

Courtesy: D. Roberson

ASD Size <38mm

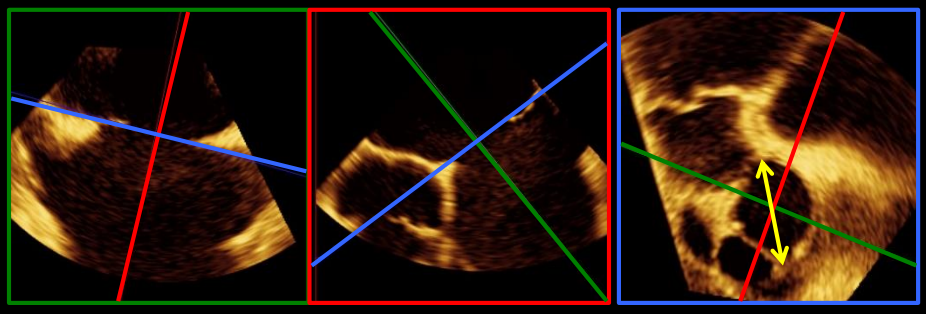

- Waist diameter determines device size (range 4 – 38 mm)

Use of Biplane Imaging: Incorrect Device Placement

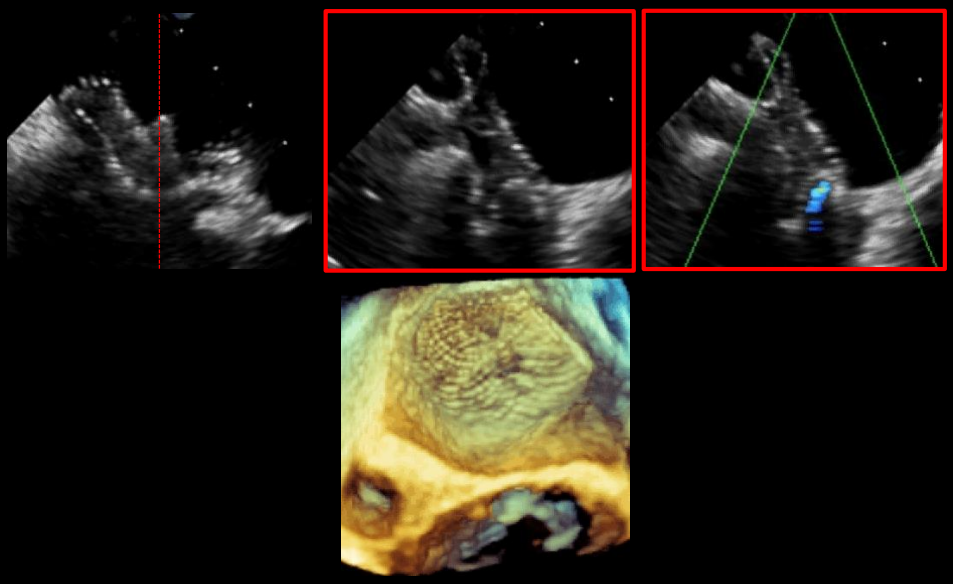

Biplane Imaging: Correct Device Placement

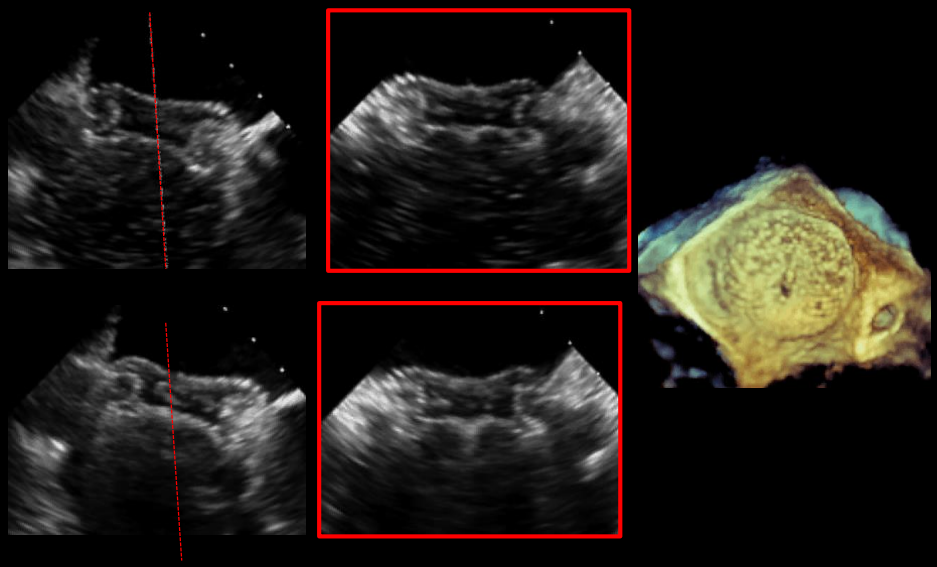

What is the mechanism of the TR?

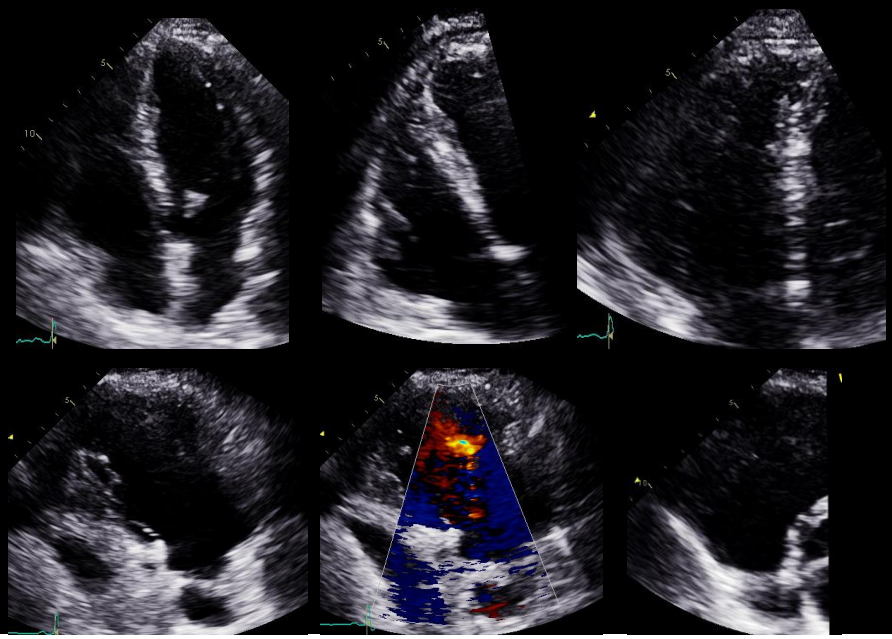

Case 2

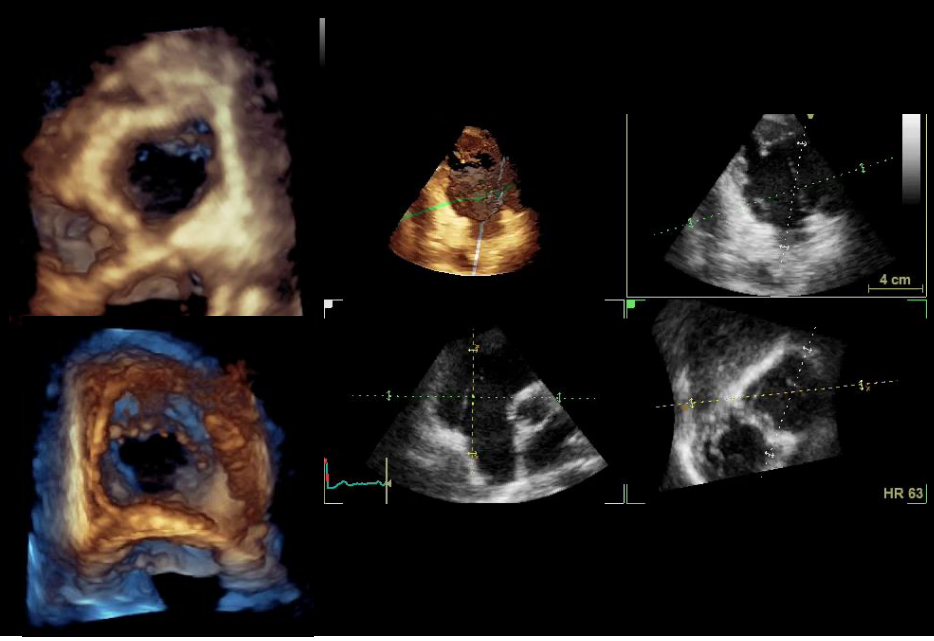

TV Imaging is Predominantly TTE

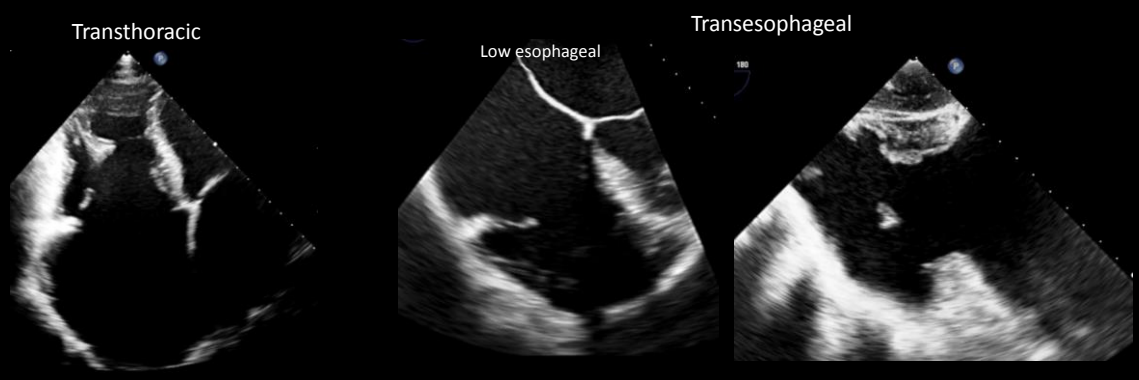

2D Echo TV Lesion Localization Is Plane Dependent

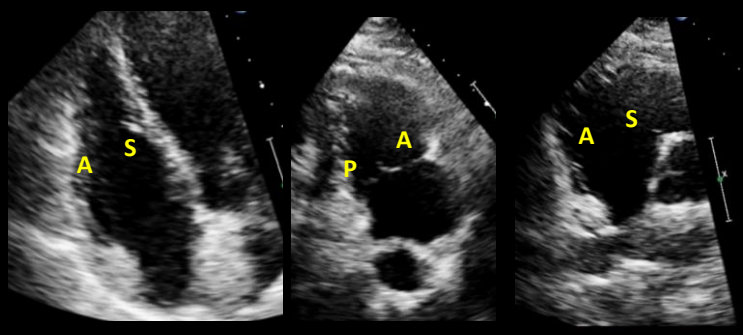

Septal	0%	100%	100%	0%	0%	48%
Anterior	100%	0%	0%	100%	0%	52%
Posterior	0%	0%	0%	0%	92%	0%

Anwar et al. Int J Cardiovasc Imaging. 2007 Dec;23(6):717-24.

Anatomy with 3D Echo

Normal

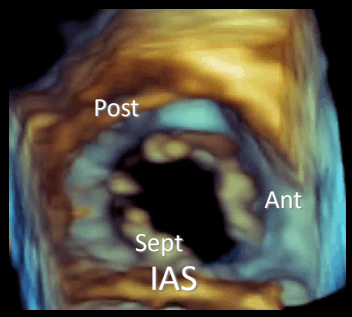

Right Ventricular Perspective

Carcinoid

Functional

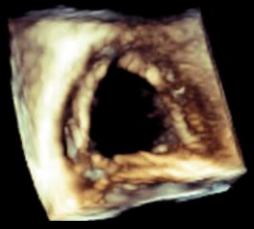

Dysplastic Valve

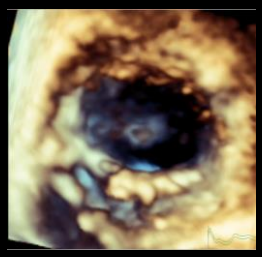

PHTN

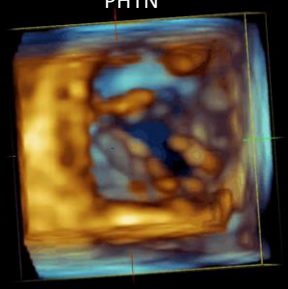

Anatomy with 3D Echo -Pacemakers

No Impingement

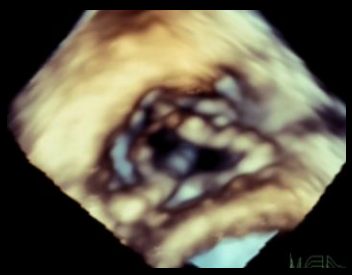

Impingement

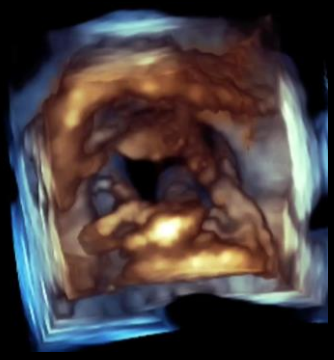

3D TTE Can Identify Lead Position in 90% of Patients

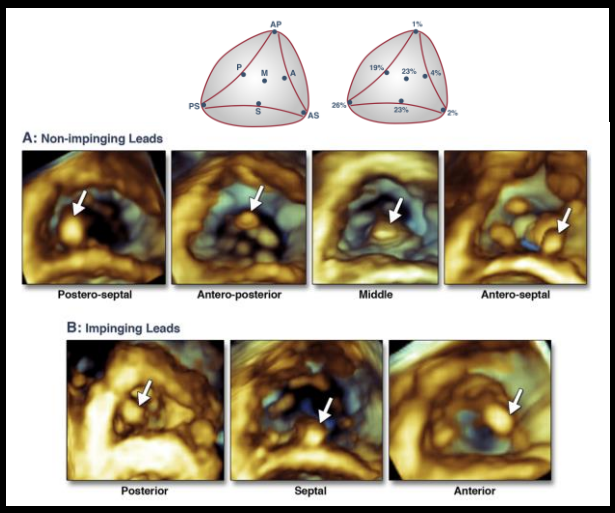

Mediratta, A. et al. J Am Coll Cardiol Img 2014;7:337–47

TV Annular Enlargement

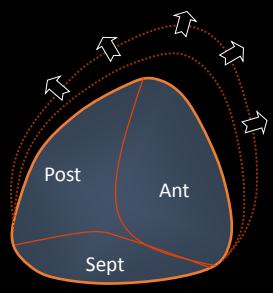

Secondary TR Management

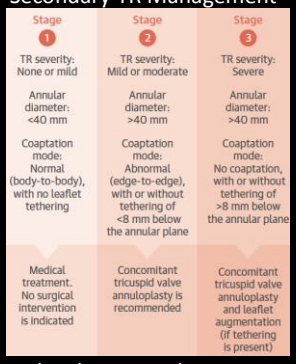

Stage 1	Stage 2	Stage 3
TR severity: None or mild	TR severity: Mild or moderate	TR severity: Severe
Annular diameter: <40 mm	Annular diameter: >40 mm	Annular diameter: >40 mm
Coaptation mode: Normal (body-to-body), with no leaflet tethering	Coaptation mode: Abnormal (edge-to-edge), with or without tethering of <8 mm below the annular plane	Coaptation mode: No coaptation, with or without tethering of >8 mm below the annular plane
Medical treatment. No surgical intervention is indicated	Concomitant tricuspid valve annuloplasty is recommended	Concomitant tricuspid valve annuloplasty and leaflet augmentation (if tethering is present)

- There is a linear relation between tricuspid valve annulus diameter and regurgitant volume
- In secondary TR, annular dilatation is a marker of severity
  - >40 mm or 21 mm/m^2 in diastole 4-chamber view
- Mild TR can be seen in those with normal tricuspid valve leaflets and annular dimensions

Dreyfus GD et al. J Am Coll Cardiol 2015;65:2331–6

2D Echo Underestimates Tricuspid Annular Diameter

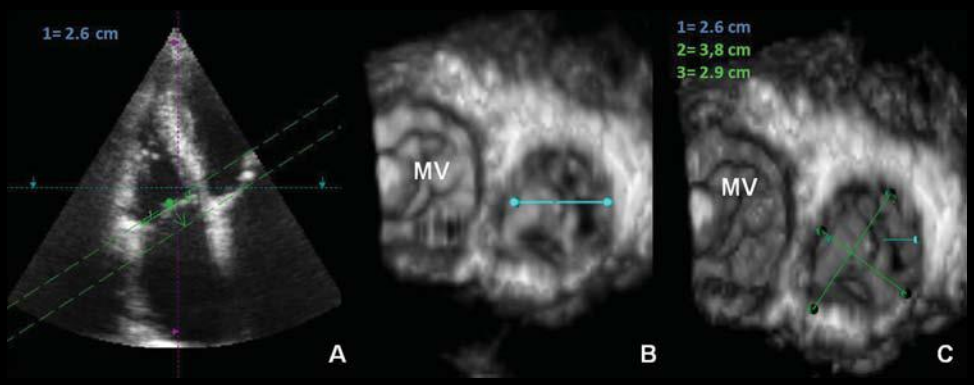

Badano et al. Eur J Echo. 2009:10;477-84

3D Tricuspid Annular Measurements

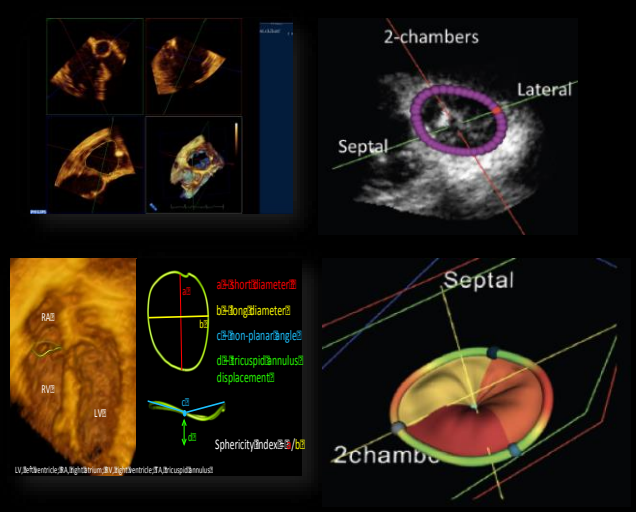

Tsang et al. JASE. 2012; 25(6): B79
Muraru D et al. Korean Circ J 2016;46(4):443-455

GUIDELINES AND STANDARDS

EAE/ASE Recommendations for Image Acquisition and Display Using Three-Dimensional Echocardiography

Promising Clinical Trials
LV Mass
RV Volumes/Function
Ao Anatomy
Ao Stenosis

LV Mass Measurement

2D biplane

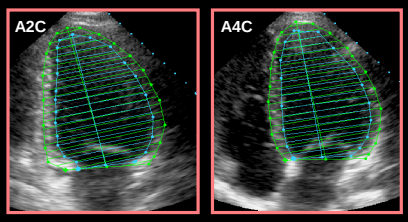

3D-guided biplane

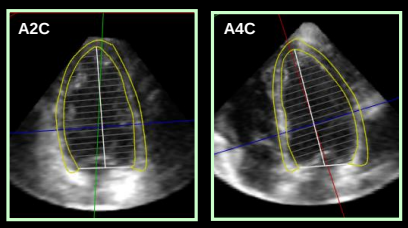

MRI reference

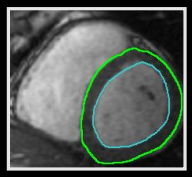

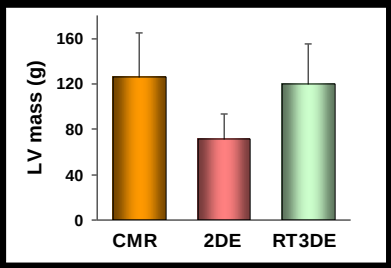

- Mor-Avi V, et al. *Circulation 2004; 110, 1814-1818*

RV Volumes/Function



3D ECHO ASSESSMENT OF THE RIGHT HEART

Validation vs. Cardiac Magnetic Resonance

	Population characteristics	RV EDV mL (95%CI)	RV ESV mL (95%CI)	RV EF mL (95%CI)
Shimada *et al.* (2010)	Meta-analysis (n=807)	**-13.9** (-17.7, -10.1)	**-5.5** (-7.6, -3.4)	**-0.9** (-1.8, -0.1)
Grapsa *et al.* (2010)	Normal subjects (n=20)	**-1.5** (-4.57, 1.57)	**0.80** (-1.35, 2.95)	**-1.3** (-3.1, 0.5)
Grapsa *et al.* (2010)	PAH (n=60)	**-3.7** (-10.96, 3.56)	**-0.02** (-6.19, 6.15)	**-1.3** (-3.07, 0.47)
Sugeng *et al.* (2010)	Patients (n=28)	**-14** (-27.8, -0.2)	**-9** (-19.2, 1.2)	**-2** (-4.27, 0.27)
van der Zwaan *et al.* (2010)	CHD (n=50)	**-34** (-43.26, -24.74)	**-11** (-18.71, -3.29)	**-4** (-5.91, -2.09)
Leibundgut *et al.* (2010)	Patients (n=88)	**-10.2** (-14.63, -5.77)	**-4.5** (-7.53, -1.47)	**-0.4** (-1.97, 1.17)

Badano LP, et al. J Cardiovasc Ultrasound 2012

Elliptical Ao Annulus

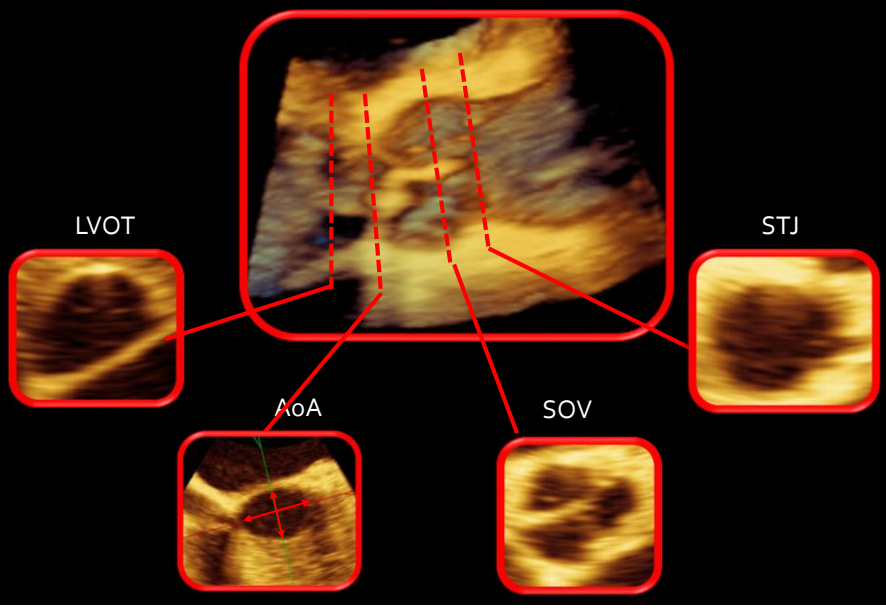

Automated Aortic Root Assessment

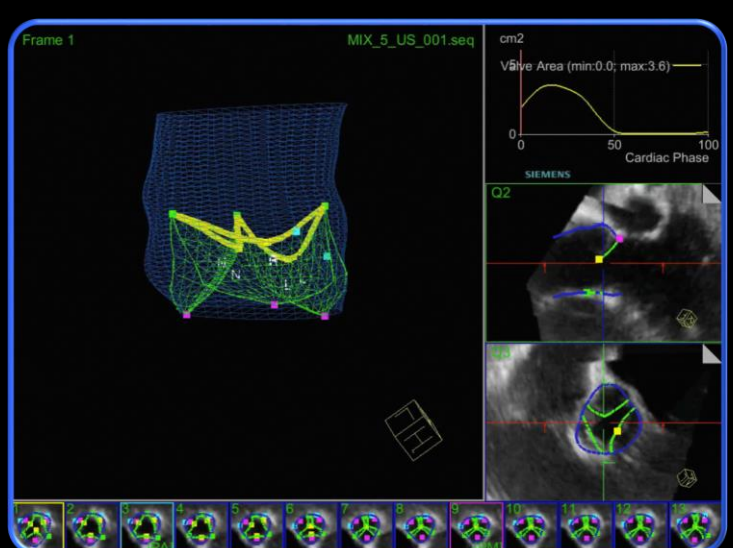

GUIDELINES AND STANDARDS

EAE/ASE Recommendations for Image Acquisition and Display Using Three-Dimensional Echocardiography

Areas of Active Research
LV Shape
LV Dyssynchrony
LA Volumes
MV Regurgitation
Prosthetic Valves

LV Shape

LA Volumes



Prosthetic Valves

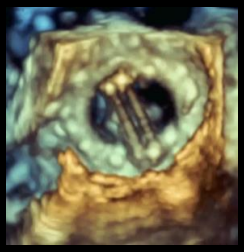

LV Dyssynchrony



MV Regurgitation

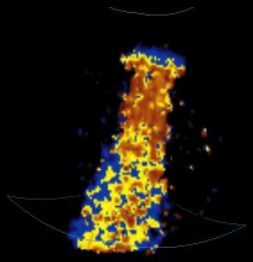

Thank you for listening

“Easy” Applications

Technique	Application

Cropping	• Display and understand the anatomy
	  • Tricuspid valve
	  • Mitral valve

Multi-planar reconstruction	• Improve measurements
	  • MV planimetry
	  • LVOT
	• Improves LV and RV assessment

Automated Analysis Programs	• LV volumes • LA volumes • RV volumes • SV measurement • MV