

Echocardiography in the Management of Patients with Left Ventricular Assist Devices: Recommendations from the American Society of Echocardiography

Raymond F. Stainback, MD, FASE, Chair, Jerry D. Estep, MD, FASE, Co-Chair, Deborah A. Agler, RCT, RDCS, FASE, Emma J. Birks, MD, PhD, Merri Bremer, RN, RDCS, EdD, FASE, Judy Hung, MD, FASE, James N. Kirkpatrick, MD, FASE, Joseph G. Rogers, MD, and Nishant R. Shah, MD, MSc, *Houston, Texas; Cleveland, Ohio; Louisville, Kentucky; Rochester, Minnesota; Boston, Massachusetts; Philadelphia, Pennsylvania; and Durham, North Carolina*

(J Am Soc Echocardiogr 2015;28:853-909.)

Keywords: Echocardiography, mechanical circulatory support, left ventricular assist devices, comprehensive examination

TABLE OF CONTENTS

Introduction	854	Patient Populations	891
Left Ventricular Assist Devices	855	Frequency and Extent of Echocardiography	891
The Role of Echocardiography in Candidate Selection	856	Laboratory Resources and Extent of Examination	891
LV Dysfunction	856	Referring/Community Hospitals	891
RV Dysfunction	857	Other Devices	892
Valve Disease	857	The Right Ventricle and Biventricular/RVAD Support	892
Congenital Heart Disease	858	Notice and Disclaimer	892
Other High-Risk Findings	859	Acknowledgments	892
Perioperative Transesophageal Echocardiography	860	References	892
Preimplantation TEE	860	Appendix A: Other FDA-Approved Pumps that may be Encountered	896
Perioperative TEE During LVAD Implantation	860	Percutaneous LVADs for Temporary Support	896
Perioperative TEE During Initial LVAD Activation and Speed Optimization	860	Surgically Implanted Extracorporeal Ventricular Assist Devices for Temporary Support	896
Role of Echocardiography (TTE or TEE) After LVAD Implantation	865	Right Ventricular Assist Devices	898
LVAD Surveillance Echocardiography	865	Appendix B: Recommended Pre-LVAD-implantation TTE Protocol	901
Echocardiography with Speed Changes and Safety Concerns	874	Appendix C: Perioperative TEE Protocol/Checklist	903
LVAD Optimization Echocardiography	876	Appendix D: Magnitude and Time Course of Echo LV Parameter Changes Induced by CF-LVAD Unloading	904
LVAD Problem-Focused Echocardiography	878	Appendix E: LVAD Surveillance Echo Protocol	906
Echocardiographic Assessment of Abnormal LVAD Alarms	882	Appendix F: LVAD Optimization/Ramp Echo Protocol	907
LVAD Recovery Echo Exam	888	Appendix G: Speed Changes: LVAD Optimization or Problem-Focused (Ramp) Protocol Worksheet	908
LVADs for Pediatric and Adolescent Patients	888	Appendix H: LVAD Recovery Protocol Worksheet	909
Other Areas of Research	890		
Indications for Other Imaging Methods After LVAD Implantation	890		
Summary/Discussion	890		

From the Texas Heart Institute, Houston, Texas (R.F.S.); Houston Methodist, Houston, Texas (J.D.E.); Cleveland Clinic, Cleveland, Ohio (D.A.A.); University of Louisville School of Medicine, Louisville, Kentucky (E.J.B.); Mayo Clinic, Rochester, Minnesota (M.B.); Massachusetts General Hospital, Boston, Massachusetts (J.H.); Hospital of the University of Pennsylvania, Philadelphia, Pennsylvania (J.N.K.); Duke University Hospital, Durham, North Carolina (J.G.R.); and Brigham and Women's Hospital, Boston, Massachusetts (N.R.S.).

Special contributions by Madhav Swaminathan, MD, FASE (ASE Council on Perioperative Echocardiography) and Theresa A. Tacy, MD (ASE Council on Pediatric and Congenital Heart Disease).

Authors are listed alphabetically.

The following authors reported no actual or potential conflicts of interest relative to this document: Raymond F. Stainback, MD, FASE; Deborah A. Agler, RCT, RDCS, FASE; Emma J. Birks, MD, PhD; Merri Bremer, RN, RDCS, EdD, FASE; Judy Hung, MD, FASE; James N. Kirkpatrick, MD, FASE; Joseph G. Rogers, MD. The following author reported relationships with one or more

commercial interests: Nishant R. Shah, MD, MSc, holds stock in GE. Jerry D. Estep, MD, FASE, serves as a consultant for Thoratec, Inc. and Maquet, Inc.

Attention ASE Members:

The ASE has gone green! Visit www.aseuniversity.org to earn free continuing medical education credit through an online activity related to this article. Certificates are available for immediate access upon successful completion of the activity. Nonmembers will need to join the ASE to access this great member benefit!

Reprint requests: American Society of Echocardiography, 2100 Gateway Centre Boulevard, Suite 310, Morrisville, NC 27560 (E-mail: ase@asecho.org). 0894-7317/\$36.00

Copyright 2015 by the American Society of Echocardiography.

<http://dx.doi.org/10.1016/j.echo.2015.05.008>

Abbreviations

2D = Two-dimensional
3D = Three-dimensional
A = Mitral valve late peak diastolic velocity
AR = Aortic regurgitation
Ao = Aorta/aortic root
AS = Aortic stenosis
ASD = Atrial septal defect
ASE = American Society of Echocardiography
AV = Aortic valve
BiVAD = Biventricular assist device
BP = Blood pressure
BTT = Bridge to transplantation
CCT = Cardiac computed tomography
CF = Continuous flow
CMS = Centers for Medicare & Medicaid Services
CPB = Cardiopulmonary bypass
CT = Computed tomography
CW = Continuous wave
DT = Destination therapy
e' = Mitral annular velocity
E = Mitral valve early peak diastolic velocity
ECMO = Extracorporeal membrane oxygenation
FAC = Fractional area change
FDA = Food and Drug Administration
HF = Heart failure
HM-II = HeartMate II left ventricular assist device
HVAD = HeartWare left ventricular assist device
IABP = Intraaortic balloon pump
IAC = Intersocietal Accreditation Commission
INR = International normalized ratio

INTERMACS = Interagency Registry for Mechanically Assisted Circulatory Support
IV = Intravenous
LA = Left atrial/atrium
LV = Left ventricular/ventricle
LVAD = Left ventricular assist device
LVEDV = left ventricular end-diastolic volume
LVEF = Left ventricular ejection fraction
LVIDd = Left ventricular internal dimension at end-diastole
LVOT = Left ventricular outflow tract
MAP = Mean arterial pressure
MCS = Mechanical circulatory support
MR = Mitral regurgitation
MRI = Magnetic resonance imaging
MS = Mitral stenosis
MV = Mitral valve
PFO = Patent foramen ovale
PDA = Patent ductus arteriosus
PI = Pulsatility index
PR = Pulmonary regurgitation
PS = Pulmonary stenosis
PT = Prothrombin time
PVAD = Percutaneous ventricular assist device
RA = Right atrial/atrium
RCA = Right coronary artery
rPA = Right pulmonary artery
RV = Right ventricular/ventricle
RVAD = Right ventricular assist device
RVOT = Right ventricular outflow tract
STE = Speckle tracking echocardiography
TAH = Total artificial heart

TAPSE = Tricuspid annular-plane systolic excursion
TEE = Transesophageal echocardiography
TR = Tricuspid regurgitation
TS = Tricuspid stenosis
TTE = Transthoracic echocardiography
VC = Vena contracta
VSD = Ventricular septal defect
VTI = Velocity-time integral

INTRODUCTION

This guideline addresses the role of echocardiography during the different phases of care of patients with long-term, surgically implanted continuous-flow (CF) left ventricular (LV) assist devices (LVADs). In patients with advanced heart failure (HF) refractory to medical therapy, LVADs have been used as a bridge to transplantation (BTT),¹ as destination therapy (DT),² as a bridge to transplant candidacy, or as a bridge to recovery.³ Over the past three decades, tremendous progress has been made in the

field of mechanical circulatory support (MCS), and more than 30,000 patients worldwide have received long-term LVADs.⁴ Recent guidelines endorse the important role of echocardiography in the clinical care of LVAD patients at several stages, including preoperative patient selection, perioperative imaging, postoperative surveillance, optimization of LVAD function, troubleshooting of LVAD alarms, and evaluation of native myocardial recovery.⁴ Despite increasing clinical use of LVADs,⁵ recognition of the central role of echocardiography in their management, and presentation of an exponentially expanding outpatient LVAD population to healthcare facilities not directly associated with implantation centers, there is a lack of published guidelines for echocardiography of LVAD recipients.

This American Society of Echocardiography (ASE) document uses both published data (albeit of limited availability at this time) and expert opinion from high-volume MCS-device implantation centers to provide consensus recommendations and sample protocols for the timing and performance of echocardiography during LVAD patient selection, device implantation, and postoperative management. The authors' goal is to provide a general framework for the interactions between echocardiography laboratories and MCS teams. Although numerous types of LVADs are in clinical use or under development, the scope of this document is primarily limited to current surgically implanted CF-LVADs that have been approved by the United States Food and Drug Administration (FDA) for extended use in adults. Pediatric and adult patients with congenital heart disease represent a smaller but important and increasing subpopulation of patients receiving extended-use MCS devices. Comments or recommendations specifically relating to pediatric and congenital heart disease patients will be noted within the text and within the pediatric LVAD discussion section. Surgically implanted LVADs for short-term use, percutaneously implanted LVADs, right ventricular (RV) assist devices (RVADs), and/or biventricular assist devices (BiVADs) may also be encountered by echocardiographers. A brief discussion of these devices and their applications is included in [Appendix A](#). Other MCS devices, including cardiopulmonary bypass (CPB) pumps, extracorporeal membrane oxygenation (ECMO), intraaortic balloon pumps (IABPs), and total artificial hearts (TAHs), are not covered in this report.

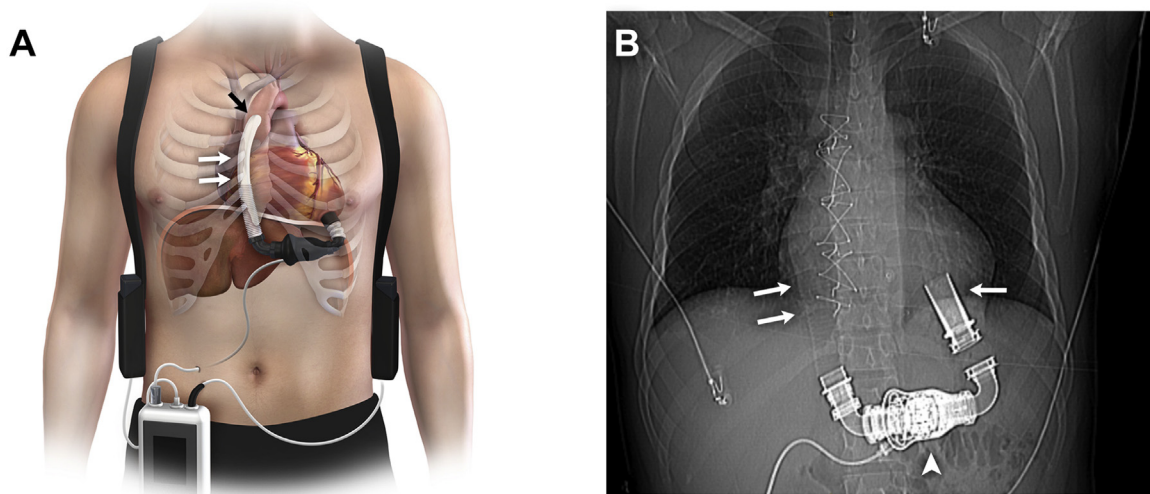


Figure 1 (A) Drawing of the HM-II LVAD, showing the subdiaphragmatic pump location, right parasternal outflow-graft position (*double white arrows*), and outflow graft-to-ascending aorta anastomosis (*black arrow*). (B) X-ray CT scout image showing the anatomic relationship between the left ventricle and the device inflow cannula (*single arrow*), impeller housing (*arrowhead*), and outflow graft (*double arrows*), controller (*white box*), battery packs (*black boxes*).

KEY POINTS

- This document addresses the role of echocardiography during the different phases of care of patients with FDA-approved long-term, surgically implanted CF-LVADs.
- The phases of patient care addressed include preoperative patient selection, perioperative TEE imaging, postoperative surveillance, optimization of LVAD function, problem-focused exams (when the patient has signs or symptoms of LVAD or native cardiac dysfunction), and evaluation of native myocardial recovery.
- Suggested protocols, checklists, and worksheets for each of these phases of care are located in the Appendices.
- Other types of MCS may also be encountered by echocardiographers, and these devices are discussed in [Appendix A](#).
- Although echocardiography is frequently used for managing LVAD therapy, published data intended to guide timing and necessary data collection remain limited. Some of the recommendations provided herein are based on expert consensus from high-volume MCS implant centers.
- Most LVAD recipients are adults with dilated cardiomyopathies. Other LVAD patient populations addressed within this document include those with smaller hearts (eg, resulting from restrictive cardiomyopathies) and those with pediatric and congenital heart disease.
- The authors' goal is to provide a general framework for the interactions between echocardiography laboratories and MCS teams.

LEFT VENTRICULAR ASSIST DEVICES

Selection of a particular LVAD for an individual patient is a complex decision-making process and is beyond the scope of this document. Readers are referred to recent reviews for a comprehensive explanation of the structure and function of long-term, surgically implanted, intracorporeal (pump inside the body) LVADs⁶ and of short-term, surgically or percutaneously implanted, extracorporeal (pump outside the body) LVADs⁷ which are described in [Appendix A](#). Currently, two CF-LVADs are approved by the FDA for surgical implantation in adults—the HeartMate II (HM-II) Left Ventricular Assist System (Thoratec Corporation, Pleasanton, CA) ([Figure 1](#)) and the HVAD Ventricular Assist System (HeartWare International, Inc., Framingham, MA) ([Figure 2](#)). The HM-II received FDA approval for

BTT therapy in April 2008⁸ and for DT in January 2010.⁹ The HeartWare HVAD received FDA approval for BTT therapy in November 2012,¹⁰ and a DT trial of this system is ongoing. For brevity, the abbreviation “LVAD” will be used here when referring to either of these CF-LVADs.

Common to both the HM-II and the HVAD are three components in series: (1) an inflow cannula positioned in the left ventricle near the apex, (2) a mechanical impeller, and (3) an outflow graft anastomosed to the ascending aorta ([Figures 1 and 2](#)). Echocardiography allows direct visualization of the proximal inflow cannula and the distal outflow graft but not of the mechanical impeller. The HM-II impeller and its housing structure are implanted below the diaphragm, whereas the HVAD impeller and its housing structure are implanted above the diaphragm, within the pericardial sac. Discussed in further detail below, impeller positioning is the primary differentiating factor in the echocardiographic evaluation of the inflow-cannula flow of these two devices. In other respects, echocardiographic evaluation of the two pumps is similar. Furthermore, both the HM-II and the HVAD are powered by a driveline connected to an extracorporeal controller. In addition to serving as a power source, the controller continually measures and calculates a number of parameters related to LVAD function. When these parameters fall outside predetermined normal ranges, the controller alerts the patient and the HF team that there is a problem. The implications of controller alarms for echocardiography are further discussed below.

KEY POINTS

- Current CF-LVADs have three intracorporeal (inside the body) components: an LV inflow cannula, a mechanical impeller, and an outflow graft that is anastomosed to the ascending aorta.
- The mechanical impeller is attached to an extracorporeal (outside the body) controller device via a driveline that provides power and a data link. The controller monitors several LVAD-related parameters and may generate device alarms. In turn, these alarms may indicate the need for an echocardiogram to validate the alarm and provide a definitive diagnosis.
- Echocardiography techniques for different devices are generally similar, except for important differences noted in the text.

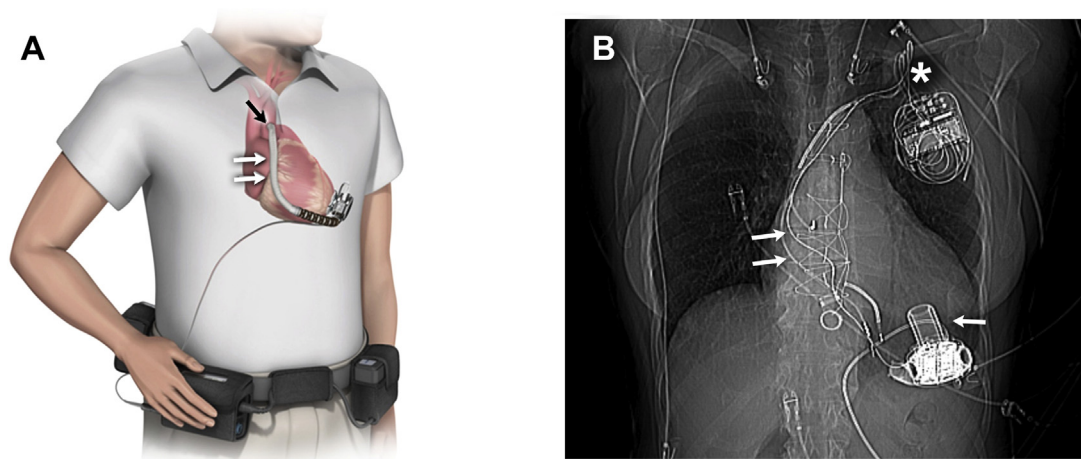


Figure 2 (A) Drawing of the HVAD, showing the intrapericardial pump location, right parasternal outflow graft position (*double white arrows*), and outflow graft-to-ascending aorta anastomosis (*black arrow*). (Courtesy of Heartware, Inc.) (B) X-ray CT scout image showing the anatomic relationship between the left ventricle and the device inlet cannula with its attached intrapericardial pump (*single arrow*). Although not visible here, the outflow graft would typically be imaged in the right parasternal area (*double arrows*). The asterisk denotes a cardiac implantable electronic device.

THE ROLE OF ECHOCARDIOGRAPHY IN CANDIDATE SELECTION

Optimal candidate selection is one of the most important determinants of a successful operative and long-term outcome for LVAD recipients.⁴ Transthoracic echocardiography (TTE) is generally the first-line imaging modality used to screen LVAD candidates for structural and/or functional abnormalities that represent absolute or relative contraindications to device implantation. In some cases, patients require urgent or emergent surgical LVAD placement. In these acute situations, adequate TTE information may be technically limited or unavailable. Therefore, transesophageal echocardiography (TEE) performed in the acute setting (catheterization laboratory, emergency department, intensive care unit, or operating room) should address all of the factors mentioned below with regard to TTE. Given its central role in LVAD candidate selection, preimplantation TTE or TEE (when necessary) should be performed in a laboratory that has been accredited by the Intersocietal Accreditation Commission (IAC)¹¹ and should be supervised and interpreted by a skilled echocardiographer¹² who is experienced in advanced HF evaluation and the hemodynamic assessment of MCS devices. Preimplantation TTE in LVAD candidates should include all the elements of a comprehensive examination as recommended by the ASE,¹³ with a particular focus on the high-risk or “red-flag” findings detailed below and summarized in [Table 1](#). A comprehensive, checklist-based preimplantation TTE protocol with the notation of red-flag findings is available in [Appendix B](#). If preimplantation TTE yields inconclusive findings, TEE may be performed, as described below. If a recently performed high-quality TTE exam includes most but not all of the required preimplantation exam elements and there has been no interval change in the patient’s clinical status, a limited, focused follow-up exam to obtain the additional necessary information may be acceptable.

LV Dysfunction

Severe LV systolic dysfunction resulting from a dilated cardiomyopathy characterizes the majority of LVAD recipients. Accordingly, echocardiography laboratories must be proficient in techniques for measuring LV size, ejection fraction (LVEF), and cardiac output.

LV Ejection Fraction. Demonstration of an LVEF of <25% is a Centers for Medicare & Medicaid (CMS)-qualifying condition for LVAD implantation as DT.¹⁴ Additionally, the LVEF is a component of both the Seattle Heart Failure Model¹⁵ and the Heart Failure Survival Score,¹⁶ two clinical-risk scoring tools that are widely used by HF specialists to calculate patients’ expected survival times and, by extension, their suitability for an LVAD. A severely decreased LVEF is by no means the only clinical parameter used for determining whether or not a patient is referred for MCS. However, its accurate measurement by echocardiography is of paramount importance. Previous ASE guidelines describe the recommended methods for echocardiographic LV chamber quantification.¹⁷⁻¹⁹ On the basis of those guidelines, laboratories with the ability and expertise to perform three-dimensional (3D) assessment for determining LV volumes and the LVEF should routinely do so when imaging conditions permit; otherwise, they should use the biplane method of disks (modified Simpson’s rule) from two-dimensional (2D) images. Strong consideration should be given to the use of a microbubble contrast agent when indicated to enhance endocardial definition and improve the precision of LVEF measurement.²⁰

LV Internal Dimension at End-Diastole. In addition to the LVEF, the LV internal dimension at end-diastole (LVIDd) from 2D parasternal long-axis images is a critical measurement in LVAD candidates. For patients who eventually undergo LVAD implantation, comparison of the preoperative LVIDd to the postoperative LVIDd is the primary clinical measure of the degree of LVAD-mediated LV unloading. Whereas a comparison of pre- and postoperative LV end-diastolic volumes (LVEDVs) would better quantify LV unloading, these measurements can be extremely challenging to obtain in the immediate postoperative period, when standard echocardiographic windows are limited by supine positioning, mechanical ventilation, a recent sternotomy, bandages, and other physical barriers. While the LVIDd and LVEDV are moderately to severely increased in most patients considered for an LVAD, limited data suggest that a smaller LV cavity, defined by an LVIDd of <63 mm, is associated with increased 30-day morbidity and mortality rates after LVAD implantation.²¹ Patients who tend to have smaller LV cavities include elderly women with a smaller body habitus and persons with

Table 1 Preimplantation TTE/TEE “red-flag” findings

Left Ventricle and Interventricular Septum
Small LV size, particularly with increased LV trabeculation
LV thrombus
LV apical aneurysm
Ventricular septal defect
Right Ventricle
RV dilatation
RV systolic dysfunction
Atria, Interatrial Septum, and Inferior Vena Cava
Left atrial appendage thrombus
PFO or atrial septal defect
Valvular Abnormalities
Any prosthetic valve (especially mechanical AV or MV)
> mild AR
≥ moderate MS
≥ moderate TR or > mild TS
> mild PS; ≥ moderate PR
Other
Any congenital heart disease
Aortic pathology: aneurysm, dissection, atheroma, coarctation
Mobile mass lesion
Other shunts: patent ductus arteriosus, intrapulmonary

AR, Aortic regurgitation; AV, aortic valve; LV, left ventricular; MS, mitral stenosis; MV, mitral valve; PFO, patent foramen ovale; PR, pulmonary regurgitation; PS, pulmonary stenosis; RV, right ventricle; TR, tricuspid regurgitation; TS, tricuspid regurgitation.

Note: These red-flag findings are found within the Recommended Pre-LVAD-Implantation TTE Protocol (Appendix B). They are also found within the Perioperative TEE Protocol/Checklist (Appendix C), which contains additional immediate post-LVAD-implantation perioperative TEE red-flag findings.

infiltrative cardiomyopathies (eg, amyloidosis). The latter group may also have concomitant right-sided HF, another preoperative high-risk finding that is discussed below. Whereas a small LV cavity is not an absolute contraindication to LVAD implantation, the presence of this finding should be communicated to the HF team.

Intracardiac Thrombi. An intracardiac thrombus is not an absolute contraindication for LVAD implantation but may increase the risk of stroke during the LV cannulation portion of the procedure. At particularly increased risk for LV thrombus are patients with a severely decreased LVEF and/or an LV aneurysm. In these patients, strong consideration should be given to the use of a microbubble contrast agent during assessment for LV thrombus. If such a thrombus is identified, the implanting surgeon should be made aware of its size and location so that the thrombus can be carefully removed during device implantation. In borderline cases, cardiac computed tomography (CCT) may be adjunctively used to rule out an LV thrombus.⁴ In patients with atrial fibrillation, who are at increased risk for thrombus in the left atrial appendage, adjunctive TEE may be required for complete intracardiac thrombus assessment.

RV Dysfunction

Echocardiographic signs of RV dysfunction include impaired RV systolic function and/or RV dilatation, increased RA pressure (ascertained by inferior vena cava size and collapsibility), and moderate or greater tricuspid regurgitation (TR). Previous ASE guidelines describe

the recommended methods for echocardiographic evaluation of RV function and chamber quantification.^{17,18,22} On the basis of those guidelines, 3D echocardiographic assessment of RV volumes to calculate the RV ejection fraction would be ideal, but the authors realize that this approach is technically challenging and not widely available. Measurement of other secondary echocardiographic surrogates of RV systolic function, including RV fractional area change (FAC), tricuspid annular-plane systolic excursion (TAPSE), and RV free-wall peak longitudinal strain, can be difficult in patients with advanced HF. Nonetheless, quantitative measures of RV function are recommended for use whenever possible, but only when able to be properly measured in a given patient. At a minimum, a qualitative assessment of RV size and systolic function and of TR severity should be performed and communicated in the interpretation.

Echocardiographic signs of RV dysfunction should not be considered in isolation. They should be integrated with a patient’s clinical signs and symptoms of possible right-sided heart failure syndrome. Clinically severe preoperative RV dysfunction may prompt the HF team to consider planned biventricular MCS, as this may lead to better outcomes than delayed conversion of an LVAD to biventricular MCS.²³ Some patients with less than severe RV dysfunction at preoperative assessment will develop severe RV dysfunction after LVAD implantation. This complication, defined by the Interagency Registry for Mechanically Assisted Circulatory Support (INTERMACS)²⁴ as the requirement of an RV assist device (RVAD) or >14 consecutive days of intravenous (IV) inotropic support, has an estimated prevalence of 13% to 44% and is associated with significant morbidity and mortality.^{25,26} Preliminary data suggest that there may be preoperative echocardiographic parameters predictive of severe postoperative RV dysfunction. In studies that included clinical parameters in their multivariable models, an RV absolute peak longitudinal strain of <9.6%²⁷ and an RV: LV end-diastolic diameter ratio of >0.75²⁸ were identified as potential independently predictive echocardiographic parameters. More recent data by Kato and colleagues²⁹ suggests that the accuracy for predicting post LVAD RV failure may be improved when more than one RV echocardiographic parameter (in this case RV tissue Doppler imaging and RV speckle tracking imaging [RV longitudinal strain]) are used in aggregate. Given the lack of consensus thus far regarding the predictive value of any single echocardiographic parameter, an aggregate assessment utilizing relevant left-sided parameters (eg, indexed left atrial volume, indexed LV size) and right-sided parameters (eg, RV parameters described above, TR severity,³⁰ and right atrial [RA] pressure estimation) is likely the optimal approach for now.^{4,31}

KEY POINTS

- Nearly all LVAD candidates undergo echocardiography to screen for structural and/or functional abnormalities that preclude LVAD implantation or that may alter surgical planning.
- At this time, the literature does not support the use of any single echocardiographic RV parameter for predicting the post-LVAD prognosis or the need for biventricular support (RVAD use).
- Quantitative echocardiographic parameters of RV function (which may vary among patients, depending upon imaging conditions), should be integrated with clinical signs and symptoms to determine the degree of preoperative RV dysfunction, which may impact the operative plan and/or postoperative prognosis.

Valve Disease

Previous ASE guidelines address detection and quantitation of valvular regurgitation,³² valvular stenosis,³³ and prosthetic valve dysfunction.³⁴

Valve Stenosis. In patients with advanced HF and a severely reduced stroke volume, spectral Doppler-derived valve gradients in isolation may not accurately reflect the degree of valvular stenosis. In these patients, calculation of the valvular orifice area may be more accurate. Moderate or severe mitral valve (MV) stenosis can prevent adequate LVAD cannula inflow. Accordingly, significant mitral stenosis (MS) must be corrected before LVAD implantation. In contrast, aortic stenosis (AS) of any severity may be present without affecting LVAD function, because LVADs completely bypass the native LV outflow tract (LVOT). It is important to note, however, that patients who have critical AS or who undergo surgical aortic valve (AV) complete closure to correct aortic regurgitation (AR) will have no forward flow in the event of obstructive LVAD failure, even if residual LV function is present.

Valve Regurgitation. Exclusion of significant AR before LVAD implantation is critical and sometimes challenging. When present at LVAD implantation, significant AR enables a “blind” loop of flow in which blood enters the LVAD from the left ventricle, is pumped into the ascending aorta, but then flows back into the left ventricle through the regurgitant aortic valve. It may be difficult for echocardiographers to determine the degree of AR present in patients with advanced HF and a severely reduced LV stroke volume. Heart failure patients with moderate or severe AR may have unimpressive color-flow Doppler images and low AR velocities due to low systemic pressures and high LV diastolic pressures. Additionally, the aortic regurgitant volume may be relatively low, despite a high regurgitant fraction. Accordingly, the Doppler-derived LVOT stroke volume and regurgitant fraction should be calculated routinely when possible.³² Furthermore, there should be a high level of suspicion for significant AR in the presence of aortic root dilatation, eccentric AR (particularly if associated with a bicommissural AV), rheumatic or calcific AV degeneration, or an aortic prosthesis. TEE should be strongly considered when there is any degree of suspected abnormal prosthetic valve regurgitation. The presence of more than mild AR should be communicated to the implanting surgeon, because recent guidelines advise confirmation by perioperative TEE and surgical correction of AR before LVAD implantation.⁴ Surgical treatment options for significant native valve AR include replacement with a bioprosthesis, completely oversewing the valve (by suturing along all coaptation zones) or by performing a central coaptation (Park) stitch.³⁵ Completely over sewing the AV cusps effectively eliminates AR, but (as mentioned above) leaves the patient with no fail-safe means of LV ejection in the event of LVAD failure. When the aortic cusp integrity is good, a central coaptation (Park) stitch technique can treat central AR while allowing aortic forward flow through the residual commissural zones to occur during reduced LVAD support (Figure 3) or in the event of LVAD pump failure.

Mitral regurgitation (MR) that is significant preoperatively is often markedly improved after initiation of LVAD support, because of reduced LV size, reduced filling pressures, and improved coaptation of the MV leaflets. For this reason, any degree of MR is acceptable in LVAD candidates. In contrast, moderate or greater TR is a potentially ominous finding, which may indicate RV dysfunction as mentioned above. It is important to communicate the presence of significant TR to the implanting surgeon; recent guidelines recommend that surgical tricuspid valve repair be considered at the time of LVAD implantation.⁴ Pulmonary regurgitation (PR) may be more commonly encountered in patients with congenital heart disease. In any patient, moderate or greater PR could contribute to preoperative RV dysfunction and would require repair in the event of RVAD implantation. However, PR may be well tolerated in the setting of successful LVAD implantation with adequate RV function and successful LV un-

loading. However, significant PR could potentially contribute to RV dysfunction after LVAD implantation if pulmonary vascular resistance were increased for any reason, including acquired pulmonary disease or an inability to adequately unload the left ventricle.

Prosthetic Valves. When indicated, prosthetic valve assessment by TTE and TEE is critical for surgical decision-making. LVAD-supported patients must receive systemic anticoagulation, regardless of the presence of mechanical prosthetic valves. However, a higher target prothrombin time international normalized ratio (PT INR) may be necessary if a mechanical valve is present. After initiation of LVAD support, the inherent reduced flow through a mechanical AV prosthesis further increases the risk of postoperative valvular or aortic root thrombosis and subsequent thromboembolic events. For this reason, replacement of even a normally functioning mechanical AV prosthesis with a bioprosthesis or valve closure should be considered at the time of LVAD implantation. Adequately functioning bioprosthetic AVs do not require removal or replacement. Similarly, surgical replacement of a normally functioning mechanical MV prosthesis is typically not recommended, even if significant MR is present, as obligatory forward transmitral flow will occur during MCS. An important exception is the presence of moderate or worse mechanical MV stenosis. In these cases, consideration should be given to MV replacement with a bioprosthesis at LVAD implantation.⁴ Although not frequently encountered, tricuspid or pulmonary valve prosthesis dysfunction is an important finding, as it could adversely affect postoperative RV function.

KEY POINTS

- The position, type, and functioning of any prosthetic valve can have an important impact on surgical and postoperative management, and adjunctive TEE imaging should be performed if clinically indicated.
- Aortic regurgitation warrants special attention, as it can easily be underestimated in HF patients, generally worsens after LVAD activation, and impairs LV unloading due to a “blind loop” of aorta → LV → LVAD flow.
- Moderate or greater TR is an ominous finding, especially if accompanied by other signs or symptoms of RV dysfunction.
- A mechanical AV should be replaced before LVAD implantation.
- Severe AS and even complete AV closure can be tolerated after LVAD implantation, although either of these conditions results in the lack of a fail-safe mechanism for LV output in the event of LVAD failure.
- Mitral regurgitation is generally well tolerated and may improve after LVAD implantation.

Congenital Heart Disease

For all patients with known congenital heart disease of any severity, previous imaging studies documenting cardiac morphology, shunts, collateral vessels, and/or the location and course of the great vessels should be reviewed.⁴ Recent data suggest that with amenable cardiac anatomy, even patients who have complex congenital heart disease can undergo implantation of an LVAD as a BTT or as DT.³⁶ Some common anomalies require correction before LVAD implantation. A patent foramen ovale (PFO), present in up to 30% of the general population, increases the risk of hypoxemia^{37,38} and paradoxical embolization in patients receiving LVAD support. For this reason, PFOs or any other interatrial communications should be closed at the time of device implantation.⁴ In evaluating patients with advanced HF for atrial septal defects (ASDs) and PFOs, the use of IV agitated saline combined with an appropriately performed Valsalva maneuver is necessary, because

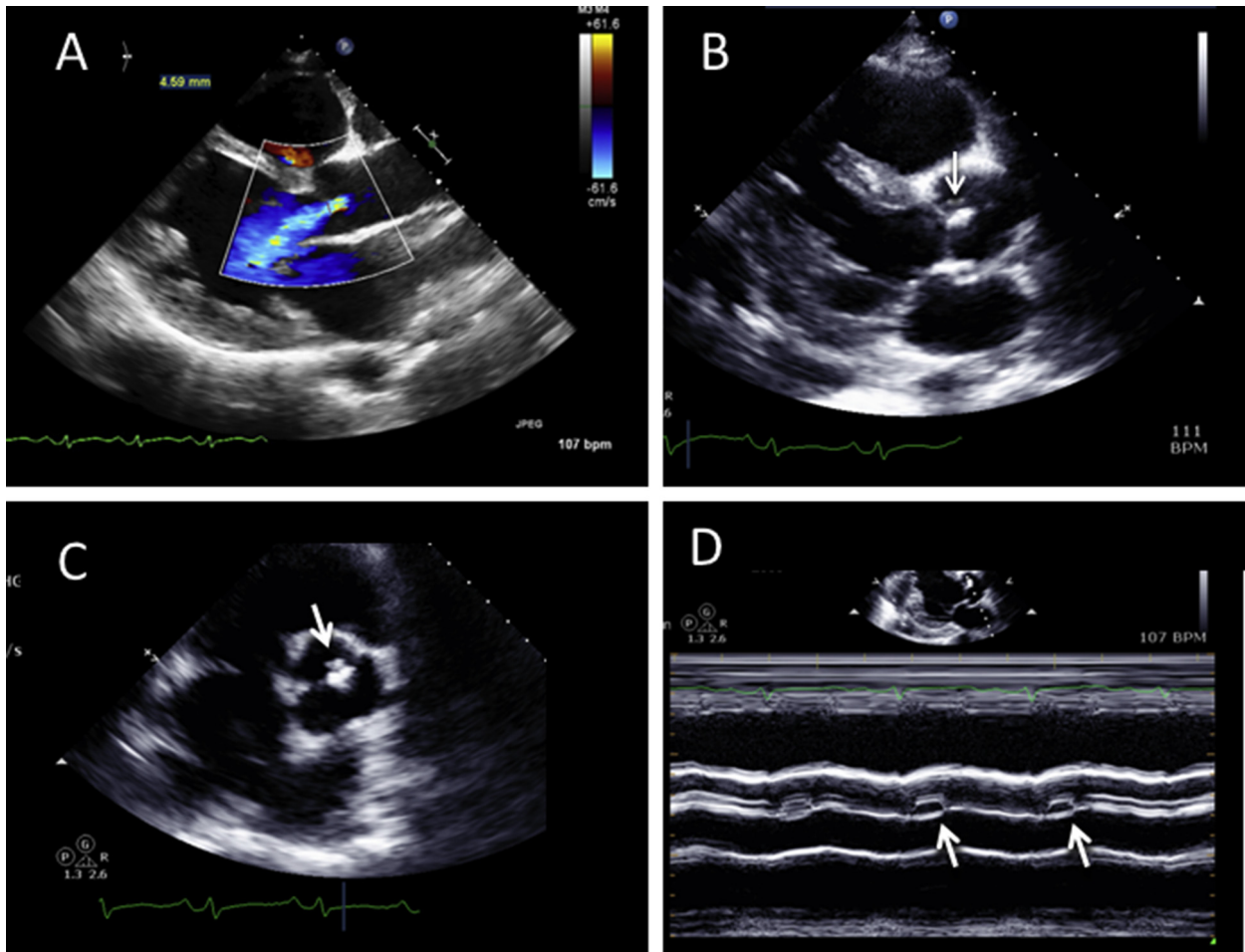


Figure 3 (A) TTE color Doppler shows moderate central AR before LVAD implantation. Intraoperative assessment revealed subtle cusp prolapse with good tissue integrity, so a central coaptation (*Park*) stitch was placed. See also [Video 1](#). (B) TTE 2D imaging of the AV shows the central coaptation stitch in the parasternal long axis (B) and short axis (C) (arrows). See also [Videos 2](#) and [3](#). M-mode imaging (D) shows residual cusp separation near the cusp commissures during reduced LVAD pump speed, but no residual AR was present.

elevated left and/or RA pressures may reduce interatrial pressure gradients and preclude detection of the defect by color Doppler imaging or agitated saline injection alone.³⁹ Like ASDs, congenital and post-myocardial infarction ventricular septal defects (VSDs) can also result in immediate postimplantation right-to-left shunting with hypoxemia and a risk of paradoxical embolization during LVAD support. The presence of VSDs should be systematically excluded by color Doppler interrogation of the entire ventricular septum; if identified, VSDs should be closed at LVAD implantation. In most cases, an unrepaired VSD is an absolute contraindication to device implantation.⁴ However, selected patients with single ventricle physiology (and an unrepaired VSD) may be considered for an LVAD.

KEY POINTS

- In patients with congenital heart disease, echocardiography is an important complementary imaging modality after other, previous imaging studies have been reviewed.
- The echocardiography exam should systematically exclude the presence of a PFO or other intracardiac shunt, which should be electively repaired at the time of surgery to avoid sudden arterial oxygen desaturation after LVAD activation.

Other High-Risk Findings

Acute endocarditis (or any other active infection) is an absolute contraindication to MCS-device implantation because of the risk of bacterial seeding of a newly implanted LVAD.⁴ As a result, a mobile mass lesion suggestive of a possible vegetation is a high-risk finding. Diseases of the aorta that are relative or absolute contraindications to LVAD implantation (eg, significant aneurysmal dilatation, dissection) may be discovered on TTE. For this purpose, high parasternal long-axis, suprasternal notch, and subcostal views of the aorta should be attempted. TEE may be very useful for the diagnosis of thoracic aorta pathology. However, in the absence of contraindications to contrast agents, computed tomography (CT)⁴ or magnetic resonance imaging (MRI)—barring MRI contraindications⁴⁰—are preferred modalities for comprehensive imaging of the aorta before LVAD implantation.⁴

KEY POINTS

- Any findings suspicious for endocarditis should be further evaluated, as this is an absolute contraindication to LVAD implantation.
- Adjunctive CT and MR imaging may be necessary to adequately evaluate for aortic disease before LVAD implantation.

PERIOPERATIVE TRANSESOPHAGEAL ECHOCARDIOGRAPHY

Preimplantation TEE

Comprehensive perioperative TEE should be performed in the operating room before LVAD implantation, with additional imaging performed at the time of LVAD activation and after a period of stabilization. Preimplantation TEE is particularly important when urgent or emergent LVAD placement is required, in which case this modality may serve as the primary screening echocardiography examination. Previous guidelines describe the recommended approach for perioperative TEE^{41,42}. A comprehensive, checklist-based pre- and postimplantation perioperative TEE protocol with notation of red-flag findings is included in [Appendix C](#). The physician performing the examination should be a highly trained cardiologist with significant advanced TEE and perioperative TEE experience^{42,43} or a cardiovascular anesthesiologist with advanced perioperative TEE training.^{42,44,45} Among the most important aspects of preimplantation TEE are reevaluation of the degree of AR, determination of the presence or absence of a cardiac-level shunt, identification of intracardiac thrombi, assessment of RV function, and evaluation of the degree of TR. These and potentially other important conditions (eg, degree of MS, PR, prosthetic dysfunction, possible vegetations, aortic disease, etc.) may have been undiagnosed or underappreciated on previous imaging exams or may have progressed in the intervening time. Their presence may necessitate conversion of a planned “off-pump” case into one that requires CPB, a change from a limited thoracotomy to a sternotomy to enable needed repairs, or possibly biventricular MCS.

For the same reasons discussed above for TTE, the degree of AR on perioperative TEE may be underappreciated on color Doppler imaging during general anesthesia, because low mean arterial pressure and/or systemic vascular resistance may be present. As a result, adequate AR assessment may necessitate systemic blood pressure (BP) augmentation by vasopressor agents.⁴ With regard to PFO detection, thorough color Doppler scanning of the fossa ovalis margins at a low Nyquist-limit setting and IV injection of agitated saline may be inconclusive. In these cases, IV injection of agitated saline combined with a “ventilator” Valsalva maneuver may also be useful. This maneuver involves injecting agitated saline into a central IV line (eg, internal jugular) during a briefly sustained application of up to 30 cmH₂O of intrathoracic pressure and, on opacification of the right atrium, release of the intrathoracic pressure.⁴⁶ Even with this maneuver, in some cases, significant competitive inferior vena cava “negative contrast” flow in the fossa ovalis region can cause a false-negative PFO evaluation after saline injection into the superior vena cava. Injection of agitated saline into a femoral vein may increase PFO detection^{47,48} if such access is available. Despite all efforts, a PFO may not become apparent in some cases until MCS is initiated and the left atrial pressure is decreased.

KEY POINTS

- The preimplant perioperative TEE is an important confirmatory imaging study, which can identify previously underappreciated or undiagnosed pathologic conditions that may influence the surgical procedure.
- An LVAD perioperative TEE checklist can be useful for laboratory personnel (see [Appendix C](#)).
- Preimplantation TEE should include reevaluation of AR, RV function, TR, and the aorta. Cardiac-level shunts and intracardiac thrombi should be excluded.

- Evaluation for PFO may require special imaging maneuvers as outlined in the text. Despite best efforts, a PFO may not be able to be diagnosed prior to LVAD implantation.

Perioperative TEE During LVAD Implantation

Both the HM-II and the HVAD require coring in the region of the LV apex for inflow-cannula insertion. This part of the procedure is inevitably accompanied by some degree of entrained air on the left side of the heart. Subsequent de-airing maneuvers require continuous TEE guidance.⁴ The left atrium, left ventricle (including the LV apex and inflow cannula ([Figures 4 and 5](#)), aortic root, ascending aorta, outflow graft-to-ascending aorta anastomosis ([Figure 6](#)), and transverse and descending aorta should all be directly visualized and carefully inspected for signs of air.³⁹ The ostium of the right coronary artery (RCA) is situated anteriorly in the aortic root and is a common destination for air ejected from the left ventricle.⁴ Acute RV dysfunction or dilatation and/or an increase in the severity of TR should suggest the possibility of air embolization to the RCA, and this complication may resolve with watchful waiting. As during the LV coring procedure, the period immediately after separation from cardiopulmonary bypass and reinstatement of mechanical ventilation can be accompanied by the sudden appearance of new air bubbles originating from the pulmonary veins, left atrium, or left ventricle. This finding, if associated with signs of RV dysfunction from a presumed coronary air embolism, may signal the need for reinstatement of CPB and/or repeat de-airing maneuvers.⁴

Perioperative TEE During Initial LVAD Activation and Speed Optimization

Upon LVAD activation, the **device name** and the **initial pump speed** should be annotated on the imaging screen. Although the exact order of perioperative TEE views obtained after LVAD initiation may vary among centers, it is recommended that physicians follow an LVAD checklist-based protocol ([Appendix C](#)) to include all of the important components unique to postoperative LVAD assessment. [Table 2](#) lists possible abnormal findings detectable by echocardiography after LVAD implantation. Early imaging of the interatrial septum with color Doppler and with IV injection of agitated saline contrast to confirm the absence of an **atrial septal communication** is recommended. This is particularly important if initiation of LVAD support results in a sudden decrease in arterial oxygen saturation, the hallmark of an “unmasked” PFO or other right-to-left shunt ([Figure 7](#)). Next, the degree of AV opening and the degree of AR (if any) should be assessed. When there is no AV opening, this may be apparent with standard planar imaging. In many cases, the extent and duration of aortic cusp separation may be markedly reduced or only intermittent, depending upon the degree of LVAD support (pump speed). M-mode imaging of the AV in the long-axis view can be helpful for measuring and reporting the degree of AV opening ([Figure 8](#)). When there is minimal residual native LVOT forward flow, AV opening may be intermittent due to pulsus alternans in regular sinus rhythm or because of arrhythmias. A slow M-mode sweep speed (eg, 25 mm/sec to acquire more cardiac cycles) may be needed to adequately display intermittent AV opening ([Figure 8C-E](#)).

Aortic Regurgitation. A pump speed–dependent reduction in LV diastolic filling pressures and increased central aortic BP can lead to the appearance of more prominent AR on color Doppler imaging than was appreciated before pump implantation ([Figure 9A](#)). During

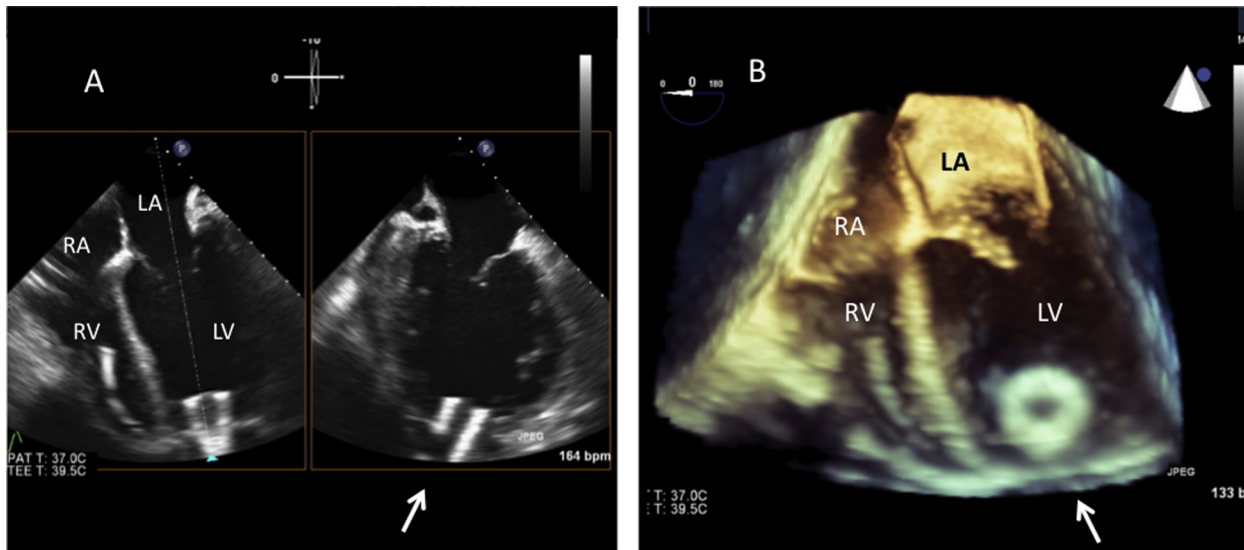


Figure 4 After LVAD implantation, TEE reveals a typical unobstructed inlet-cannula position (arrow) by means of simultaneous orthogonal-plane 2D (A) and real-time 3D imaging (B). See also Video 4. The relative RV to LV size appears normal. The right ventricle has a pacing lead.

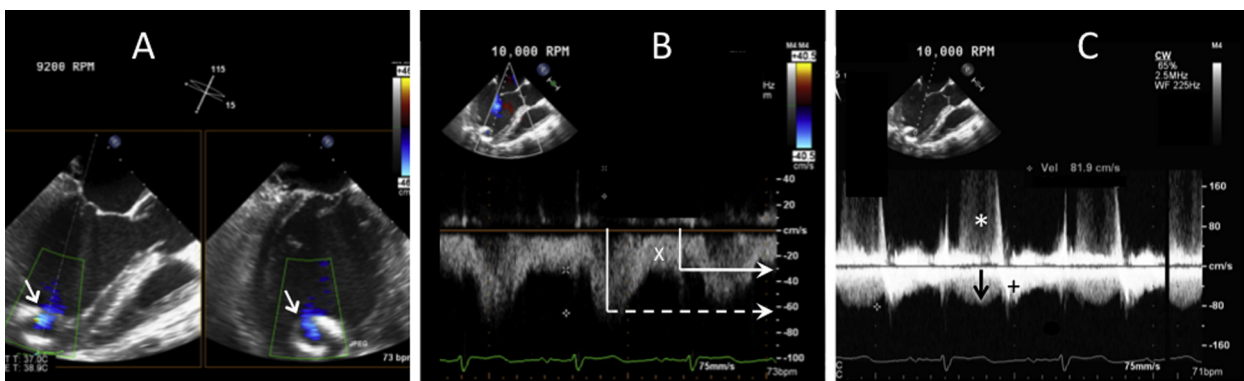


Figure 5 (A) After LVAD implantation, TEE shows that the inflow cannula is somewhat directed towards the ventricular septum (arrow). This can be acceptable but may predispose to inflow-cannula obstruction after sternal closure or later reduction in LV size. However, cannula position and flow velocities are shown to be acceptable (normal) in this case. Simultaneous orthogonal plane imaging reveals unobstructed, laminar inflow-cannula flow on 2D and color-flow Doppler (blue) examination. See also Video 5. (B) Pulsed Doppler interrogation of the inflow cannula shows a typical continuous, systolic dominant inflow pattern. Dashed arrow = peak systolic velocity; X = nadir diastolic velocity. (C) Continuous-wave spectral Doppler interrogation of the inflow cannula (to screen for inflow obstruction) shows normal inflow-cannula systolic flow (black arrow); “+” indicates a hybrid signal that results from overlapping of continuous diastolic inflow-cannula flow and diastolic MV inflow; “**”) indicates MR velocity.

LVAD support, AR can be intermittent (depending upon the valve opening duration), predominantly diastolic, nearly continuous (extending into the normal systolic phase of the cardiac cycle), or continuous (holosystolic and hodiastolic). Measuring the temporal occurrence of AR can be achieved with color M-mode and continuous-wave (CW) Doppler (see Figure 9F-G). The AR duration, AR vena contracta (VC) width, LVOT AR jet height, and other evidence of hemodynamically significant AR (discussed in further detail, below) should guide the need for possible surgical intervention on the AV. Although the AR VC width may be useful in a qualitative sense, during LVAD support, the width may vary throughout the cardiac cycle with continuous AR (Figure 9C) and at different pump speeds (Figure 9D,E). Methods for assessing AR severity in the context of an LVAD problem-focused exam are further discussed below. However, in keeping with previous guideline recommendations, a VC width of ≥ 0.3 cm or a jet width/LVOT width of $>46\%$ at a Nyquist limit of 50-60 cm/s³² should be

considered to indicate at least moderate (and possibly severe) AR, owing to the prolonged (if not continuous) duration of AR during LVAD support. Neither the AR pressure half-time method nor pulsed Doppler evaluation of aortic diastolic flow reversal is a reliable method for AR severity assessment after LVAD implantation. This is because the AR duration extends into the systolic ejection period. In addition, both of these methods are highly affected by LV preload, LV afterload, and aortic pulse pressure, which is diminished during LVAD support. However, CW spectral Doppler imaging may be useful for evaluating the timing and duration of AR (Figure 9F, G), and its pixel intensity may be additive to the qualitative assessment.

RV Dysfunction. Poor RV performance, with or without significant TR, immediately after LVAD initiation is not uncommon due to rapid normalization of the RV preload by the pump. Early RV dysfunction may be transient, due to CPB-related factors, or refractory, due to

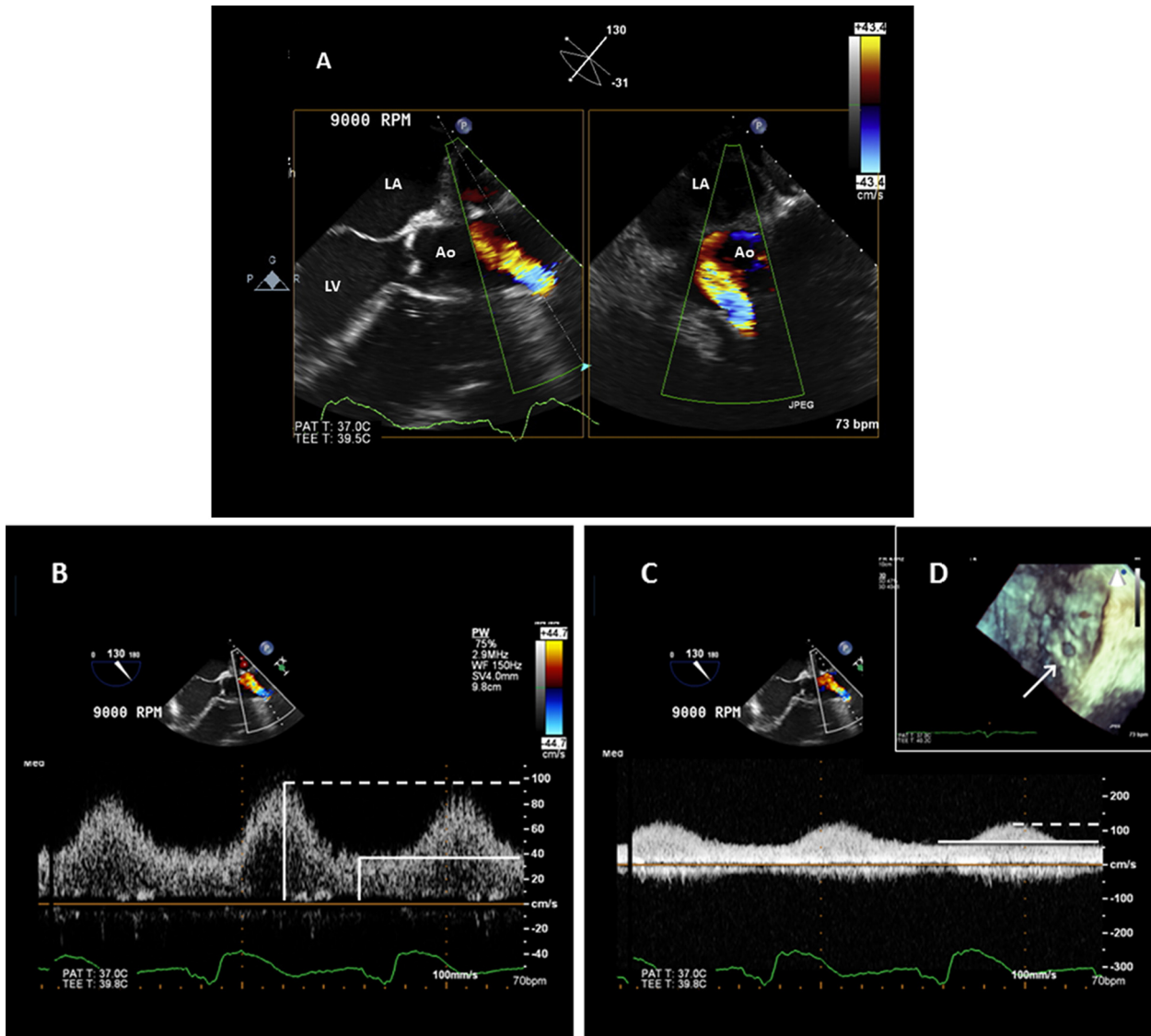


Figure 6 TEE of the outflow graft-to-ascending aorta anastomosis. **(A)** Simultaneous orthogonal plane 2D imaging with color-flow Doppler shows normal laminar color Doppler inflow. See also [Video 6](#). **(B)** Pulsed Doppler profile (peak velocity approximately 100 cm/s, dotted line). **(C)** Continuous-wave Doppler with a peak systolic velocity (dotted line) that, as expected, is somewhat higher (just >100 cm/s) than that revealed by pulsed Doppler. The solid line indicates the nadir diastolic velocity. **(D)** Typical circular appearance of unobstructed outflow graft-to-aorta anastomosis (arrow) using real-time 3D TEE, en face view.

underlying RV dysfunction. In this setting, significant TR may be present despite an “optimal” LVAD pump speed. However, an excessive LVAD pump speed may precipitate acute severe RV dysfunction with acute severe TR. When the LVAD pump speed is set too high, the left ventricle may become small (“sucked down” or “over-decompressed”), resulting in an abnormal RV-to-LV septal shift that causes distortion of the RV geometry, including the tricuspid valve annulus; this alteration precipitates or worsens TR, which, in turn, causes or exacerbates RV dysfunction. The cascade of events resulting from an excessive LVAD pump speed may ultimately result in a “suction event,” a condition in which a segment of the LV myocardium partially occludes the inflow cannula and reduces pump inflow. Suction events, along with the noted high-risk findings, can be quickly corrected by lowering the pump speed ([Figure 10](#)). Suction events can be related to other causes of reduced LV preload relative to the pump speed setting. Accordingly, rapid assessment of AV opening, the relative LV and RV sizes, degree of TR, ventric-

ular septal position, inflow-cannula position, and flow velocities is recommended after initiation of LVAD support and after changes in the LVAD pump speed. It is important that the updated pump speed is always reannotated on the screen during the course of the perioperative TEE exam. A suction event that occurs at a relatively low pump speed or ongoing severe RV dysfunction at low levels of LVAD support is an ominous sign that may indicate the need for a return to CPB or for biventricular support. Suction events can be related to other causes of a reduced LV preload (eg, hypovolemia) or a low afterload (eg, sepsis) relative to the pump speed setting.

Inflow Cannula and Outflow Graft. *Inflow Cannula.*—An appropriately positioned inflow cannula lies near or within the LV apex and is directed towards the MV, although some angulation towards the ventricular septum may be observed ([Figure 5](#)). Assessment of the relationship of the inflow cannula to the ventricular septum is generally performed by

Table 2 Continuous-flow LVAD postimplant complications and device dysfunction detected by echocardiography

Pericardial effusion

With or without cardiac tamponade including RV compression. *Tamponade*: respirophasic flow changes; poor RVOT SV.

LV failure secondary to partial LV unloading

(by serial exam comparison)

- a. 2D/3D: increasing LV size by linear or volume measurements; increased AV opening duration, increased left atrial volume.
- b. Doppler: increased mitral inflow peak E-wave diastolic velocity, increased E/A and E/e' ratio, decreased deceleration time of mitral E velocity, worsening functional MR, and elevated pulmonary artery systolic pressure.

RV failure

- a. 2D: increased RV size, decreased RV systolic function, high RAP (dilated IVC/leftward atrial septal shift), leftward deviation of ventricular septum.
- b. Doppler: increased TR severity, reduced RVOT SV, reduced LVAD inflow cannula and/or outflow-graft velocities (ie, <0.5 m/sec with severe failure); inflow-cannula high velocities if associated with a suction event. Note: a "too-high" LVAD pump speed may contribute to RV failure by increasing TR (septal shift) and/or by increasing RV preload.

Inadequate LV filling or excessive LV unloading

Small LV dimensions (typically <3 cm and/or marked deviation of interventricular septum towards LV). Note: May be due to RV failure and/or pump speed too high for loading conditions.

LVAD suction with induced ventricular ectopy

Underfilled LV and mechanical impact of inflow cannula with LV endocardium, typically septum, resolves with speed turndown.

LVAD-related continuous aortic insufficiency

Clinically significant—at least moderate and possibly severe—characterized by an AR proximal jet-to-LVOT height ratio >46%, or AR vena contracta ≥ 3 mm; increased LV size and relatively decreased RVOT SV despite normal/increased inflow cannula and/or outflow graft flows.

LVAD-related mitral regurgitation

- a. Primary: inflow cannula interference with mitral apparatus.
 - b. Secondary: MR-functional, related to partial LV unloading/persistent heart failure.
- Note: Elements of both a and b may be present.

Intracardiac thrombus

Including right and left atrial, LV apical, and aortic root thrombus

Inflow-cannula abnormality

- a. 2D/3D: small or crowded inflow zone with or without evidence of localized obstructive muscle trabeculation, adjacent MV apparatus or thrombus; malpositioned inflow cannula.
- b. *High-velocity* color or spectral Doppler at inflow orifice. Results from malposition, suction event/other inflow obstruction: aliased color-flow Doppler, CW Doppler velocity >1.5 m/s.
- c. *Low-velocity* inflow (markedly reduced peak systolic and nadir diastolic velocities) may indicate internal inflow-cannula thrombosis or more distal obstruction within the system. Doppler flow velocity profile may appear relatively "continuous" (decreased phasic /pulsatile pattern).

Outflow-graft abnormality

Typically due to obstruction/pump cessation.

- a. 2D/3D imaging: visible kink or thrombus (infrequently seen).
- b. Doppler: peak outflow-graft velocity ≥ 2 m/s* if near obstruction site; however, diminished or absent spectral Doppler signal if sample volume is remote from obstruction location, combined with lack of RVOT SV change and/or expected LV-dimension change with pump-speed changes.

Hypertensive emergency

New reduced/minimal AV opening relative to baseline exam at normal BP, especially if associated with new/worsened LV dilatation and worsening MR. Note: hypertension may follow an increase in pump speed.

Pump malfunction/pump arrest:

- a. Reduced inflow-cannula or outflow-graft flow velocities on color and spectral Doppler or, with pump arrest, shows diastolic flow reversal.
- b. Signs of worsening HF: including dilated LV, worsening MR, worsened TR, and/or increased TR velocity; attenuated speed-change responses: decrease or absence of expected changes in LV linear dimension, AV opening duration, and RVOT SV with increased or decreased pump speeds; for HVAD, loss of inflow-cannula Doppler artifact.

2D, Two-dimensional; 3D, three-dimensional; A, mitral valve late peak diastolic velocity; AR, aortic regurgitation; AV, aortic valve; BP, blood pressure; CW, continuous-wave; E, mitral valve early peak diastolic velocity; e', mitral annular velocity; HVAD, HeartWare ventricular assist device; IVC, inferior vena cava; LV, left ventricular; LVAD, left ventricular assist device; LVOT, left ventricular outflow tract; MR, mitral regurgitation; MV, mitral valve; RAP, right atrial pressure; RV, right ventricular; RVOT, right ventricular outflow tract; SV, stroke volume; TR, tricuspid regurgitation. Adopted and modified from Estep et al.⁶⁵

*Note: based on observational data. The "normal" outflow graft peak velocities are not well defined. Because the HVAD outflow graft diameter is smaller than that of the HM II device (see discussion in text). Therefore, the normal Doppler-derived HVAD outflow velocities may be somewhat higher on average than those observed for the HM II LVAD.

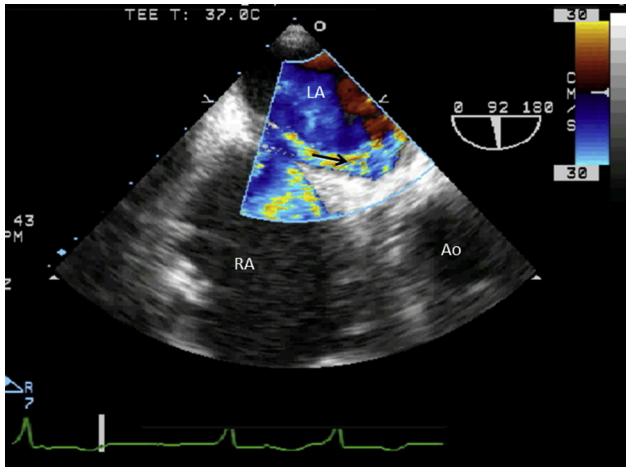


Figure 7 Perioperative TEE showing marked RA-to-LA shunting via an “unmasked” PFO, which became apparent immediately after LVAD activation. The PFO “tunnel”-defect shunt is readily apparent on color-flow Doppler (arrow) with a low Nyquist-limit setting of 30 cm/s. See also [Video 7](#).

using standard planar mid-esophageal LV views.³⁹ Additional simultaneous orthogonal planes and real-time 3D imaging may be used to better identify the terminal portion of the cannula within the LV cavity (Figures 4A,B and 5A). Although a certain degree of angulation may be unavoidable, an excessive degree of angulation may necessitate surgical revision, given an expected decrease in LV cavity size either acutely or later in the clinical course after initiation of MCS. The combination of a smaller LV cavity and an angulated cannula can result in direct contact between the inflow cannula and the septum, which, in turn, can cause ventricular arrhythmias and/or inflow-cannula flow obstruction, as previously discussed. Additionally, the inflow cannula may directly interfere with the native submitral apparatus, and this finding should be communicated to the surgeon. Color Doppler interrogation of a properly aligned HM-II inflow cannula should reveal low-velocity (typically ≤ 1.5 m/sec)⁴⁹ laminar, unidirectional flow from the ventricle to the inflow cannula, with a variable degree of uniform systolic augmentation and no regurgitation (Figure 5B).³⁹ In some cases, the normal inflow-cannula spectral Doppler flow signal may be “contaminated” by mitral inflow and/or AR (Figure 5C). Using both pulsed and CW spectral Doppler for interrogating the HM-II inflow-cannula flow is recommended, in order to screen for obstructive velocities (Figure 5C). Any HM-II inflow cannula turbulent color Doppler or significant peak systolic velocity variability suggests the presence of mechanical obstruction by the interventricular septum, LV muscular trabeculations, or submitral apparatus. The pericardial location of the HVAD impeller results in a prominent, characteristic color and a spectral Doppler artifact that generally precludes Doppler interrogation of the inflow cannula.^{49,50} The HVAD Doppler artifact occurs only when the inflow cannula appears within the imaging sector. Therefore, successful color and spectral Doppler interrogation of other cardiac structures is possible whenever the imaging plane excludes the HVAD inflow cannula (Figure 11). Consequently, HVAD inflow must be determined indirectly by correlating the inflow cannula anatomic imaging (ie, does the cannula appear unobstructed?) with downstream anatomic and hemodynamic parameters, as discussed in more detail below.

Outflow Graft.—After interrogation of the inflow cannula, attention should be directed towards the outflow graft. Whereas the proximal

outflow graft is not visible with TEE, the middle portion adjacent to the right side of the heart (Figure 12) and the distal outflow graft-to-aorta anastomosis can be visualized in the majority of patients. Flow from the outflow graft into the aorta can be visualized by color Doppler interrogation near the level of the right pulmonary artery (eg, great vessel, upper esophageal view [Figures 6 and 13]). Simultaneous orthogonal-plane or real-time 3D imaging may allow better characterization of the anastomosis site. Every effort should be made to perform spectral Doppler interrogation coaxially to the direction of flow. As with the inflow cannula described above, the spectral Doppler appearance should consist of low-velocity, laminar, unidirectional flow with a variable amount of systolic augmentation. However, outflow-graft-velocity benchmarks are not available. The peak systolic and nadir diastolic Doppler-derived velocities vary with pump speed in the same patient, and these speeds may also vary with the graft cross-sectional area of the particular device type. However, an outflow-graft peak systolic velocity of >2 m/s at any level (including the that of the aortic anastomosis) may be abnormal and warrant further investigation or monitoring.

Finally, it is important to note that sternal closure can change the orientation of either the inflow cannula or the outflow graft relative to their open chest positions. Accordingly, it is critical to reevaluate the inflow cannula orientation and flow characteristics and the outflow graft and/or outflow graft-to-aorta anastomosis flow immediately after sternal closure. This can be accomplished by TEE or TTE.

Pump Speed. Optimal pump speed selection is a complex topic. The early postimplantation recovery phase may be associated with significant fluctuations in LV preload and afterload. Therefore, the immediate postimplantation (operating room) pump speed that is associated with ‘normal’ LVAD function by the perioperative TEE parameters discussed above may or may not be appropriate later on. In addition (as discussed in more detail, below), selection of an “optimal” LVAD speed setting varies among implantation centers. Some centers select the speed that minimizes LVEDVs and/or the LVDD while allowing at least intermittent AV opening (assessed best by M-mode echocardiography at the AV level). Other centers maximize LV unloading, leaving the AV closed.

KEY POINTS

- Intracardiac air is a consequence of LVAD implantation, and TEE evaluation is useful for ascertaining the success of de-airing maneuvers.
- All images acquired after LVAD activation should be annotated with the device name and current pump speed.
- Postimplant perioperative TEE should include rapid assessment for possible unmasked PFO shunt, AV opening, the relative LV and RV sizes, degree of TR, ventricular septal position, inflow-cannula position, and flow velocities after initiation of LVAD support and after changes in the LVAD pump speed.
- A “suction event,” is a condition in which a segment of LV myocardium partially occludes the inflow cannula and reduces pump inflow. This complication is usually related to over-pumping of the left ventricle (producing a small “sucked down” LV cavity). Suction events can often be quickly corrected by lowering the pump speed.
- HM-II inflow cannula peak systolic flow velocities are typically <1.5 m/sec. Higher velocities suggest possible inflow-cannula obstruction.
- HVAD inflow-cannula velocities cannot be measured due to a characteristic Doppler artifact.
- TEE imaging can frequently show the anatomic contour and flow velocities of the distal outflow-graft region and the outflow-graft-to-aorta anastomosis.

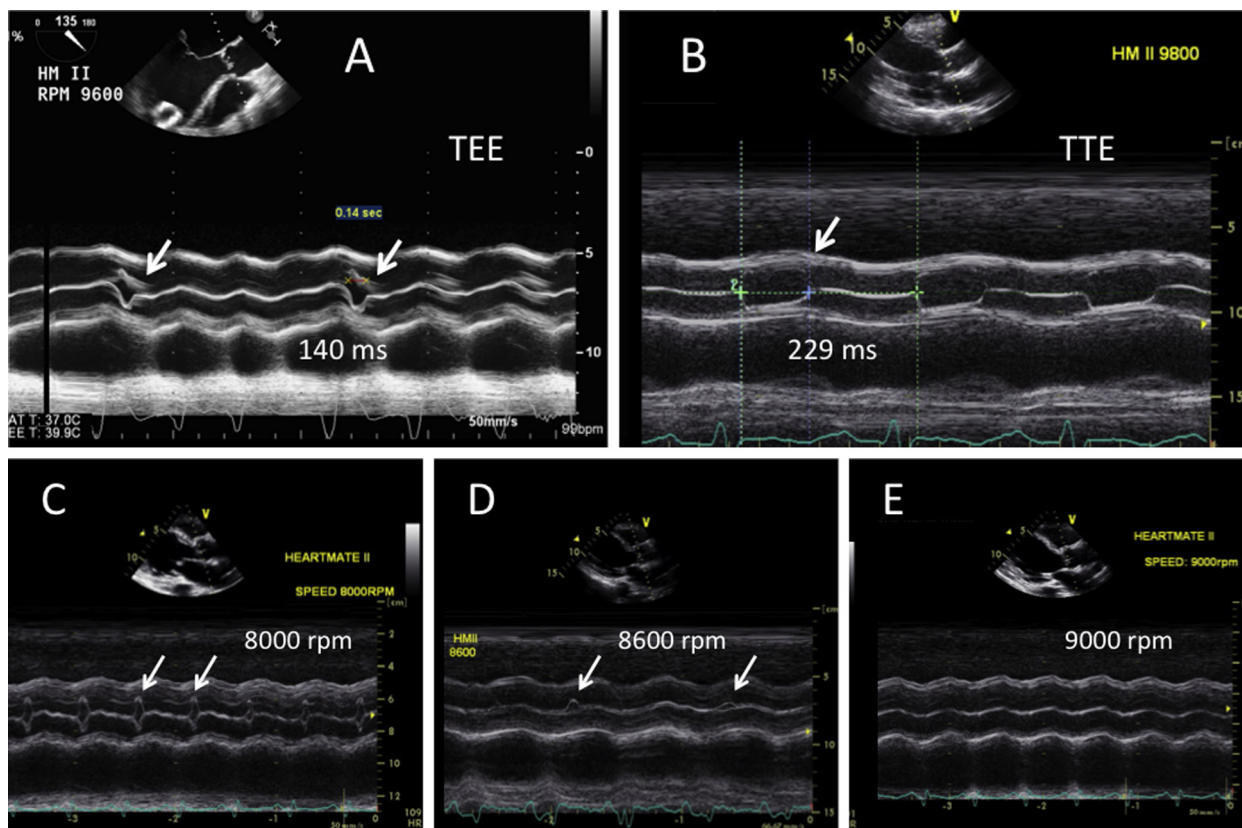


Figure 8 The duration of AV opening during LVAD support can be easily measured using M-mode during either TEE (**A**) or TTE (**B**). In view A, the AV “barely opens” intermittently (*arrows*); this may, in part, be related to an arrhythmia and suggests normal LVAD function at a pump speed of 9600 rpm. In view B, there is near-normal AV opening, with durations of >200 ms; this may be an abnormal finding at a high LVAD pump speed (9800 rpm). (**C–E**) The expected progressively reduced duration of AV opening in the same patient during a ramp (speed-change) echo exam at different HM-II pump speeds: In view C (8000 rpm), the AV “barely opens”; in view D (8600 rpm), the AV “opens intermittently” (*arrows*); in view E (9000 rpm), the AV “remains closed.”

- Outflow-graft velocities of >2 m/s at any level may be abnormal and warrant further consideration for possible obstruction, although benchmark data are lacking in this regard.

2. LVAD problem-focused echocardiography, with or without an LVAD speed-change protocol.
3. LVAD recovery echocardiography.

ROLE OF ECHOCARDIOGRAPHY (TTE OR TEE) AFTER LVAD IMPLANTATION

The significant variability in the clinical courses of individual patients after LVAD implantation precludes a “one-size-fits-all” approach to postimplantation echocardiography. Nevertheless, the authors believe that an overall framework can be recommended. In general, the starting point for any LVAD echocardiographic examination is a comprehensive “HF” TTE exam, which is performed at the pump’s baseline speed setting and includes LVAD-specific views and Doppler flow assessments in addition to all the elements of preoperative TTE. In some cases, outlined below, the exam also includes the systematic reacquisition of selected exam components at pump speeds above and/or below the baseline speed. The exact protocol for changing pump speeds varies, depending on the indication for examination. There are three subcategories of LVAD echo protocol indications that appear to reflect real-world clinical management:

1. LVAD surveillance echocardiography, with or without LVAD optimization echocardiography.

LVAD Surveillance Echocardiography

LVAD surveillance echocardiography is performed at the pump’s baseline speed setting and includes LVAD-specific views and Doppler flow assessments in addition to all the elements of a standard HF TTE exam. Addition of an LVAD optimization protocol, may involve further limited imaging at pump speeds higher and/or lower than the baseline speed to optimize LVAD and native heart function.

The authors recommend that patients with an uncomplicated post-operative course (eg, absence of HF symptoms, successful weaning from IV pharmacologic inotropic and vasopressor agents within 14 days, absence of LVAD controller alarms, and lack of serologic evidence of hemolysis or infection) undergo follow-up surveillance TTE at prespecified intervals. Periodic **LVAD surveillance echo exams** are recommended, to establish patient-specific “baseline” parameters for both LVAD and native heart function. An LVAD surveillance echo exam should be considered at approximately 2 weeks after device implantation or before index hospitalization discharge (whichever occurs first), followed by consideration of surveillance TTE at 1, 3, 6, and 12 months post implantation and every 6 to 12 months thereafter. [Figure 14](#) summarizes a sample schedule

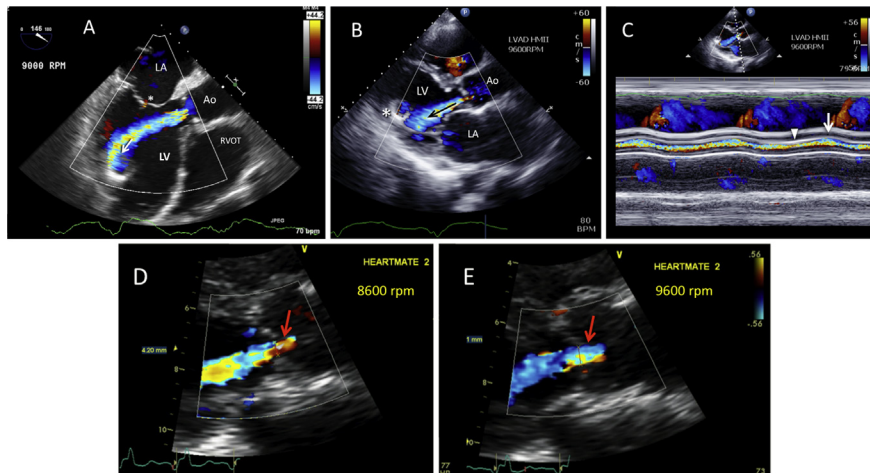


Figure 9 Assessment of AR. **(A)** TEE shows at least moderate—and possibly severe—continuous AR during LVAD support. The AR VC is clearly >3 mm, and the jet width/LVOT width is clearly $>46\%$. Color-flow Doppler reveals inflow-cannula systolic entrainment of the AR jet (*arrow*). A closed MV and trace MR (*) are indicative of marked systolic AR. *RVOT*, right ventricular outflow tract. See also [Video 8](#). **(B, C)** During LVAD support, at least moderate continuous AR (*arrow*) is observed in the transthoracic parasternal long-axis view with color Doppler **(B)** and color M-mode imaging **(C)**; the inflow cannula is denoted by an asterisk. In view C, note the variance in the early systolic (*arrowhead*) versus late systolic (*arrow*) AR VC width, as shown by M-mode. This finding is not consistent among different patients; it is likely influenced by several variables and by the fact that the AV cusps can exhibit augmented systolic opening, despite AR, at speeds close to (but below) the AV “opening speed.” See also [Video 9](#). **(D–E)** The AR VC width may increase at higher pump speeds in the same patient, as seen here. This may partially be due to an increased systemic arterial pressure at higher pump speeds, which presumably increases the AR volume. At both speeds, the VC is >3 mm, indicating at least moderate—and possibly severe—AR. The VC width is 4.2 mm at 8600 rpm in view D and is 5.7 cm at 9600 rpm in view E (HM-II LVAD). **(F)** “Continuous” holosystolic and hodiastolic AR, as detected by continuous-wave Doppler (TTE apical 5-chamber view). **(G)** Continuous-wave Doppler (TTE apical 5-chamber view) reveals nearly continuous AR, which significantly extends into the electrical and mechanical systolic period with a brief period of AV systolic forward flow (*arrows*). **(H)** Color M-mode shows minimal AV opening, with a brief duration of low-velocity systolic forward flow (*arrows*). **(I)** TTE parasternal long-axis view of an AR jet on color-flow Doppler imaging (*arrow*). **(J)** The AV opens widely, with forward flow that interrupts AR. However, the AR period extends into the electrical and mechanical systolic period (*arrows*) during HVAD pumping at 2600 rpm.

for timing postimplantation surveillance TTE. Comparison of serial surveillance-exam results to each other (for an individual patient) or to population-based benchmarks (see [Appendix D](#)) can also help the examiner understand a patient’s response to LVAD therapy over time. Moreover, surveillance data may allow early diagnosis of occult native heart abnormalities (eg, development of LVAD-related AR) or other device-related problems, including a drift from previously optimal device speed settings. When surveillance TTE is coordinated with the patient’s routine LVAD clinic visits, HF specialists can integrate the information obtained into their clinical assessments and care plans. A putative benefit of routine LVAD surveillance echocardiograms (with optimization protocols when indicated) is improved patient outcomes, including early detection and treatment of complications and reduced hospitalizations for recurrent HF.

KEY POINTS

- Patients with an uncomplicated postoperative course should undergo LVAD surveillance echocardiography at certain predetermined intervals after LVAD implantation to assess the patients’ response to MCS therapy and to screen for the development of subclinical complications.
- When possible, LVAD surveillance echocardiography should be coordinated with routine LVAD-clinic visits.

Clinical Data-Acquisition Standards and Sonographer Reproducibility (see [Table 3](#)). Before initiating any LVAD echo exam, sonographers should always annotate the LVAD type and base-

line LVAD speeds in rotations per minute (rpm) on the imaging screen in addition to the standard patient demographic data. If the device speed is changed, this should be reannotated during the exam. The device type and speed information should also be routinely incorporated into reporting templates.

Blood Pressure. The patient’s BP, which reflects peripheral vascular resistance, is an important parameter that greatly influences ventricular unloading and the observed echocardiographic findings. Therefore, the BP should be recorded just before the exam and immediately afterward if pump speed changes were made. Patients with CF-LVADs have a reduced and narrowed pulse pressure, and a palpable pulse may be absent. Therefore, cuff-based BP assessment may be difficult or impossible to perform. In the intensive care unit, the BP may be obtained from invasive arterial monitoring devices. In other settings in which no pulse is present, the use of a BP cuff along with handheld audible Doppler evaluation of the brachial or radial artery may be required.⁵¹ Note that the arterial Doppler-derived BP reading lies between the systolic pressure and the mean arterial BP.⁵² For practical purposes, if the patient has a pulse (ie, the AV is opening), the Doppler-derived BP is the same as the systolic BP. If the patient does not have a pulse (ie, the AV is not opening), the Doppler BP is considered to be the mean arterial BP. A current BP measurement is necessary for accurate echo interpretation and for safety reasons during “speed change” protocols, particularly when changing to higher speed settings. Susceptible patients may develop clinically significant hypertension in response to increased LVAD flow, and a mean arterial pressure of <85 mmHg is recommended.⁵³

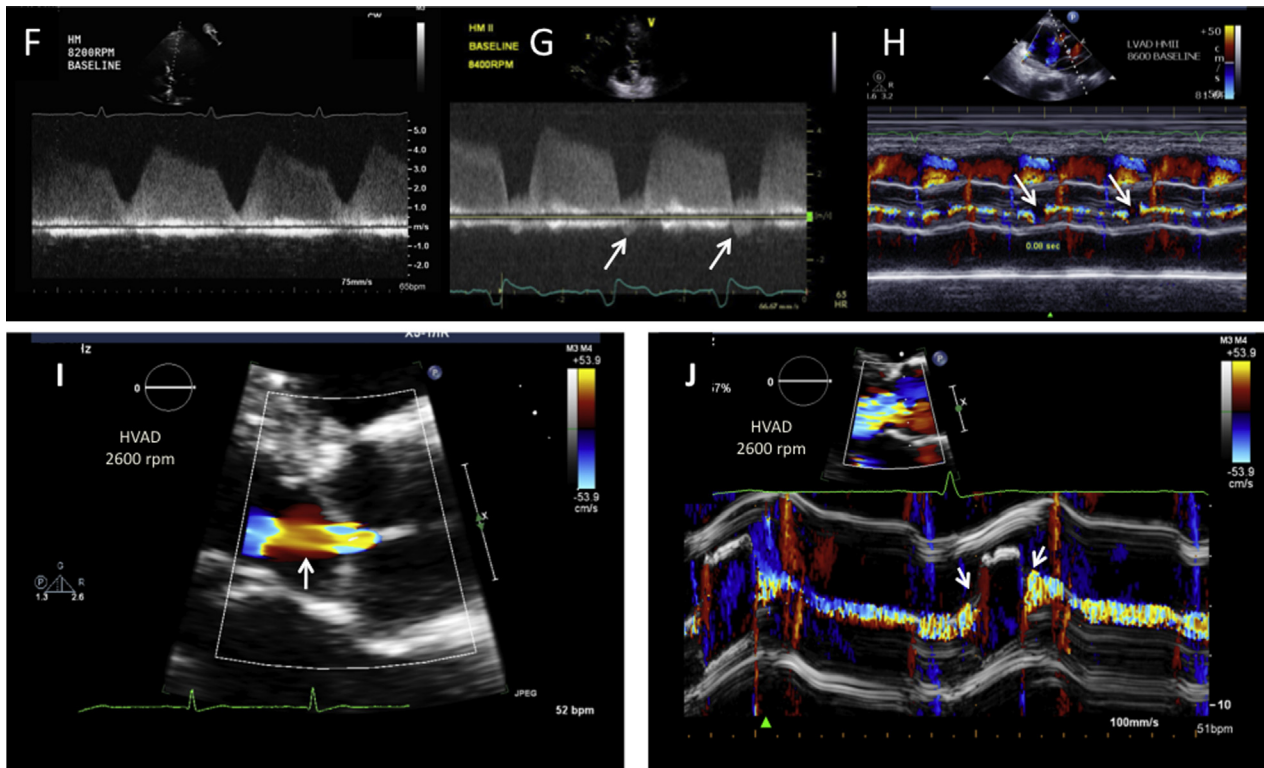


Figure 9 (continued).

Hypotension is generally defined as a mean arterial pressure of <60 mmHg and may be associated with traditional symptoms and/or signs reflective of hypoperfusion. With CF-LVADs, one of the challenges is that a sonographer (or some other trained and available individual) needs to be facile at obtaining an arterial Doppler-derived BP reading. To facilitate the care of CF-LVAD recipients, there may be a need for improved BP monitoring techniques.⁵⁴

KEY POINTS

- Although BP readings can be challenging to obtain in LVAD patients, this variable is important, as it significantly influences observed echo findings and their interpretation.
- In the absence of a palpable pulse, BP measurement may require audible Doppler interrogation by an appropriately trained individual before the echo exam.
- Susceptible patients can experience marked hypertension after the LVAD pump speed is increased. Therefore, the BP measurement should be repeated after a significant pump-speed increase, particularly if the BP is elevated at the baseline pump speed.
- A mean arterial BP of <85 mm Hg is recommended.
- Hypotension is generally defined as a mean arterial pressure <60 mmHg. It may be associated with traditional symptoms and/or signs of hypoperfusion.

LV Size and Systolic Function. Methods for determining LV size and systolic function by using linear and volumetric approaches in non-LVAD patients have been described by Lang and colleagues.¹⁷

LV Size.—As mentioned above, the LVIDd from the 2D parasternal long-axis image is considered the most *reproducible* measure of LV size

after LVAD implantation (Figure 15A). In the presence of a normally functioning CF-LVAD, severely depressed native LV function, and altered MV opening, determination of end-diastole may be difficult. In this scenario, correlating the images to the electrocardiographic signal can be helpful. Additionally, strong consideration should be given to the use of a microbubble contrast agent when endocardial definition is insufficient for accurate LVIDd measurement.²⁰ Previous data from HM-II outpatients in stable condition suggest that at least a 15% reduction in the LVIDd compared to preimplant values can be expected 3 months after implantation.^{55,56} Care must be taken to correlate LV end-systolic versus end-diastolic diameters with the electrocardiographic signal. The LVIDd may be paradoxically smaller than the LVIDs, and this is an important finding, as it is associated with excessive LVAD unloading and/or severe RV dysfunction. Although LV volumes, as determined by Simpson's biplane or single-plane method (Figure 16), reflect the LV size more accurately than do linear measurements, the LV size by volume assessment may be technically challenging to obtain after LVAD implantation because of apical shadowing/dropout associated with the inflow cannula. This is one reason why postimplantation LV volumes assessed by echocardiography are smaller than those assessed by CCT.⁵⁷ A reasonable LV diastolic volume assessment is possible in many ambulatory LVAD patients, and this metric can be incorporated into the surveillance exam, particularly at the baseline pump speed setting. However, LVIDd measurement, being more expeditiously acquired and reproducible, is practical for tracking the relative LV size over time at a baseline pump speed (eg, Figure 15A vs. 15B) and in the context of a speed-change exam (see below) for quick problem solving. That the serial LVIDd measurement (combined with the degree of AV opening) can be used as a surrogate marker for the degree of LV unloading in CF-LVAD patients seems intuitive and is supported by limited available literature, which is derived primarily from HM-II

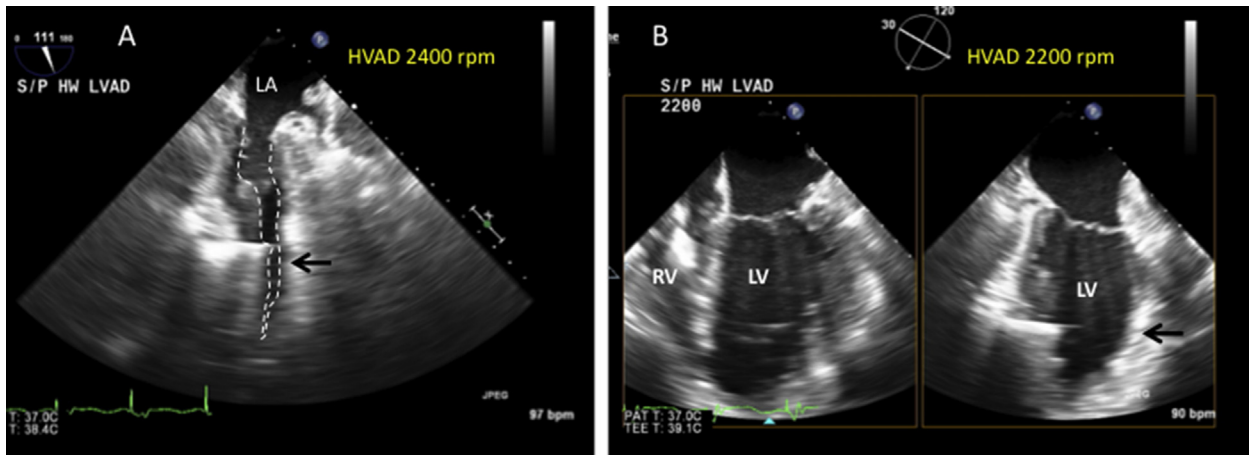


Figure 10 Suction event diagnosed with perioperative/postoperative TEE soon after HVAD activation. A 2400-rpm pump speed was initially satisfactory until the patient developed sudden hypotension and LVAD flow cessation. **(A)** Relook imaging (mid-esophageal 2-chamber view) showed LV cavity obliteration (*dotted line*) and inflow-cannula obstruction by the anterior LV endocardium (*arrow*). See also [Video 10](#). **(B)** Restoration of acceptable LV size and normalized LVAD function seconds after pump-speed reduction to 2200 rpm. *Note:* In this case, the suction event was precipitated by intravascular volume depletion and a low afterload following weaning from CPB; the event was easily corrected by reducing the pump speed, administering IV fluids, and adjusting vasopressor infusions. In this example, the RV remained small and not dilated. However, CPB suction events can result from a low LV preload related to acute RV failure, with associated RV dilatation, TR, and a leftward ventricular septal shift that may persist despite pump-speed reduction (see the TTE example below). Depending on the degree of underlying RV dysfunction, perioperative suction events or RV failure may or may not be transient and responsive to medical management. See also [Video 11](#).

studies. However, robust outcomes data are limited, and applicability to HVAD patients, for whom there is less evidence, has not been demonstrated at this time.⁵⁸

LV Systolic Function.—Accurate determination of LV volumes is challenging after device implantation. So, too, is accurate and meaningful determination of overall LV systolic function, as based on the LVEF. Limitations for LVEF measurements are both technical with regards to imaging quality (endocardial border detection) and physiologic. The LV endocardium may be difficult to visualize because of apical foreshortening, apical shadowing from the device or acoustic dropout (signal attenuation). LVAD-related physiologic challenges include enhanced interventricular dependence and discordant septal and inferolateral wall motion, which may vary considerably in the same patient at different pump speeds. If the LV endocardium, including the apex, can be adequately visualized, with or without a microbubble contrast agent, the preferred method for calculating the LVEF is the biplane method of disks ([Figure 16](#)), modified Simpson rule.¹⁷ Although other parameters for LV systolic function may be considered, the LVEF is an important surrogate for showing possible LV worsening or recovery. Therefore, surveillance and recovery LVAD exam reports should include an LVEF assessment, even if only a qualitative assessment is possible. However, LVAD support markedly reduces LV preload, an important determinate of LVEF. Therefore, the value of LVEF for determining systolic function during LVAD support must be taken into consideration during clinical decision-making.

Other methods: In patients with suboptimal apical but adequate parasternal views, the following methods for measuring LV systolic function may be considered, although their accuracy has not been validated in LVAD patients.

1. The LV fractional area change (FAC) method at the mid-papillary muscle level on 2D short-axis views: $FAC (\%) = [(end-diastolic\ area - end-systolic\ area) / (end-diastolic\ area)]$.⁵⁹
2. The Quinones method for determining the LVEF,⁶⁰ with the assumption of an akinetic apex given the presence of the apical inflow cannula.

3. The LV fractional shortening (%) method: $FS = [(LVIDd - LVIDs) / (LVIDd)]$, where FS = fractional shortening and LVIDs = the LV internal dimension at end-systole,¹⁷ which has been applied in LVAD patients.^{57,61}

The linear and volume measurements of systolic function noted above represent possible methods for tracking the course of individual patients, serving as their own controls, over time. However, routine use of methods 1 to 3, above may not be feasible or recommended for many LVAD patients because of segmental wall-motion abnormalities, exaggerated paradoxical septal motion, ventricular dys-synergy and/or ventricular septal shift, the extent of which could change at varying pump speeds in the same patient. Note that methods of calculating the LVEF based on the LV stroke volume are not recommended, because many LVAD patients have beat-to-beat variations in this parameter.⁴⁹ Previous data suggest that the vast majority of outpatient HM-II recipients in stable condition have persistent moderately to severely depressed LV systolic function during the first 6 months after device implantation.^{55,56}

KEY POINTS

- After CF-LVAD activation, the LVIDd may be the most reproducible measure of LV unloading that can be tracked over time and/or at different pump speeds.
- The LVEDV is a more accurate representation of LV size than is the LVIDd.
- After LVAD implantation, measurement of LV volumes and the LVEF can be technically challenging. When the LVEF needs to be obtained (particularly to assess for LV recovery), Simpson's biplane method of disks is recommended for use when possible.

LV Diastolic Function. It is assumed that LVAD patients have markedly abnormal baseline diastolic function. Although the standard LV diastolic function parameters⁶² can be measured and included in the report, there is a paucity of data validating their clinical usefulness in the setting of LVAD support. The use of certain diastolic parameters

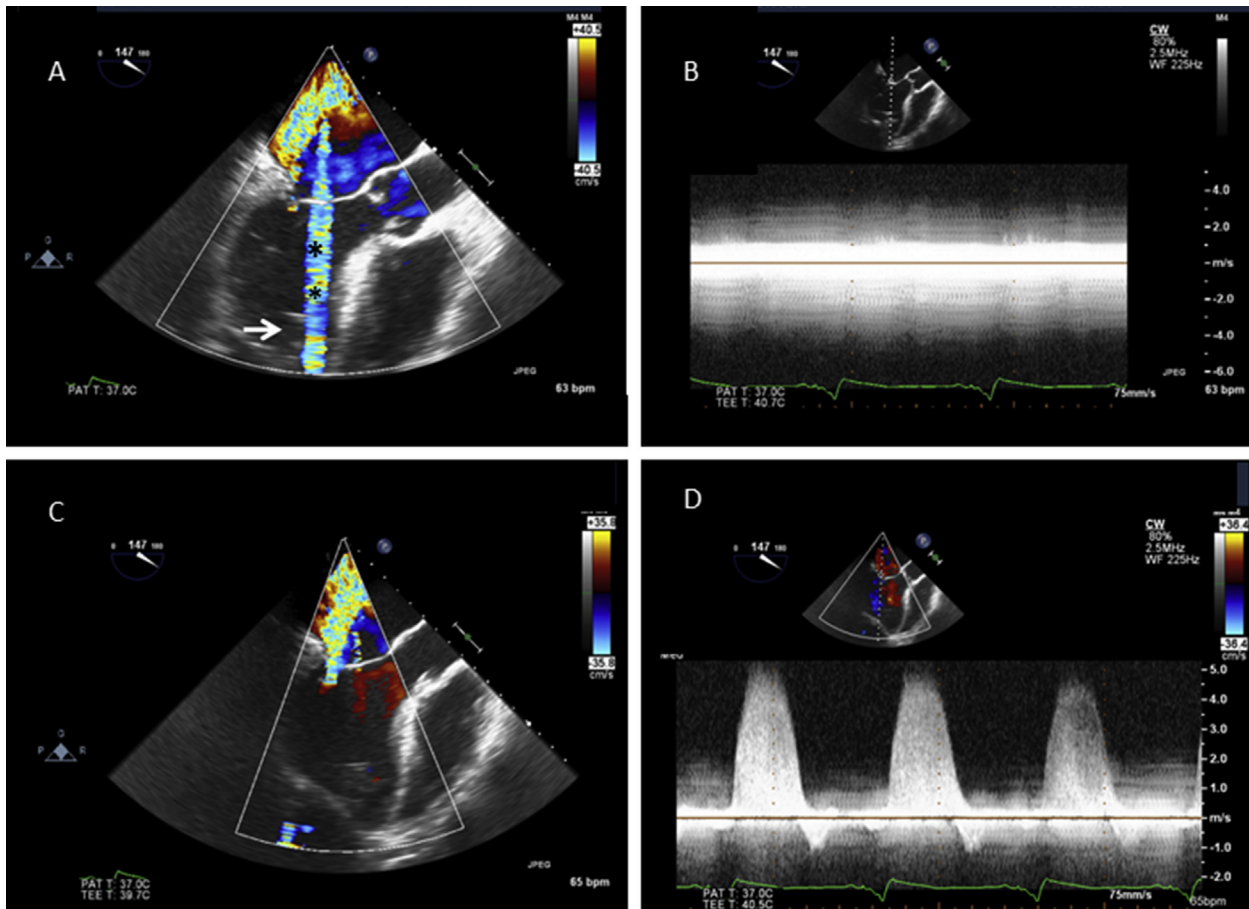


Figure 11 An HVAD inflow-cannula Doppler exam is typically not possible due to the characteristic color artifacts (**A**) (***) and spectral Doppler artifacts (**B**). See also [Video 12](#). When the inflow cannula is excluded from the 2D imaging sector (**C**), the artifacts diminish, and other aspects of the Doppler exam can be performed. (**D**) Successful continuous-wave Doppler examination of MR in the same patient after slight rotation of the imaging sector away from the inflow cannula. Because the 2D image (view A: *arrow*) suggests that the inflow cannula is directed towards the ventricular septum, normal inflow-cannula flow must be confirmed by other methods, whether TEE or TTE. See also [Video 13](#).

could be helpful, particularly when correlated with symptoms in individual patients, and at the discretion of the interpreter since they may reflect changes in the degree of LV unloading when compared to a prior study's data or at different pump speeds during the same exam. Previous data suggest that the mitral E velocity (cm/s), left atrial volume (mL), pulmonary vascular resistance (Wood units), and pulmonary artery systolic pressure (mmHg) are significantly reduced and that the mitral deceleration time (ms) is significantly prolonged in outpatients whose condition is stable 3 to 6 months after HM-II implantation.^{55,56} How these parameters should be integrated into postimplantation clinical management is currently undefined, as is their prognostic value for patient outcomes. For a clinical LVAD echo reporting purposes, a practical approach at this time may be to use the following (or a similar) statement: "Interpretation of the degree of LV diastolic dysfunction (presumed abnormal) is not provided because of continuous flow LVAD support."

KEY POINTS

- It may be assumed that LVAD patients have markedly abnormal baseline diastolic function.

- How LV diastolic parameters measured after LVAD implantation should be integrated into the echocardiography interpretation and clinical management is currently undefined, as is their prognostic value for patient outcomes.

RV Size and Systolic Function. Many of the standard measures of RV size and systolic function,²² including linear dimensions, RV FAC, TAPSE, and right-sided cardiac output, can feasibly be measured in LVAD patients.^{56,63,64} However, recent data suggest that the correlation of TAPSE with overall RV systolic function may be weaker after cardiothoracic surgery and, therefore, this variable may have less clinical utility than the other measures.⁶⁵ Current data regarding the expected response of RV systolic function after LVAD implantation are conflicting: one study showed a significant improvement in RV FAC at 3 months,⁵⁵ but another study did not show a significant difference in this parameter at either 1 month or 6 months.⁵⁶

Valvular Assessment. Aortic Valve.—Evaluating and reporting the degree of AV opening (if any) is important because it is affected by a number of other parameters, including LVAD speed, native LV function, volume status, and peripheral vascular resistance. In addition, whether or not the AV opens may have clinical implications. Whereas recent guidelines recommend that the LVAD speed be set low enough to allow

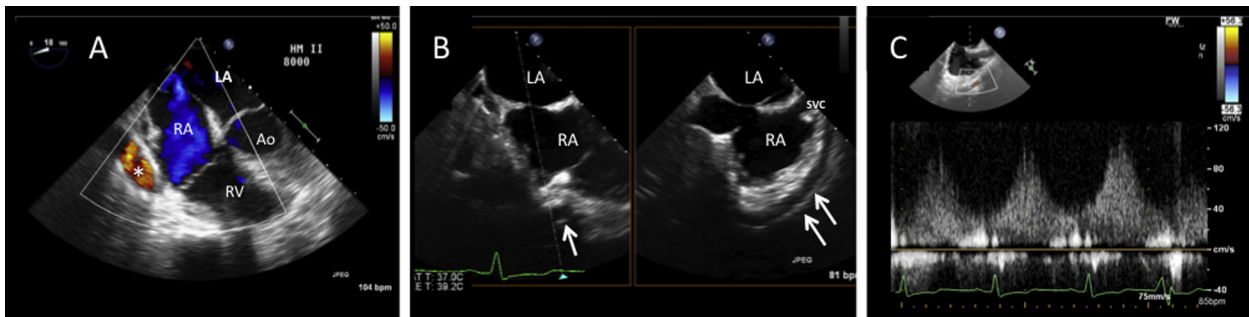


Figure 12 LVAD outflow graft, as assessed by TEE. **(A,B)** In a modified mid-esophageal 4-chamber view **(A)**, the outflow graft (*) is frequently seen in near short-axis orientation. See also [Video 14](#). **(B)** Shows the utility of simultaneous orthogonal-plane imaging, which, in this case, a short axis image of the outflow graft (*single arrow*) is used as a reference image to reveal a long segment of the graft overlying the RA in a standard bicaval view (*double arrows*). See also [Video 15](#). **(C)** Successful pulsed Doppler interrogation of the outflow graft (this is not always possible in practice). See also [Video 16](#).

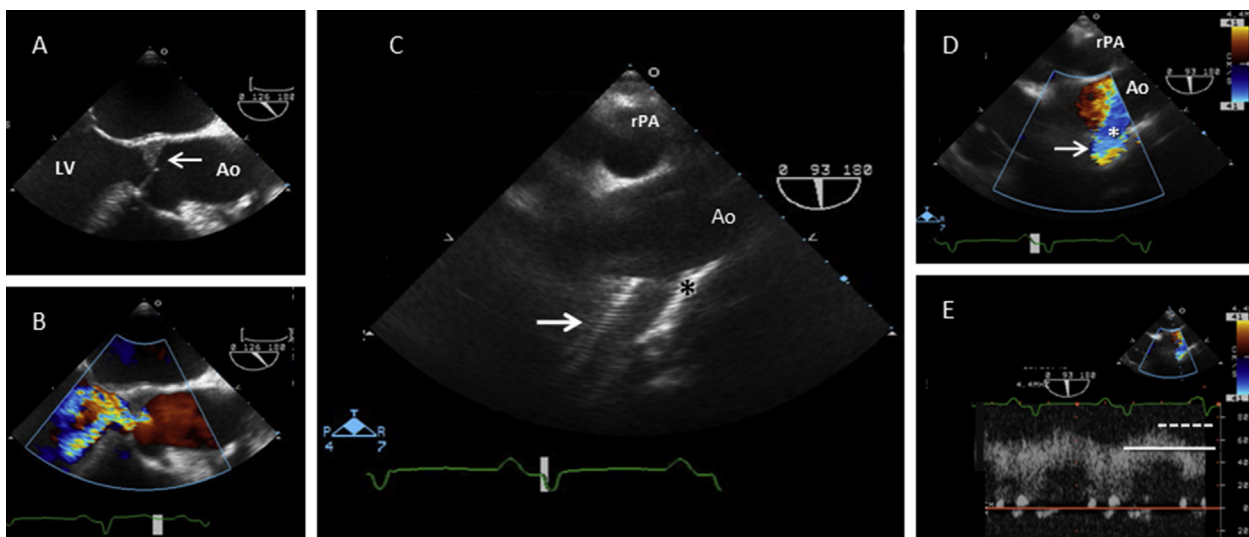


Figure 13 TEE characteristics of severe AR due to aortic cusp fusion associated with longstanding LVAD support. **(A)** Mural thrombus within the AV noncoronary cusp (*arrow*). See also [Video 17](#). **(B)** Severe AR, as detected by color-flow Doppler. See also [Video 18](#). **(C)** Using the right pulmonary artery (rPA) as an acoustic window, an upper esophageal long-axis view of the ascending aorta (Ao) shows the LVAD outflow graft (*arrow*) and its ascending aortic anastomosis site (*). **(D)** Color-flow Doppler evaluation of the outflow-graft-aorta anastomosis. See also [Video 19](#). **(E)** Pulsed Doppler assessment of the outflow anastomosis reveals a laminar signal with high flow characterized by nearly equal systolic (*dotted line*) and diastolic (*solid line*) velocities (*arrow*), consistent with severe AR.

at least intermittent AV opening,⁴ such opening may not occur at *any* LVAD speed in patients with extremely poor native LV function. The frequency of AV opening is most accurately assessed by recording multiple (five to six) cardiac cycles at a slow M-mode sweep speed (eg, 25–50 mm/s) ([Figure 8D,E](#)); the valve should be characterized as either opening with every cardiac cycle, opening intermittently, or remaining closed.^{49,66} Many HF teams also request that the duration of AV opening (ms) be measured from the same M-mode acquisitions. This parameter may vary from beat to beat, so it is best to measure several beats and report an average value. When the AV-opening duration is relatively constant, a faster sweep speed (eg, 75–100 mm/s) may be appropriate ([Figure 8A,B](#)). An important potential pitfall of using M-mode to assess the presence and duration of aortic cusp separation is illustrated in [Figure 17](#). The AV semilunar cusp conformation, combined with cardiac translational motion or slightly off-axis imaging, can create the false appearance of aortic cusp separation, even when the cusps are not separating. Careful attention and the additional use of color M-mode may be useful in difficult cases to avoid M-mode “pseudo AV opening” or an exaggerated AV-opening duration. However, an addi-

tional interesting observation is that in some cases of “minimal” AV opening, the duration of AV cusp separation and duration of forward systolic flow are not always the same, and color M-mode can help to document this finding ([Figure 9G,H](#)). In patients whose AV remains closed, it is important to evaluate for aortic root thrombus, which may be transient or associated with commissural fusion. Continuously closed aortic cusps have been associated with the development of aortic root thrombosis and LVAD-associated AR, as discussed below.⁶⁷ Fusion of the aortic cusps, either surgical or secondary to chronic aortic cusp closure, can be recognized on speed-change echocardiograms (discussed below).

New-onset (“de novo”) AR occurs in approximately 25% to 33% of patients 12 months after LVAD implantation^{68,69} and is a key finding, given its known adverse effects on LVAD performance, morbidity, and mortality.^{70–72} Several studies suggest that persistent AV closure is a risk factor for de novo AR after LVAD implantation, even without the presence of aortic root thrombus ([Figure 18](#)).^{68,73,74} For the reasons noted above in the postimplant TEE section, standard methods for quantifying AR³² may be challenging to use after

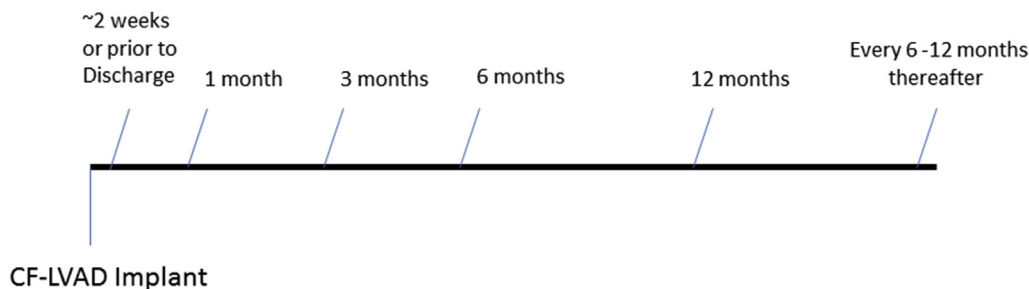


Figure 14 Sample schedule for initial and follow-up surveillance echocardiography of patients with no evidence of device malfunction.

LVAD implantation. In the absence of definitive cutoff criteria to define mild, moderate, and severe AR after LVAD implantation, one should perform an aggregate assessment based on duration (predominantly diastolic vs. continuous), AR jet VC width, jet height relative to the LVOT, comparative LVAD and native circuit flow measures and LV chamber size. Additionally, significant AR noted on LVAD surveillance echocardiography may be further evaluated with device controller data and the cardiac response during LVAD problem-focused echocardiography with speed changes, as described below.

KEY POINTS

- Recording multiple cardiac cycles with color M-mode at a sweep speed of 25-50 mm/s is recommended to accurately assess the frequency and duration of AV opening.
- Persistent AV closure can be associated with aortic root thrombus and de novo AR.
- If aortic root thrombus is suspected, a decrease in the LVAD pump speed should be avoided, as it could result in sudden AV opening (eg, during a planned speed-change exam).
- After LVAD implantation, the presence of AR is not uncommon. Assessment of severity is partly based on careful color Doppler analysis in the parasternal long-axis view.

Mitral Valve.—As noted above, LV unloading generally leads to reduced MV annular dilatation, improved leaflet coaptation, and, ultimately, reduced MR severity. Persistence of significant MR after initiation of LVAD support may indicate inadequate LV unloading or inflow cannula malposition and interference with the submitral apparatus. If MR is present, it can be quantified by using standard methods.³² Incidental post-LVAD MR may also represent LVAD malfunction and should be discussed with the clinical team.

Tricuspid and Pulmonary Valves.—Like MR, moderate or greater TR is an important finding on LVAD surveillance echocardiography, as this condition may be associated with insufficient LV unloading (functional TR), excessive LV unloading with a leftward shift of the interventricular septum (eg, a suction event), elevated systolic pulmonary pressures, and/or intrinsic RV systolic dysfunction. Distinguishing between these etiologies by utilizing echocardiographic parameters is discussed in further detail below. Regardless of the etiology, TR after LVAD implantation can generally be assessed with standard methods.³² Furthermore, the native pulmonary valve typically remains functionally normal after LVAD implantation and can be interrogated by using standard methods when significant stenosis or regurgitation is suspected.^{32,33} As noted in the foregoing discussion of perioperative TEE, the presence of significant preexisting or acquired PR may have implications with regards to RV function and/or the ability to perform RVAD implantation if needed.

Interventricular Septal Position. The end-diastolic interventricular septal position, which is dependent on the interventricular pressure gradient, should be routinely reported as *neutral, leftward-shifted, or rightward-shifted*. A leftward shift can be due to elevated RV end-diastolic pressures, reduced LV preload, or LV over-decompression resulting from excessive LVAD speed; differentiation of these etiologies is further discussed below. A rightward shift is generally due to elevated LV end-diastolic pressures resulting from an inadequate LVAD speed setting, pump dysfunction, severe AR, or an increased LV afterload.

Inflow-Cannula and Outflow-Graft Interrogation. *Inflow Cannula.*—Usually, the apically inserted inflow cannula can be adequately imaged in standard or modified 2D parasternal and apical TTE views. The sonographer's objective is to reveal the inflow cannula's location and orientation in relation to the interventricular septum and other LV structures. The inflow cannula can often be visualized with 3D echo techniques, and this approach may be used as a complementary imaging method by examiners experienced in 3D imaging. As noted above in the section on perioperative TEE, color Doppler interrogation of a properly aligned inflow cannula should reveal laminar, unidirectional flow from the ventricle to the inflow cannula, with no evidence of turbulence or regurgitation.³⁹ Pulsed and CW spectral Doppler interrogation may require "off-axis" modification of a standard parasternal, apical, or short-axis TTE view to achieve true coaxial alignment between the sampling beam and inflow-cannula flow; such interrogation should additionally reveal the flow to have a low peak velocity (<1.5 m/s). Due to native LV contractility, cannula flow generally remains pulsatile to some degree even when the AV does not open.^{49,55} Recording both the peak systolic and nadir diastolic velocities over at least three to four cardiac cycles is recommended (Figures 5 and 19).

The inflow cannula should be routinely interrogated with CW spectral Doppler at the baseline pump speed and particularly during the course of speed-change exams (discussed, below) to screen for inflow obstruction. Note that in many cases, a normal inflow-cannula spectral Doppler flow-velocity profile may be contaminated by low-velocity diastolic AR or mitral inflow (Figure 20). Moreover, in the setting of TEE evaluation of the inflow cannula, the CW Doppler signal can be contaminated by MR (Figure 5C) as well. The HVAD inflow-cannula flow velocities typically cannot be evaluated by using either color or spectral Doppler due to a characteristic Doppler artifact (Figure 21) related to the inflow cannula's direct connection to the adjacent impeller housing.

Outflow Graft.—In contrast to inflow-cannula imaging, visualizing the outflow graft requires the utilization of atypical echocardiographic windows. The terminal portion of the outflow conduit and its

Table 3 Sonographer checklist/ordering worksheet: LVAD-specific demographic data, image acquisition, and safety considerations particularly relating to “speed-change” echo exams (optimization, problem-solving/ramp studies)

√	Sonographer Checklist / Ordering Worksheet
	Study Type being ordered
	<ul style="list-style-type: none"> • Surveillance, initial (+/– optimization, pre/discharge) • Surveillance, post-discharge (+/– optimization, number months post: 1, 3, 6, 12, 18, etc.) • Problem-solving at baseline speed only • Problem-solving at baseline + other speed settings • Recovery
	Ordering/responsible physician identified
	Implant date documented
	Symptoms noted (if applicable)
	Device alarms: if present, type of alarm identified
	Other key clinical history/information related to indication noted
	Anticoagulation therapy adequate if low pump speeds tested
	LVAD name noted on worksheet and annotated on screen
	LVAD speeds (baseline and changes) noted on worksheet and annotated on screen
	Blood pressure (cuff or Doppler) noted on worksheet and annotated on screen (<i>obtained by designated trained individual at time of exam</i>)
	Designated person to change pump speed available
	Supervision: appropriate staff to perform speed changes; safety endpoint recognition (eg, low flow, suction event, hypo/hypertension)
	Aortic Root Thrombus detection: reason not to proceed (lowering speed could open AV)
	Endpoints for speed-change exams
	<ul style="list-style-type: none"> • Protocol completion • Hypotension • Hypertension • New symptoms • Device alarm • Signs of a suction event <ul style="list-style-type: none"> ○ Decrease in LV size (typically <3 cm) ○ Interventricular septum shifting leftward ○ Flow impeded into inlet cannula ○ Worsening TR due to septal shifting and/or RV enlargement • Signs of low cardiac output • Cannula flow reversal (at low pump speeds)

AR, Aortic regurgitation; AV, aortic valve; LV, left ventricular; LVAD, left ventricular assist device; TR, tricuspid regurgitation.

anastomosis to the aorta can generally be visualized from a high left parasternal long-axis view (Figures 22 and 23). The mid-portion of the outflow graft is best visualized from a right parasternal view while the patient is in a right lateral decubitus position. Color Doppler and spectral Doppler interrogations are usually possible from these views; and, as with the inflow cannula, recording both the peak systolic and nadir diastolic velocities over at least three to five cardiac cycles is recommended (Figure 24), depending upon the uniformity of the spectral Doppler signal. Note that the outflow-graft flow-velocity profile will appear either above or below the baseline in the spectral Doppler display, depending upon the sonographer’s positioning of the sample volume direction (caudad vs. cephalad) within the graft. There is no standard recommendation for a positive-versus-negative outflow graft display other than to provide the most coaxial alignment and to ensure that the flow direction (caudad vs. cephalad) is apparent. In some patients, the outflow graft may be visualized in sub-costal and/or sternal notch views, depending upon the body habitus. At similar flow rates, normal flow velocities within the HM-II outflow graft (16-mm diameter) are somewhat lower than those within the

smaller-caliber HVAD outflow graft (10-mm diameter). Otherwise, phasic holosystolic and holodiastolic laminar flow-velocity patterns should be similar between the two devices. The outflow-graft pulsed Doppler velocity-time integral (VTI) combined with the expected or measured outflow-graft area may be used to directly measure LVAD flow (see Figure 22 and the discussion below).

KEY POINTS

- When 2D imaging is inconclusive, 3D echocardiography can help delineate the relationship of the inflow cannula to the interventricular septum and other LV structures.
- In patients with an HM-II LVAD, peak systolic and nadir diastolic inflow-cannula and outflow-graft velocities may be derived from coaxially-aligned spectral Doppler.
- HM-II inflow-cannula peak systolic flow velocities are typically <1.5 m/sec. Higher velocities suggest possible inflow-cannula obstruction.
- HVAD: inflow-cannula velocities cannot be accurately measured due to a characteristic Doppler artifact.

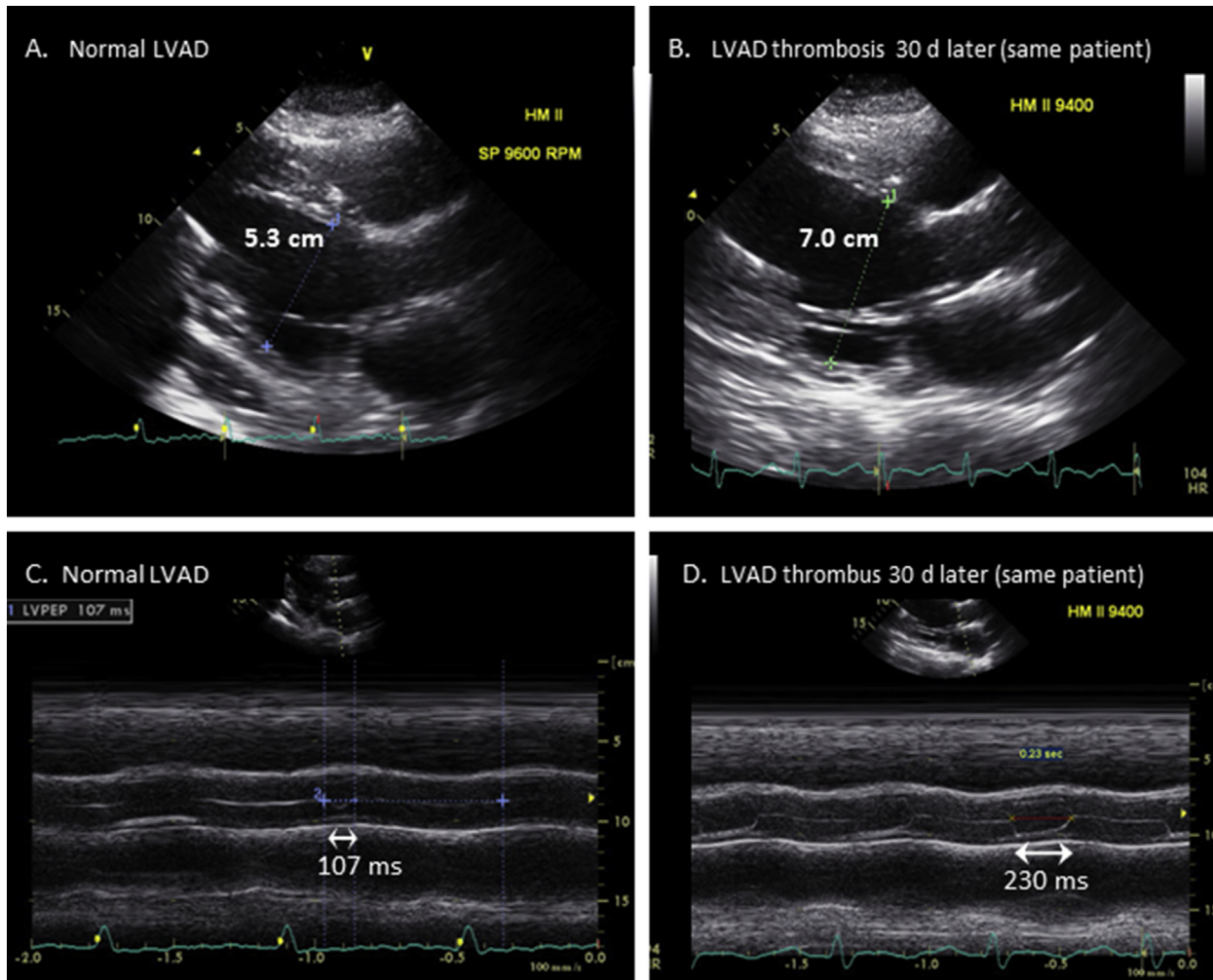


Figure 15 Side-by-side comparison of multiple imaging metrics in the same patient before and after HM-II LVAD impeller thrombosis. **(A)** LVVIDd, normal LVAD; **(B)** increased size by LVVIDd after LVAD thrombosis; **(C)** AV M-mode, minimal opening (107 ms) during normal LVAD function; **(D)** markedly increased AoV opening duration (230 ms) after internal LVAD thrombosis; **(E,G)** Inflow-cannula color-flow (arrow) and pulsed Doppler images, respectively, during normal LVAD function (see also Video 20); **(F,H)** Very low velocity inflow-cannula systolic flow on color-flow (arrow) and pulsed Doppler images, respectively, with nearly absent diastolic flow (view H) after development of impeller thrombosis; **(I)** RVOT pulsed Doppler VTI = 15 cm during normal LVAD function; **(J)** RVOT pulsed Doppler VTI = 7.9 cm after LVAD thrombosis. *Inflow*, inflow cannula; *vel.*, velocity.

- Peak systolic and nadir diastolic inflow-cannula and outflow-graft velocities should be derived from 3 to 5 cardiac cycles, depending upon the regularity of the spectral Doppler contour.
- Outflow graft velocities of >2 m/s at any level may be abnormal and warrant further consideration for possible obstruction, although benchmark data are lacking.

Native Heart Versus LVAD Flow Assessment. In the absence of significant pulmonary valve regurgitation, the net cardiac output (combined native LV outflow and LVAD conduit flow) is the same as the right-sided cardiac output. The right-sided output is calculated by using the following commonly applied equation: RVOT cardiac output = RVOT pulsed Doppler VTI*1.314*(RVOT diameter/2)² × HRI (Figure 25), where RVOT is the right ventricular outflow tract and HR is the heart rate. When the AV does not open, and there is no significant AR, the RVOT-derived cardiac output is the same as the LVAD cardiac output. When the AV opens significantly and an adequate LVOT VTI can be measured with pulsed Doppler (and in the absence of significant AR), the LVAD cardiac output should equal

the RVOT-derived cardiac output minus the LVOT cardiac output. In the presence of significant AR and no AV opening, the LVAD flow can be assumed to be significantly greater than the RVOT-derived cardiac output, owing to a blind loop of LVAD-to-aorta flow as described, above. In cases of greater than mild AR, it may be useful to calculate the LVAD cardiac output directly by measuring flow within the outflow graft with pulsed Doppler and the following equation: LVAD output = outflow-conduit VTI*1.314*(outflow graft diameter/2)² × HRI (Figure 22),^{55,75,76} although this approach has not been well validated for the HVAD. When using this formula, increased accuracy may be achieved by measuring the outflow-graft diameter (area) directly at the site of Doppler interrogation rather than using the manufacturer's reported graft diameter (which could cause overestimation of flow).⁵⁵ The aortic regurgitant volume would then equal the LVAD stroke volume, measured directly, minus the RVOT-derived stroke volume, as described above and in Figure 25. These Doppler methods may be useful for validating normal or abnormal LVAD flows reported by the device's controller (see discussion of alarms, below) or to detect problems early, in advance of an alarm report.

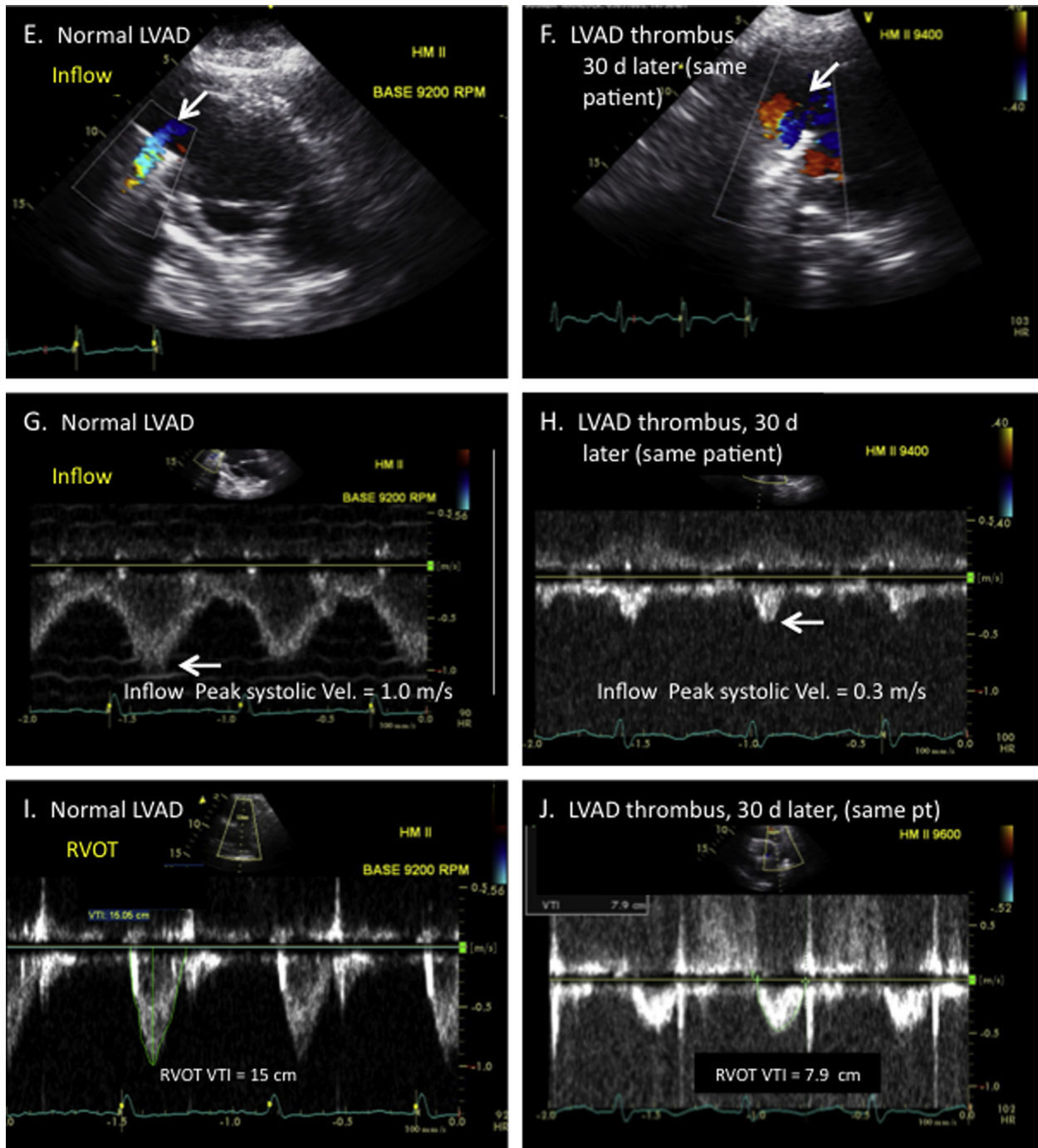


Figure 15 (continued).

KEY POINTS

- In the absence of AV opening, significant AR, or significant PR, the RVOT Doppler-derived cardiac output equals the LVAD cardiac output.
- If the AV opens and the LVOT cardiac output can be measured, the result should be subtracted from the RVOT cardiac output when computing the LVAD cardiac output.
- In the presence of significant AR and in the absence of AV opening, it may be best to directly compute the LVAD cardiac output by using pulsed-wave Doppler in the outflow graft. An estimate of regurgitant volume can then be computed by subtracting the RVOT cardiac output.

Echocardiography with Speed Changes and Safety Concerns

“Speed-change testing” occurs in the setting of either an optimization protocol or a problem-focused (ramp) exam, both of which are outlined below. Before initiating a speed-change exam, consideration of the patient’s anticoagulant status is recommended.

Speed-change testing is typically performed only if a patient has been receiving therapeutic doses of warfarin or parenteral anticoagulation therapy. Risks of performing speed changes include embolic events associated with sudden AV opening (return to pulsatile flow)

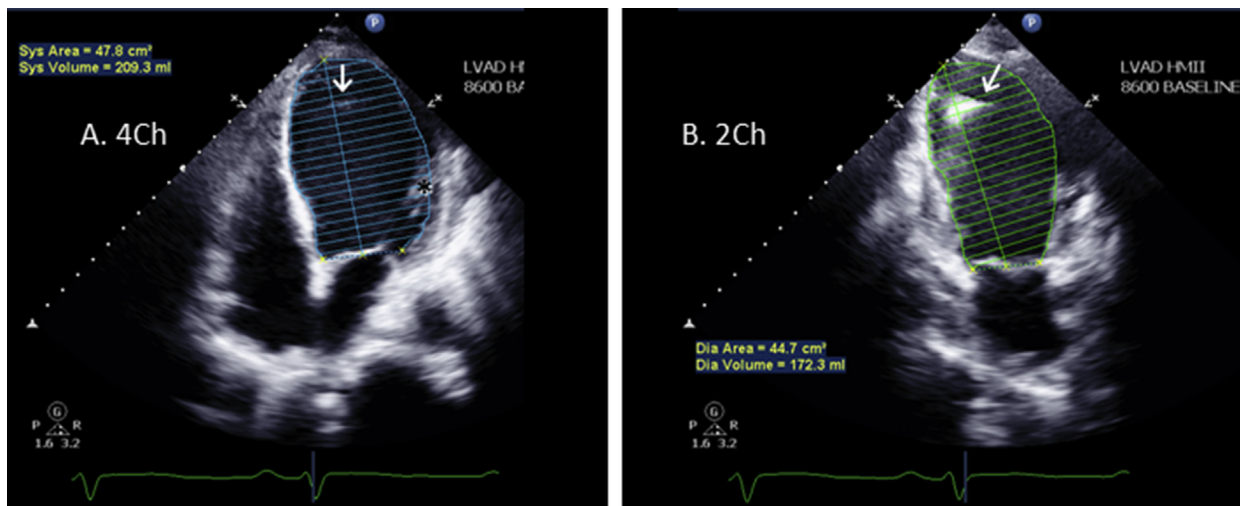


Figure 16 LVEDV, as measured by Simpson's bi-plane method of disks, is preferred for LV size assessment when possible. Simpson's single-plane LVEDV method (using the best/least-foreshortened **(A)** 4-chamber [4Ch] or **(B)** 2-chamber [2Ch] view) may suffice for LV size assessment and may be superior to linear measurements (eg, [Figure 15](#)). The inflow cannula (*arrow*) and anterolateral papillary muscle (*) are excluded from the endocardial tracing. *Note:* In view B, aneurysmal remodeling of the LV apex (relative to the LV base), which would cause underestimation of LV size by parasternal long-axis-view linear measurements (eg, [Figures 15A,B](#)). See also [Videos 21](#) and [22](#).

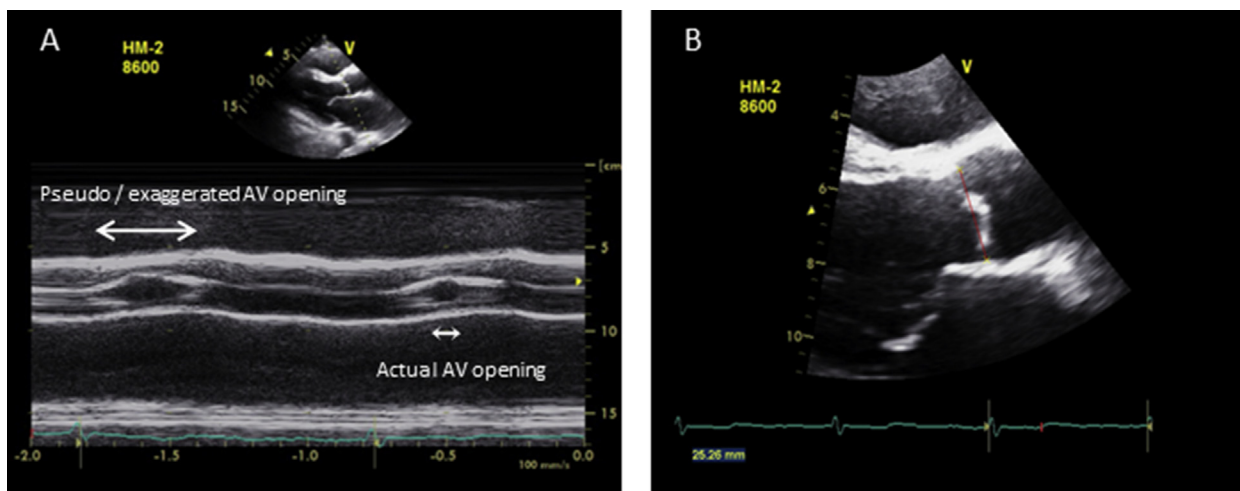


Figure 17 An exaggerated or “false” AV opening duration, as assessed by M-mode, should be suspected when the aortic cusp opening shape is fusiform **(A)**. Although the apparent M-mode AV opening duration in this case appeared to be >200 ms (*arrows*), there was, in fact, little or no AV opening. **(B)** This error was due to several factors, including the semilunar shape of the AV cusps, placement of the interrogating cursor to the left of the cusp closure line (view B: *red line*), and translational motion of the aortic root (see moving image). This pitfall could have negative implications when the examiner relies solely on M-mode for selecting the AV closing speed during an LVAD optimization protocol. M-mode should not be used in isolation. False M-mode AV opening can be identified by correlating M-mode findings with the 2D image; and color M-mode (in the presence of AR) to validate the extent of AV opening. See also [Video 23](#).

in the event of undiagnosed aortic root thrombus or the potential liberation of peripheral or internal pump thrombi, particularly at lower pump speeds. In general, strong consideration should be given to deferring speed-change exams if baseline imaging shows a possible intracardiac or aortic root thrombus. An experienced and knowledgeable member of the MCS team should be immediately available to solve potential problems and recognize key safety endpoints (discussed below) before an optimization or problem-focused echo exam is initiated. In the case of an optimization exam, unless the supervising MCS medical staff member or an experienced echocardiography medical staff member is actively supervising the exam, it is necessary for the ordering HF team to prospectively indicate what

speeds should be tested, what echo parameters should be measured at each speed, what defines the “optimal” LVAD speed for that particular patient, and what the LVAD speed should be at the conclusion of the study (eg, the “optimal” speed or the initial baseline LVAD speed setting). A structured ordering template may assist with this process, and a representative template is shown in [Table 3](#), which also outlines reasons to stop a speed-change (ramp) test. These reasons include (1) completion of the test; (2) a suction event (at higher speeds); (3) new symptoms—including, but not limited to—palpitations, dizziness, chest pain, shortness of breath, or headache, which may be related to hypoperfusion or hypotension; (4) hypertension; (5) and cannula flow reversal. Because increasing the pump speed can markedly increase

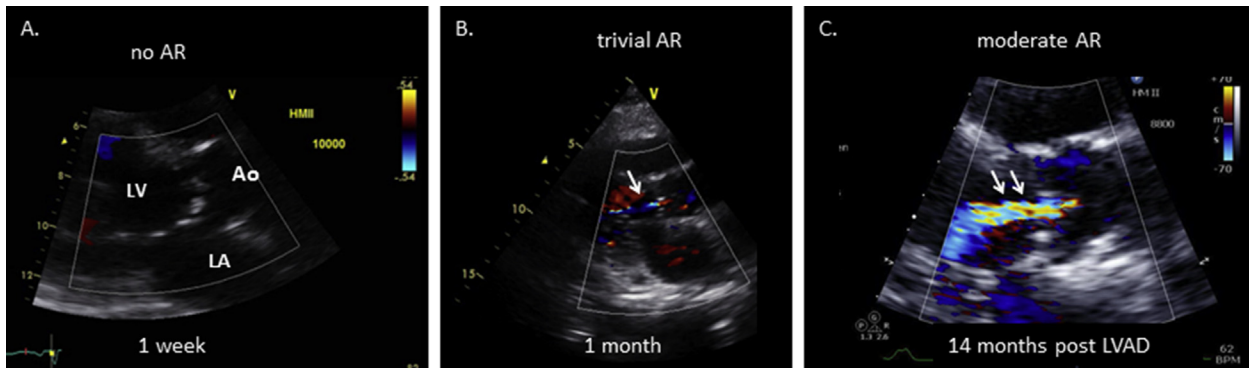


Figure 18 De novo AR after LVAD implantation. This condition progressed from no AR on the baseline surveillance study exam at 1 week (**A**) to trivial AR (arrow) at 1 month (**B**), to at least moderate AR (arrows, VC >3 mm) at 14 months (**C**). All images are transthoracic parasternal long-axis views with color Doppler. In this patient, the AV never opened at any pump speed during the LVAD support period; aortic root thrombus was not present. See also [Videos 24-26](#).

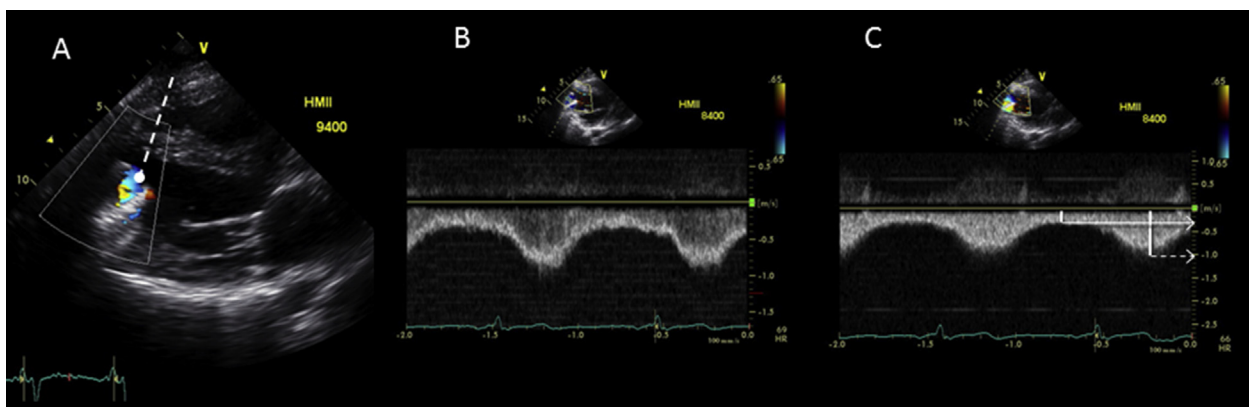


Figure 19 Normal HM-II inflow-cannula flow, which, in this case, required the use of a modified parasternal long-axis view for coaxial alignment of the sampling volume. (**A**) Color-flow Doppler with pulsed Doppler sample volume at the inflow cannula's inflow zone. See also [Video 27](#). The color-flow and pulsed spectral Doppler profiles (**B**) are consistent with laminar flow. (**C**) Peak systolic velocity = 1.0 m/s (dotted arrow) and nadir diastolic velocity = .3 m/s (solid arrow) as assessed by continuous-wave spectral Doppler. (Normal peak inflow velocities are typically <2 m/s).

the mean arterial BP, the BP should be rechecked at higher pump speed settings.⁷⁷ At lower pump speeds, particularly in the presence of elevated mean arterial pressure (hypertension), outflow-graft flow reversal can occur. The inflow-cannula color and spectral Doppler exam should be repeated at each new pump speed in order to establish the following: (1) expected progressive decrease in the peak systolic and nadir diastolic flow-velocity ratio with increasing pump speeds ([Figure 24](#)); (2) possible flow reversal (at lower speeds as mentioned or with pump arrest [[Figure 26](#)]), (3) inflow-cannula flow obstruction ([Figures 27 and 28](#): suction event) and (4) diminished or absent change in the flow-velocity profile at varying speeds in the case of internal pump thrombosis or other mechanical obstruction or significant AR ([Figure 15H](#)). Both pulsed and CW spectral Doppler interrogation of the inflow cannula is useful at the baseline speed and at each new higher pump speed in order to screen for inflow obstruction. However, Doppler evaluation of the outflow graft, although useful at the baseline speed (when possible), may be optional at subsequent pump speeds (eg, during optimization or problem-focused exams, discussed below) unless the baseline values are abnormal or the information might be otherwise relevant for clinical problem solving. The outflow-graft Doppler exam is of greater importance for HVAD patients due to an inability to measure HVAD inflow-cannula velocities with Doppler.

LVAD Optimization Echocardiography

The LVAD optimization echo exam (with speed changes) is generally performed in asymptomatic or minimally symptomatic patients with no device alarms or other clinical indicators of abnormal LVAD or cardiac function. LVAD optimization echocardiography consists of routine comprehensive TTE at the baseline speed setting ([Appendix E](#)), followed by stepwise incremental adjustments to the LVAD speed (in rpm), with collection of prespecified echocardiographic parameters ([Appendix F](#)) at each new speed, that reflects LVAD and/or native LV function (eg, LVIDd, interventricular septal position, AV-opening frequency/duration, TR and/or MR severity).^{49,70,77}

HM-II Speeds. The minimum and maximum speed settings for the HM-II LVAD are 6,000 and 15,000 rpm, respectively. The speed can be changed in 200-rpm increments. Although patient-dependent, the recommended range of typical operating speeds is 8800-10,000 rpm.⁷⁸ With the HM-II pump, speed changes for optimizing device function are usually made in small increments of 200-400 rpm.

HVAD Speeds. The minimum and maximum speed settings for the HVAD are 1,800 and 4,000 rpm, respectively. The speed can be changed in 20-rpm increments. The recommended range of typical

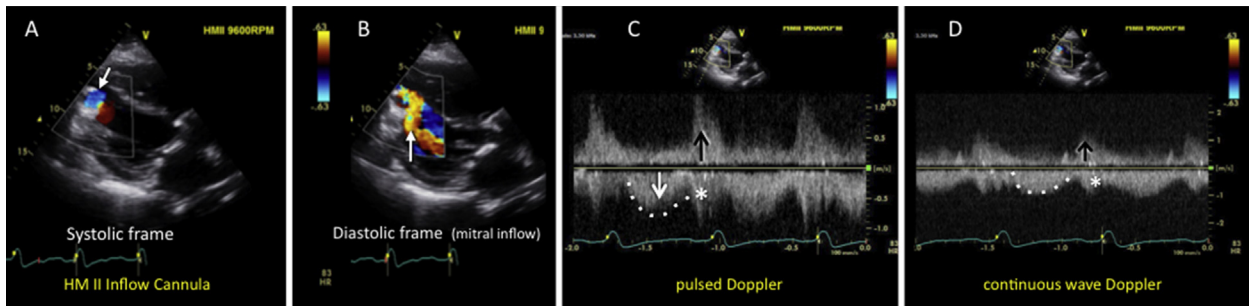


Figure 20 (A) HM-II inflow cannula, systolic frame, showing normal color Doppler inflow (blue, downward arrow). (B) HM-II inflow cannula, diastolic frame, with color Doppler showing prominent diastolic mitral inflow (orange, upward arrow) in a patient with a previous mitral annuloplasty repair. See also [Video 28](#). (C) Pulsed Doppler examination of the inflow cannula shows normal systolic inflow (dotted line). However, prominent bidirectional diastolic velocities are present due to mitral inflow (arrow) and interaction between the cannula and the adjacent interventricular septum (*) (see moving image). (D) Continuous-wave Doppler shows a similar pattern and rules out obstruction. Note: Hybrid/contaminated inflow-cannula Doppler signals may also be observed with AR jets. These types of low-velocity, normal-variant, contaminated inflow-cannula spectral Doppler patterns can be explained with color Doppler and should not be confused with higher-velocity signals (typically >2 m/sec), which could signify inflow obstruction. Nonetheless, the pure continuous diastolic inflow, as shown in [Figure 19](#), is not seen, and the diastolic nadir velocity cannot be reported.

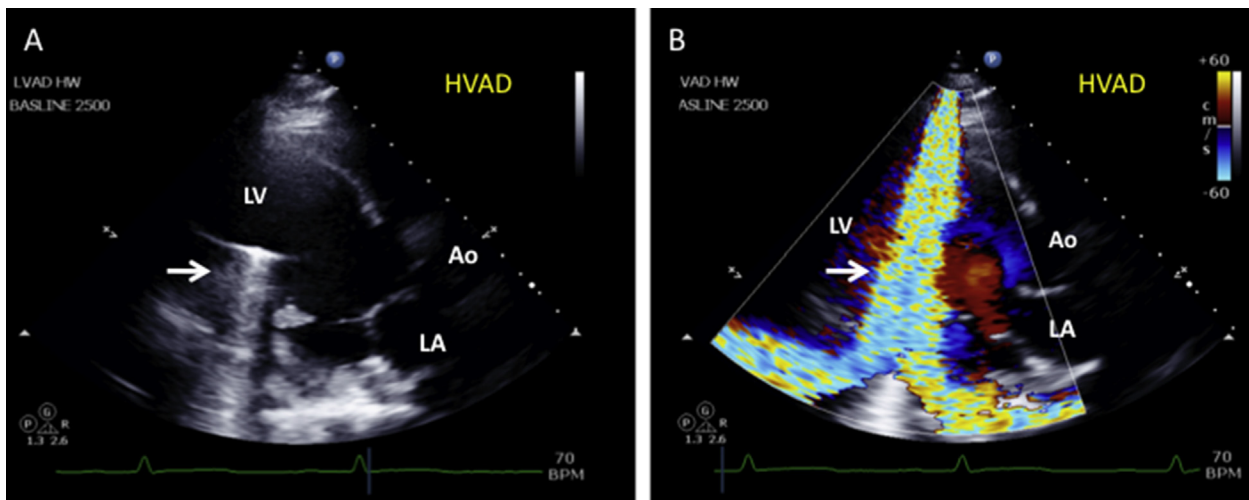


Figure 21 (A) HVAD inflow-cannula artifact (arrow), 2D parasternal long-axis view, as evaluated by TTE. (B) Typical color-flow Doppler artifact (arrow) associated with the HVAD inflow cannula. This artifact also prohibits spectral Doppler interrogation of the inflow cannula (as in [Figure 11B](#)). Inflow-cannula flow must be surmised by other means (eg, outflow-graft and RVOT flow, AV opening, and LV size changes during pump-speed changes). See also [Videos 29](#) and [30](#).

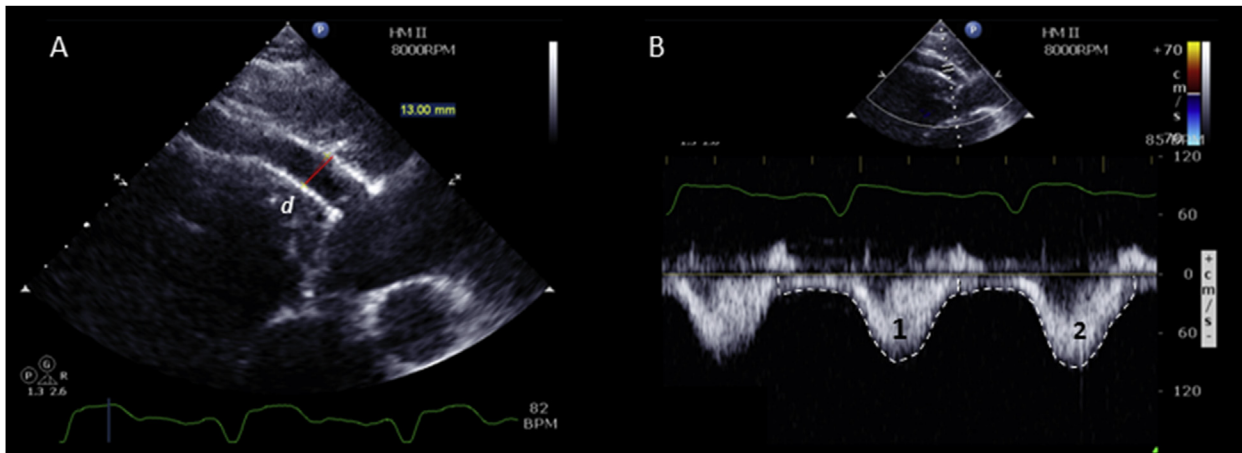
operating speeds is 2,400-3,200 rpm. With this device, speed changes for optimizing device function are usually made in small increments of 20 or 40 rpm.⁵³

Some LVAD implantation centers have chosen to include an optimization (speed-change) protocol routinely with all LVAD surveillance echo exams ([Figure 14](#)). Others have chosen to include the optimization protocol only with the initial surveillance echo examination (eg, index hospitalization discharge/2 weeks postimplantation) and then only as needed when a routine surveillance echo (without speed changes) reveals a less-than-optimal LVAD speed according to predefined criteria.^{63,70} It is important to note that utilization of echocardiography to optimize the LVAD speed is relatively new, and the impact of echocardiography-guided LVAD speed optimization protocols on short- and long-term clinical outcomes is currently unknown. [Appendix D](#) shows summary benchmark echocardiography parameters from three cohorts of patients from three different institutions, beginning before LVAD implantation and extending up to 12 months afterward.

Determination of the “Optimal” LVAD Speed. The definition of the optimal LVAD speed varies among implantation centers. However, there is a general consensus among centers that the optimal speed lies between “minimum” and “maximum” speeds, defined as follows:

The **minimum speed** is defined by **echocardiography parameters** as the speed below which the LVIDd (cm) is increased relative to baseline; the interventricular septum may be shifted rightward; MR may become more prominent; AV opening may occur or become more frequent or sustained; and estimated RA and systolic pulmonary artery pressures may increase. **Clinically**, the minimum speed is that speed below which the patient develops reduced functional capacity, congestion, and/or worsening end-organ function.

The **maximum speed** is defined **echocardiographically** as the speed above which the interventricular septum shifts leftward and/or impedes flow into the inflow cannula; TR may worsen due to the leftward interventricular septal shift with tricuspid valve annular



$$\text{LVAD output} = (\text{outflow graft } d/2)^2 \times \pi \times \text{outflow graft TVI} \times \text{HR}$$

- For irregular HR or variable stroke volumes, average 3-5 cycles
- Average outflow graft TVI = TVI (throughout n cardiac cycles) / n
- Because of continuous flow, the LVAD VTI includes the area under curve for both the systolic and the diastolic periods as shown in B, in which case $n = 2$. ($\pi \approx 3.14$)

This example: $n = 2$ cycles; $\text{TVI}_1 = 21.2$ cm, $\text{TVI}_2 = 23.6$ cm; $\text{HR} = 82$ bpm; $d_{\text{graft}} = 1.3$ cm

$$\text{TVI avg} = (21.2 + 23.6) / 2 = 44.8 / 2 = 22.4 \text{ cm}$$

$$\text{LVAD Stroke volume} = (1.3 \text{ cm}/2)^2 \times \pi \times 22.4 \text{ cm} = 29.7 \text{ ml}$$

$$\text{LVAD Cardiac output} = 29.7 \text{ ml} \times 82 \text{ bpm} = 2,435 \text{ ml} / \text{min} = 2.4 \text{ L/min}$$

Note: Although potentially useful, this type of imaging may be challenging to obtain in routine practice.

Figure 22 Direct Doppler measurement of LVAD flow from the distal outflow graft, as evaluated by TTE (A). See also Video 31. Flow (stroke volume and cardiac output) within the outflow graft (LVAD output) may be derived by measuring the graft's diameter (arrow) and the pulsed Doppler VTI at the same location, proximal to the anastomosis site (B).

distortion and/or RV enlargement; the AV may cease opening; and AR (when present) is increased. Some or all of these changes above the maximal speed may constitute a "suction event," with low-flow alarms (see below).

To provide a margin of safety, implantation centers that view maximal LV unloading as paramount in HF management will define the optimal LVAD speed as being just below the maximum speed even when the AV remains closed (typically at least 400 rpm below the maximum speed for the HM-II⁷⁸ and at least 40 rpm below the maximum speed for the HVAD). Implantation centers that desire AV opening, when possible, will choose a lower "optimal" LVAD speed, at which AV opening occurs either intermittently or during every cardiac cycle, combined with other echocardiographic data to suggest clinically adequate (if not maximal) LV unloading. A subset of these centers may elect to maximize the AV-opening duration. As noted above, Appendix F provides a typical set of parameters that can be measured at each speed during an LVAD optimization exam, including LVIDD, interventricular septal position, AV-opening frequency/duration, MR severity, and/or TR severity and velocity and cannula flow velocities.

LVAD Problem-Focused Echocardiography

An LVAD problem-focused echocardiography exam should be performed whenever the HF team suspects a problem with LVAD function. The problem-focused exam is generally triggered and guided by one or more of the following indications:

1. An LVAD controller alarm.
2. New or abnormally persistent symptoms.
3. Abnormal serologic findings that suggest intravascular hemolysis or infection.
4. Follow-up testing of abnormalities detected on an echocardiogram at the baseline pump speed.
5. Other abnormal imaging data, monitored results (eg, arrhythmias, hypotension), or other clinical tests that suggest LVAD malfunction.

To maximize the efficiency and utility of a problem-focused echo exam, the HF team should provide the echo lab personnel with the study indication(s). Table 3 presents recommendations for typical exam indications and a list of appropriate LVAD exam protocols.

Regardless of the indication(s), the LVAD problem-focused echo examination begins with all the elements of an LVAD surveillance echo exam (Appendix E), performed at the baseline pump speed setting. This initial portion of the exam does not include any speed changes, and it may generally be performed by a sonographer without MCS staff members present, unless the patient's condition is unstable. Thereafter, the number of different speeds required and the incremental speed changes needed may vary, depending on the suspected problem and the observed response to a speed change in real time. Accordingly, the "speed-change" component of a problem-focused echo exam frequently requires the immediate availability of MCS team members and/or trained echo medical staff for interpreting responses to device speed changes and recognizing safety endpoints for the exam, as discussed above and summarized in Table 3. Incorporating safety endpoint considerations

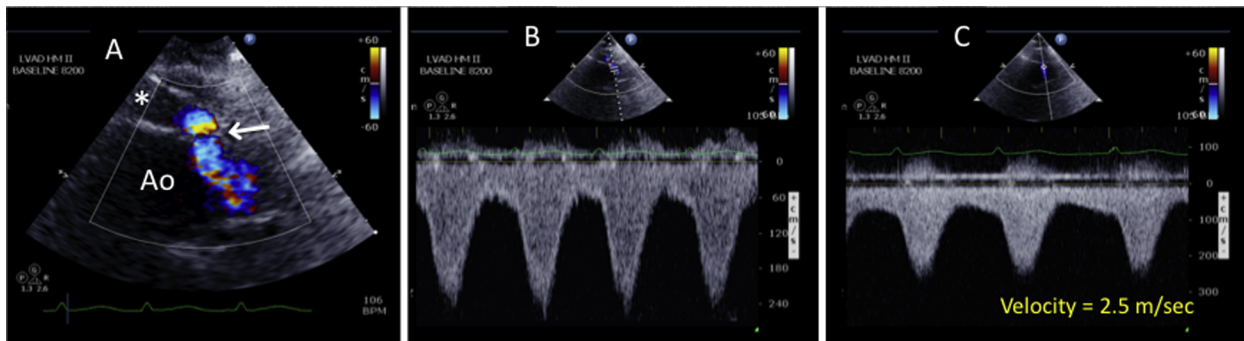


Figure 23 Mild stenosis of the LVAD outflow graft-to-ascending aorta anastomosis site, as assessed by TTE using color and spectral Doppler. **(A)** 2D image: outflow graft (*). The aliased color-Doppler signal reveals the site of anastomotic stenosis (arrow). See also [Video 32](#). **(B)** Pulsed-Doppler examination of the anastomotic region shows turbulent flow and an abnormally high peak systolic velocity. **(C)** Continuous-wave Doppler reveals an abnormally high anastomotic velocity of 2.5 m/sec.

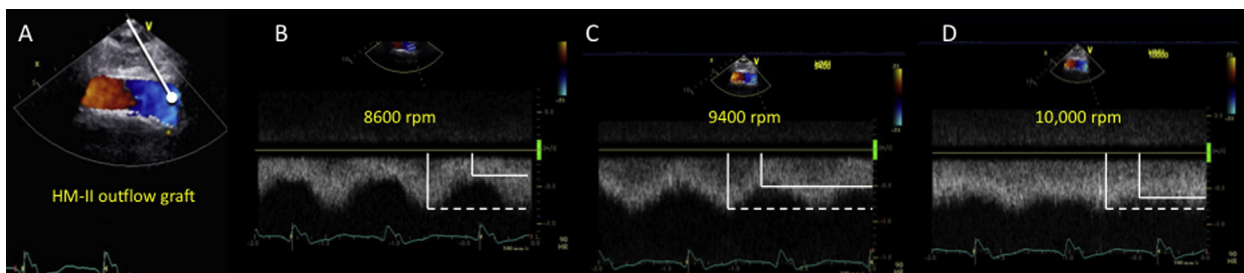


Figure 24 LVAD outflow graft, mid right parasternal window, on TTE. The flow velocity within the outflow graft should appear laminar, with a characteristic diminution of the peak systolic velocity (*dotted line*) and increase in the nadir diastolic velocity (*solid line*) as the pump speed is systematically increased (narrowing of the pulse pressure). *Note:* A similar diminution of the peak systolic velocity and increase in the nadir diastolic velocity occurs as the pump speed is systematically increased in the absence of any provoked inflow obstruction. See also [Video 33](#).

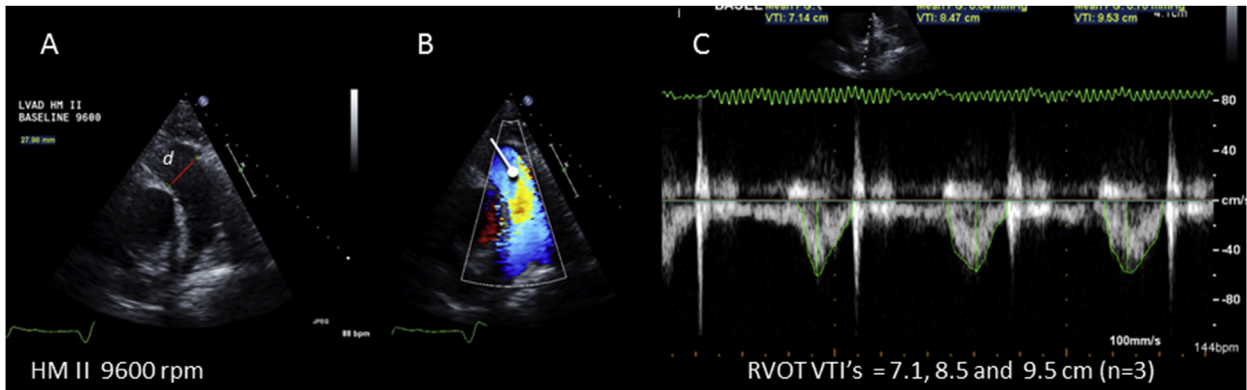
into the conduct of the exam requires considerable knowledge and clinical judgment, and the required staff may or may not be readily available at the bedside to provide the requisite expertise. In some cases, it makes logistical sense for the sonographer to perform the initial comprehensive, baseline “single-speed” phase of the problem-focused exam as a discrete study. Then, after the results are formally interpreted and communicated to the HF team, the speed-change component may be added more strategically, pending availability of the appropriate additional team members. On the other hand, for patients in unstable condition, the situation may need to be managed more expediently, and device speed adjustments may supersede the need for a comprehensive baseline exam. In any case, the HF treatment team, sonographers, and echocardiographers should be familiar with both the clinical indications and characteristic echocardiographic findings for the most frequently encountered normal and abnormal clinical scenarios. [Table 2](#) describes the most common abnormal echocardiography findings that may be encountered, regardless of the indication for the exam (eg, surveillance [no symptoms or alarms] vs. problem-focused). [Table 4](#) outlines the most common LVAD alarm situations and the possible/expected associated echocardiographic findings.

Performing an LVAD Problem-Focused Exam with Speed Changes. The LVAD problem-focused echo exam with “speed changes” (also known as a “ramp study”) is used to test for suspected

abnormal pump function (eg, pump thrombosis)^{77,79,80} to investigate device alarms, and/or to establish the significance of specific cardiac abnormalities (eg, significant AR, worsening MR, RV failure). For ramp studies, one typically uses larger incremental changes in pump speeds than are used for an LVAD optimization protocol associated with a surveillance exam (noted above). “Ramp-up” LVAD problem-focused echo protocols have been designed specifically to test for internal pump thrombosis.^{77,79,80} Ramp protocols may be used to assess the clinical significance of other problems, such as suspected RV dysfunction, pericardial effusion, or AR, and for problem solving in the setting of device alarms (outlined below). The following important parameters should be evaluated at each pump speed (see [Appendix F](#)): LVIDd; RVOT VTI (for RVOT stroke volume and cardiac output); degree of AV opening; characteristics of the inflow cannula (and the outflow graft when possible), as evaluated by spectral Doppler; degree of AR and MR; MV inflow parameters, as assessed by standard Doppler; interventricular and interatrial septal position; degree of TR; and estimated RV systolic pressure. Reasons to stop a speed-change (ramp) test are outlined in the discussion above and are listed in [Appendix G](#).

KEY POINTS

- Speed-change echocardiography may be added to a surveillance exam (if an optimization protocol is in place) or used in the context of a problem-focused or recovery exam.



$$\text{Total cardiac output (LVAD + Native LVOT)} = \text{RVOT } d/2^2 \times \pi \times \text{RVOT VTI} \times \text{HR}$$

Figure 25 The total cardiac output (combined LVAD flow output and native LVOT flow output [if any]) is the same as the RVOT cardiac output. The RVOT cardiac output is measured by using standard imaging techniques including **(A)** measurement of the RVOT (pulmonary annulus) diameter (d). Color-flow **(B)** and spectral Doppler **(C)** studies are performed to rule out significant pulmonary regurgitation and to measure the RVOT VTI. *Note:* In the case shown above, the RVOT VTI is low (7–9 cm) at a relatively high HM-II pump speed of 9600; this was consistent with a low cardiac output, which was due to an obstructed (kinked) outflow graft. It may be useful to average 3 to 5 VTIs, depending on their variability.

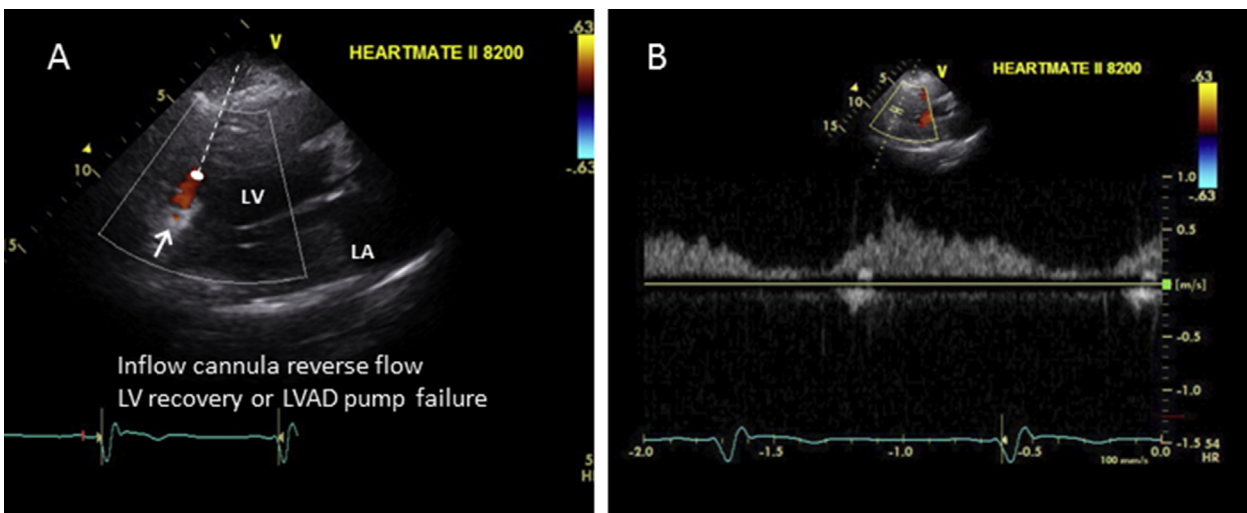


Figure 26 TTE, in the modified parasternal long-axis view, shows HM-II inflow-cannula diastolic flow reversal in a normally functioning LVAD at a relatively low pump speed (8200 rpm) in a patient with significant LV recovery (see moving image). **(A)** Color-flow Doppler image. The inflow cannula is denoted by an *arrow*. See also [Video 34](#). **(B)** Pulsed spectral Doppler image of the inflow cannula shows reduced systolic forward flow but pandiastolic regurgitant flow (aorta to left ventricle) due to improved diastolic recoil. *Note:* A similar Doppler pattern is seen with LVAD pump arrest, although such arrest is associated with symptoms and echocardiographic signs of HF.

- Speed-change echocardiography should generally occur under the supervision of an experienced MCS medical staff member.
- A current BP recording (as previously described) should be documented at baseline and repeated, when indicated, after pump-speed changes (particularly when the speed is increased).
- Speed-change echocardiography can precipitate an embolic event and should be performed only after confirming the patient's anticoagulation status and after excluding an intracardiac/aortic root thrombus on baseline imaging.
- An institution's speed-change echocardiography protocols should specify the speeds to be tested, echocardiography parameters to be measured, definition of "optimal" LVAD speed, reasons for early termination, and desired LVAD speed settings after study completion.
- Typically, a comprehensive exam is performed at the baseline speed.
- Subsequent imaging at other pump speeds can be tailored to the indication for the exam.
- Doppler: At a minimum, speed-change echocardiography should include interrogation of the inflow cannula by pulsed-wave and CW Doppler to screen for the development of obstruction at higher pump speeds (which is possible for the HM-II but not possible for the HVAD).
- Color-flow and spectral Doppler at each new speed to assess the degree of AR, MR, TR, and RVOT flow from the parasternal view (and other available

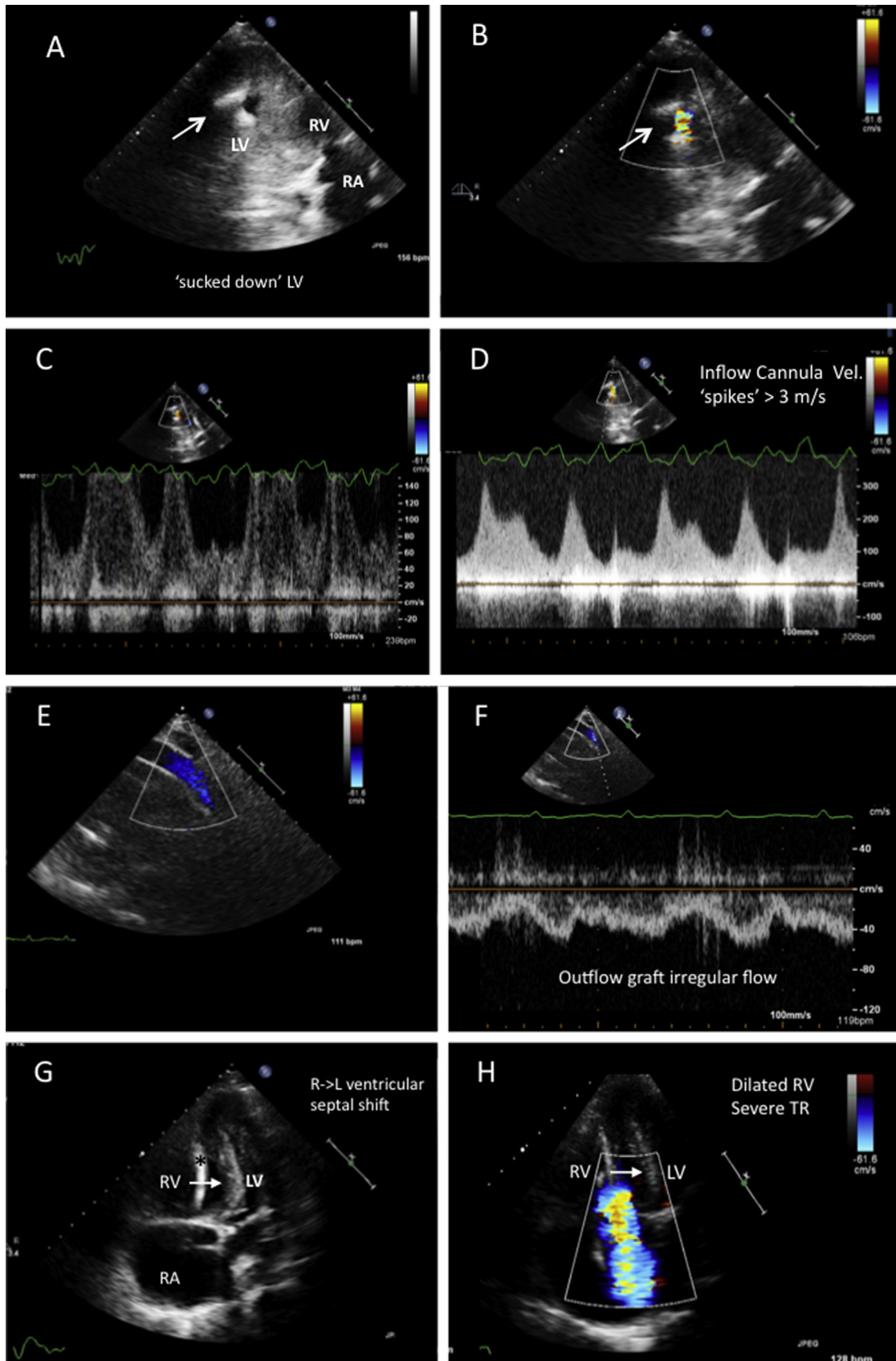


Figure 27 Suction event at a relatively low pump speed (HM-II, 8200 rpm) consistent with severe RV failure. (Because this condition was refractory to medical management, the patient received an RVAD after this exam). **(A)** Modified parasternal RV inflow-tract view. The tiny LV cavity is “sucked down” around the inflow cannula (arrow), and the ventricular septum is bowed towards the left. See also

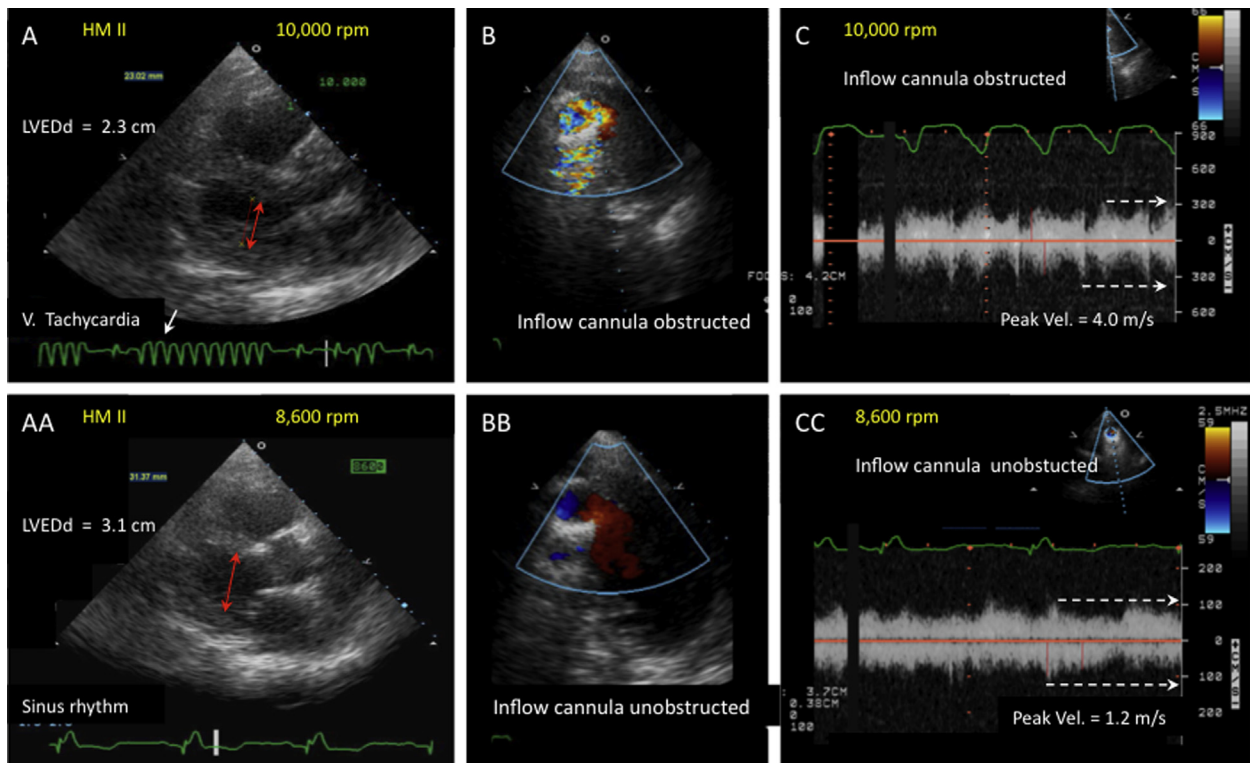


Figure 28 Mechanical ventricular tachycardia due to a suction event at a high pump speed (10,000 rpm), due to new hypovolemia resulting from a gastrointestinal illness. **(A)** Small LV chamber size (LVEDd = 2.3 cm, red arrows), with frequent nonsustained ventricular tachycardia (white arrows). See also [Video 39](#). **(B)** Turbulent, aliased inflow-cannula inflow, as assessed by color Doppler. See also [Video 40](#) and [41](#). **(C)** Complex, “spiky,” high inflow-cannula inflow velocities up to 4 m/s on continuous-wave Doppler examination. **(AA)** Reducing the pump speed (to 8600 rpm) immediately increased the LVEDd (to 3.1 cm, red arrows) and eliminated the ventricular tachycardia (ie, reduced mechanical contact between the ventricular septum and the inflow cannula). Normal low-velocity inflow-cannula flow is observed on color-flow **(BB)** and continuous-wave Doppler (see also [Video 42](#)) **(CC)** at the reduced pump speed. The LV size remained small (3.1 cm) because of the hypovolemia, which later resolved. *Note:* Mechanical ventricular tachycardia may also be associated with excessive inflow-cannula angulation towards the septum or other endocardial surfaces after sternal closure, particularly at increased pump speeds.

windows) can be useful, particularly if the patient is symptomatic or abnormalities are detected on the baseline study.

- Outflow-graft Doppler (possible for both the HM-II and HVAD) should be attempted at the baseline speed and at other speeds if the patient is symptomatic or pump malfunction is suspected.
- At a minimum, imaging of AV opening (M-mode), inflow-cannula position, LV and RV size, and atrial and ventricular septal positions at each new speed may be useful, depending on the reason for the exam.
- Although the definition of the “optimal” LVAD speed varies among implantation centers, minimum and maximum LVAD speeds are invariably defined by echocardiographic parameters.

Echocardiographic Assessment of Abnormal LVAD Alarms

This section outlines the types of abnormal controller alarms, their differential diagnoses, and the extent to which a problem-focused echo-

cardiogram can validate and/or explain the alarm’s cause. The LVAD surveillance and problem-focused echo exams outlined above can frequently detect early abnormalities before controller alarms are triggered, providing a means for preemptive management decisions. On the other hand, LVAD controller alarms may be triggered with or without patient symptoms or other abnormal clinical findings. In any case, audible controller alarms will alert patients or caregivers to seek medical attention. Sonographers and echocardiographers should have some familiarity with the different alarm types and the LVAD controller parameters in order to acquire the appropriate echocardiographic information.

Speed denotes the revolutions per minute (rpm) of the impeller. The pump speed is adjusted via the device controller. As noted above, the HM-II LVAD is capable of 6,000-15,000 rpm (typical

Video 35. (B) Aliased color-flow Doppler image of the inflow cannula. **(C)** Aliased high-velocity pulsed spectral Doppler image of the inflow cannula. See also [Video 36](#). **(D)** Continuous-wave spectral Doppler examination of the inflow cannula shows irregular flow, with systolic velocity “spikes” of up to 3.5 m/sec during tachycardia (HR = 154 bpm). **(E)** Right parasternal TTE view of the outflow graft shows low-velocity laminar flow, as evaluated by color Doppler. **(F)** Pulsed Doppler of the outflow graft, shows an irregular pattern low-velocity flow, consistent with variable degrees of severe inflow-cannula obstruction. **(G)** Apical 4-chamber view shows severely dilated right-sided chambers, a tiny LV cavity, and right-to-left bowing of the interventricular septum (arrows), with associated severe TR on color-flow Doppler **(H)**. See also [Videos 37](#) and [38](#). The asterisk denotes a pacing lead.

Table 4a LVAD Low-flow alarm differential and echocardiographic findings

VAD Alarm Findings	HM-II* PI decrease PI event HVAD Suction display	HM-II*: PI decrease PI event Low-flow alarm Flow display “----” HVAD: Low-flow display Suction display	HM-II* PI decrease PI event Low-flow alarm Flow display “----” HVAD: Low-flow display Suction display	HM-II* PI decrease PI Event Low-flow alarm Flow display”----” HVAD Low-flow display Suction display	HM-II*: Increase PI#	HM-II*: Decrease PI PI event Low-flow alarm Flow display”----;” HVAD: Low-flow display Suction display	HM-II*: Decrease PI PI event Low-flow alarm Flow display “----” HVAD: Low-flow display Suction display
Clinical Diagnosis	LVAD suction event†	Hypovolemia	RV failure	Tamponade	Malignant hypertension	Inflow thrombus or outflow-graft kinking/obstruction	Arrhythmias
Possible Echo Findings‡	LV size: decrease RV size: depends on cause Interatrial septal shift: depends on cause† Interventricular septal shift: depends on cause† AV opening: depends on cause† MV regurgitation: depends on cause† TV regurgitation: depends on cause† RAP estimate§: depends on cause† Other: Inflow cannula abutting endocardium and position “off-axis”# Increased inflow-cannula peak velocity with partial obstruction as cause¶ Ventricular ectopy or dysrhythmia on ECG gating	LV size: decrease RV size: smaller or no change Interatrial septal shift: no change Interventricular septal shift: no change AV opening: may decrease MV regurgitation: possible decrease TV regurgitation: possible decrease RAP estimate§: decrease Other:	LV size: decrease RV size: increase Interatrial septal shift: towards left Interventricular septal shift: towards left AV opening: decrease MV regurgitation: no change TV regurgitation: increase RAP estimate§: increase Other:	LV size: decrease RV size: decrease Interatrial septal shift: no change Interventricular septal shift: no change AV opening: no change MV regurgitation: no change TV regurgitation: may increase RAP estimate§: increase Other: Compressed left and/or right atrium Pericardial effusion	LV size: increase RV size: no change Interatrial septal shift: no change Interventricular septal shift: no change AV opening: decrease MV regurgitation: increase TV regurgitation: no change RAP estimate§: no change Other: Increased outflow-cannula peak systolic velocity Relative increase in estimated left sided ventricular filling and pulmonary pressure	LV size: increase RV size: no change Interatrial septal shift: no change Interventricular septal shift: no change AV opening: increase MV regurgitation: increase TV regurgitation: no change RAP estimate§: increase Other: Elevated peak outflow-cannula velocity >2 m/s with partial obstruction¶ Blunted change in the following parameters with pump-speed augmentation: LVEDd reduction RVOT VTI increase MV DT increase AV opening reduction	LV size: no change RV size: may increase Interatrial septal shift: may shift left with RV failure Interventricular septal shift: typically no change AV opening: may decrease MV regurgitation: may increase TV regurgitation: may increase RAP estimate§: may increase Other: LVAD suction-event findings may be seen

AV, aortic valve; DT, deceleration time; ECG, electrocardiography; HM-II, HeartMate II left ventricular assist device; HVAD, HeartWare ventricular assist device; LV, left ventricular; LVAD, left ventricular assist device; LVEDd, left ventricular end-diastolic diameter; MR, mitral regurgitation; MV, mitral valve; PI, pulsatility index; RAP, right atrial pressure; RV, right ventricular; RVOT, right ventricular outflow tract; TV, tricuspid valve; VAD, ventricular assist device; VTI, velocity time integral.

*HeartMate (HM)-II feature. PI = Pulsatility index, which is the left ventricle’s pulsatile contribution to the pump; a PI event occurs when there is a 45% + or – change from the previous 15-second running average.

†An LVAD suction event can be seen with hypovolemia, RV failure, and tamponade and may be associated with arrhythmias (atrial and/or ventricular) and/or inflow cannula malposition.

‡Changes may be seen and are typically relative to individual benchmark data obtained from previous echo parameters at a similar LVAD pump speed.

§Based on IVC size and response to inspiration and hepatic vein flow (diastolic predominance or systolic flow reversal).

||HVAD feature for suction event.

¶May observe diminished peak inflow and/or outflow velocity with complete obstruction (very rare).

#Variable power/flow and PI changes can be seen, depending on the severity of hypertension.

Table 4b LVAD high-flow (high-power) alarm differential and echocardiographic findings

VAD Alarm Findings	HM-II* Power >10 watts Flow display “+++” Decreased PI PI event HVAD Alarm display high-watt [§]	HM-II* Decreased PI (or constant) PI event	HM-II* PI event HVAD Alarm display high-watt [§]
Clinical Diagnosis	Rotor/bearing thrombosis with pump malfunction [†]	Sepsis syndrome or medication vasodilation effect	Significant AR
Possible Echo Findings [‡]	LV size: increase RV size: no change Interatrial septal shift: no change or rightward if elevated LAP Interventricular septal shift: no change AV opening: increase MV regurgitation: increase TV regurgitation: typically no change RAP estimate : may increase due to left-sided HF Other: Matched left and right ventricular outflow stroke volume Increase in estimated left-sided ventricular filling and pulmonary pressure Blunted change in the following parameters with pump-speed augmentation: LVEDd reduction RVOT VTI increase MV Deceleration time increase AV opening time reduction Inflow-cannula position “off-axis” [¶] Increase in the inflow cannula or outflow cannula systolic-to-diastolic peak velocity ratio	LV size: no change RV size: no change Interatrial septal shift: no change Interventricular septal shift: no change AV opening: increase MV regurgitation: no change or decrease TV regurgitation: no change RAP estimate : no change Other:	LV size: increase RV size: no change Interatrial septal shift: no change or rightward if elevated LAP Interventricular septal shift: no change AV opening: typically none MV regurgitation: no change or increase TV regurgitation: typically no change RAP estimate : may increase due to left-sided HF Other: Color-Doppler signs of AR throughout cardiac diastole and systole Typically moderate or greater severity characterized by: Vena contracta width ≥ 0.3 cm or Jet width/LVOT width $\geq 46\%$ Decrease in RVOT stroke volume Increase in systolic pulmonary artery pressure

AR, Aortic regurgitation; AV, aortic valve; HM-II, HeartMate II left ventricular assist device; HVAD, HeartWare ventricular assist device; LAP, left atrial pressure; LV, left ventricular; LVAD, left ventricular assist device; LVEDd, left ventricular end-diastolic dimension; LVOT, left ventricular outflow tract; MV, mitral valve; PI, pulsatility index; RAP, right atrial pressure; RV, right ventricular; RVF, right ventricular failure; RVOT, right ventricular outflow tract; TV, tricuspid valve; VAD, ventricular assist device; VTI, velocity time integral.

*HeartMate (HM)-II feature: PI = pulsatility index, which is the left ventricle's pulsatile contribution to the pump; a PI event occurs when there is a 45% + or - change from the previous 15-second running average.

[†]Diagnosis is suspected if associated with significant hemolysis and other signs (see text) and may be confirmed by visual inspection if the pump is exchanged.

[‡]Changes may be significant relative to normal LVAD benchmarks or individual benchmark data obtained from previous echo parameters at a similar LVAD pump speed.

[§]HVAD feature: alarm display with potential causes provided.

^{||}Based on inferior vena cava size and response to inspiration and hepatic vein flow (diastolic predominance or systolic flow reversal).

[¶]“Off-axis” relative to normal direction of inflow cannula directed towards the mitral valve.

clinical operating range, 8,800-10,000 rpm),⁷⁸ and the HVAD is capable of 1,800-4,000 rpm (typical clinical operating range, 2,400-3,200 rpm). The concern with lower pump speed settings is that a relative low-flow state and stagnation of blood may predispose to development of impeller thrombosis. At higher pump speeds, suction events could occur.

Power is a direct measurement of pump motor voltage and current and generally varies directly with speed (eg, higher speeds

are associated with higher power). It is measured continuously and displayed on the controller panel as an average over time in watts (a typical value is <10 W). A “**power spike**” refers to an increase in power without an increase in speed and may indicate a mechanical obstruction. For both the HM-II and the HVAD, recurring power spike values that differ from baseline values by ≥ 2 W are concerning, because they may indicate mechanical obstruction due to impeller thrombosis.

Flow (L/min) is an estimated value that is directly related to the selected speed (rotary pump rotation in rpm) and power. In estimating flow, the HVAD also accounts for blood viscosity derived from the hematocrit. For the HVAD, a hematocrit change of more than $\pm 5\%$ should prompt updating of the system monitor to avoid substantial flow calculation errors, especially at lower LVAD speeds.^{9,81}

Pulsatility denotes the difference between the minimum and maximum flows calculated by the device and is analogous to the difference between the trough and peak of an arterial waveform tracing. Pulsatility is directly related to residual native ventricular contractility and is inversely related to afterload. **The pulsatility index (PI)** is a parameter relevant to the HM-II controller that is tangentially related to pulsatility. The PI, also a derived value, is calculated from the highest-to-lowest power readings over a range, divided by the average power over that range. The PI corresponds to the magnitude of flow through the pump and will increase with increased preload, improved ventricular contractility, and a reduced afterload.

Alarms, in general, can be classified as either **low-flow** or **high-flow/high-power**. Pump parameter deviations and identified alarms should be placed in a clinical context (see Table 4) and validated with further testing when their etiology is not clearly apparent to the MCS team. The clinical symptoms and signs, along with the type of LVAD alarm findings, will guide the diagnosis and treatment recommendations. Readers are referred to the most recent practice guidelines to review the clinical presentations and treatment recommendations for LVAD-specific problems (ie, pump thrombosis).⁴ The HM-II device's low-flow alarms may be associated with, or defined by, one or more of the following signs: the PI is decreased, a PI event is noted (a 45% +/- change from the previous 15-second running PI average), a low-flow alarm is displayed, or flow displayed as "—" is noted as the flow estimate. HVAD low-flow alarms appear as "Low Flow" or "Suction" on the controller alarm display.

KEY POINTS

- Key parameters common to most LVAD consoles are speed, power, and flow. LVAD controller alarms are typically triggered by abnormalities in one or more of these parameters.
- Knowledge of a patient's clinical status, in addition to the alarm type, can help guide echocardiographers during image acquisition (to determine the extent of the exam) and interpretation.
- For clinical problem-solving, it may be useful to divide controller alarms into either "low-flow" or "high-flow," as each of these is associated with a unique set of differential diagnoses (see Table 4a,b).
- "Low-flow" alarms can be caused by "suction events," RV failure, hypovolemia, cardiac tamponade, inflow-cannula/outflow-graft obstruction, malignant hypertension, and/or arrhythmias.
- "High-flow/high-power" alarms can be caused by pump thrombosis, systemic arterial vasodilation, significant AR, and/or recovery of native LV function. Differentiation between possible causes of alarms generally requires evaluation of both clinical and echocardiographic parameters.

Low-Flow Alarms. The differential diagnosis of low-flow alarms focuses on patient-related factors, including LVAD suction events, RV failure, hypovolemia, cardiac tamponade, apical inflow-cannula or outflow-cannula kinking or obstruction, malignant hypertension, and atrial and ventricular arrhythmias.

Suction Events.—As previously noted, LVAD suction events relate to contact of the inflow cannula and the LV endocardium, which results

in reduced inflow-cannula flow and can be associated with a change in clinical status (eg, presyncope and/or palpitations from ventricular arrhythmias) and/or LVAD function. Any condition that produces LV under-filling places a patient at risk for LVAD suction events. These events can result from hypovolemia (Figure 28), RV failure (Figure 27), cardiac tamponade (Figure 29), and/or pump speed settings that are too high for the prevailing hemodynamic conditions. During suction events, the LVAD "sucks down" the LV chamber to an abnormally small size, leading to a right-to-left ventricular septal shift. Patients with a malpositioned inflow cannula may be predisposed to the development of intermittent inflow-cannula obstruction and/or ventricular arrhythmias from mechanical contact with adjacent (usually septal) endocardium (Figure 28). Monitoring for possible suction events is an important component of a ramp or speed-change protocol, as discussed above. The treatment recommendation is typically twofold: (1) decrease the pump speed and (2) identify and treat the underlying cause of the event.

RV Dysfunction.—There is a spectrum of RV dysfunction severity that can be defined clinically or by echocardiography. Right ventricular dysfunction may or may not be associated with suction events. With acceptable LVAD and RV function, the interventricular septum typically is neutrally positioned at a pump speed that can provide an adequate cardiac output by virtue of an adequate available preload from the right ventricle. In patients with advanced RV dysfunction or failure (based on a severely elevated RV end-diastolic pressure and a very low RV cardiac output) investigation of a low-flow alarm may reveal that the interventricular septum is significantly and continuously bowed towards the left ventricle. New or worsening RV dysfunction can be evaluated echocardiographically by assessing changes from the baseline exam with regard to RV size and function, inferior vena cava size and collapsibility, Doppler measures of pulmonary pressures, and color and spectral Doppler interrogation of TR severity (Figure 27).

Tamponade.—Clinically, pericardial or thoracic cavity tamponade may mimic RV failure and result in a low-flow alarm. Because the LVAD is generally the primary determinant of mitral inflow and significantly influences outflow, there may not be an exaggerated flow paradox across any valves despite increased intrapericardial pressure in cases of tamponade. Therefore, clinical suspicion of tamponade should be high if pericardial effusion or a suspected hematoma is visualized (Figure 29) in conjunction with low-flow alarms and small LV and/or RV chambers. In any of these scenarios, the RVOT cardiac output will be decreased and will fail to vary as expected with pump speed changes.

Inflow-Cannula Obstruction.—Other causes of low-flow alarms include partial or intermittent mechanical obstruction of the inflow cannula secondary to thrombosis, large vegetations, or endocardial contact (eg, suction events). On echocardiography, findings will be similar to those of primary pump dysfunction with regard to LV size, septal shift, and AV opening. However, color and spectral Doppler-derived inflow-cannula velocities may be abnormally increased, frequently with non-uniform inflow velocity patterns (Figures 27 and 28), the severity of which may vary with the degree of residual LVAD flow. The inflow-cannula spectral Doppler velocities may be elevated as blood accelerates proximal to the obstruction, whereas outflow-graft velocities may be relatively decreased and/or appear to have peak velocity variations. Two-dimensional and 3D TTE (and especially TEE) may show thrombi and vegetations obstructing cannulas or cardiac structures (eg, areas

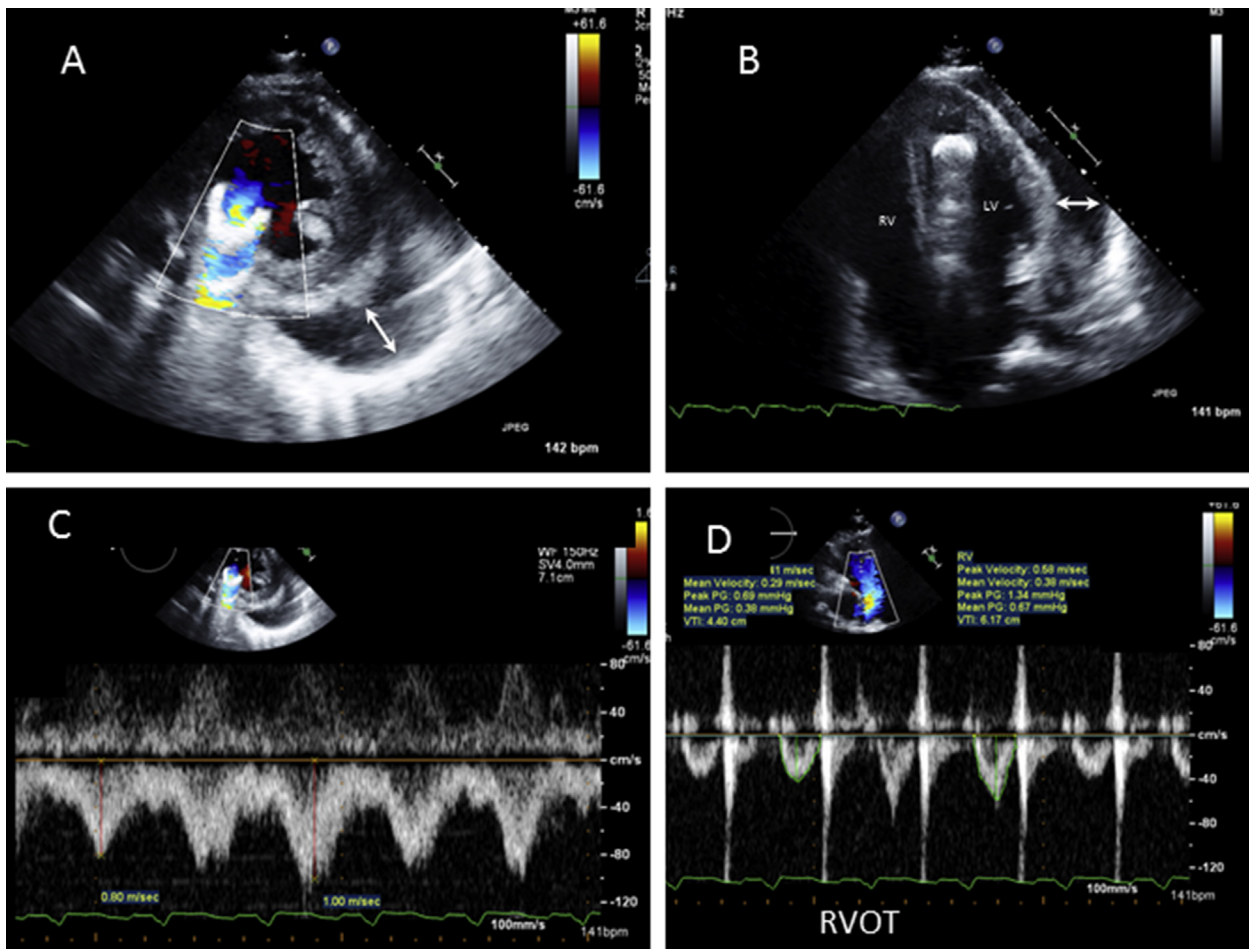


Figure 29 Tamponade after LVAD implantation was suspected because of low LVAD flow unresponsive to speed changes. A large, loculated pericardial effusion is seen posterolateral and lateral to the left ventricle (arrows). **(A)** parasternal short-axis view. See also [Video 43](#). **(B)** The apical 4-chamber view ruled out signs of RV failure. See also [Video 44](#). **(C)** Spectral Doppler examination of the inflow cannula ruled out inflow obstruction. **(D)** Pulsed Doppler evaluation of the RVOT shows very low VTIs (4-6 cm) at a high pump speed of 9000 rpm (HM-II). Although suggested in views C and D, respirophasic flow changes in flow velocities are frequently absent in LVAD recipients.

of hypertrabeculation being drawn into the inflow cannula). Inflow-cannula obstruction in the setting of a suction event is “dynamic” and can be demonstrated on a ramp study by a small LV cavity size and increased inflow-cannula velocities that normalize after reductions in pump speeds.

Mechanical Obstruction of the Outflow Graft.—Mechanical obstruction of the outflow graft (eg, resulting from kinking, malposition, external compression, or thrombosis) will function similarly to an increased afterload in opposing LVAD flow ([Figures 23 and 30](#)). Findings are similar to those of inflow-cannula obstruction, except that Doppler interrogation of the outflow graft may reveal increased or decreased velocities, depending upon the site and degree of obstruction relative to the velocity sampling site. Inflow-cannula Doppler interrogation may show normal or decreased velocities (depending upon the degree of the distal obstruction); the outflow-graft velocities may be increased if sampled in the region of an obstruction but may be normal or attenuated if sampled significantly proximal or distal to the obstruction. A ramp study may be extremely helpful by revealing attenuation of the expected intracardiac flow changes (eg, RVOT and LVOT VTIs, or conduit systolic-to-diastolic flow-velocity

ratios), LV chamber size, and the degree of AV opening at varying pump speeds.

High-Flow/High-Power (or High-Watt) Alarms. The differential diagnosis for high-power alarms focusing on patient characteristics includes impeller thrombosis, systemic arterial vasodilatation (sepsis syndrome versus a medication effect), or significant continuous AR.

Pump dysfunction can be caused by malfunction of a mechanical component, but it is more commonly caused by partial thrombosis of the impeller in CF-LVADs. Any condition that impedes the impeller rotation results in increased LVAD power consumption. In the setting of partial impeller thrombosis that results in high power consumption, the displayed high flow is a calculated and results in a false estimate of high flow. Typically the actual flow is equivalent to baseline flow or is actually decreased. Clinical features associated with pump thrombosis include hemolysis, which is characterized by hemoglobinuria along with elevated lactate dehydrogenase, total bilirubin, and serum free hemoglobin levels.^{82,83} On echocardiography, primary pump dysfunction secondary to thrombosis may manifest as signs of reduced LV unloading in comparison with the previous surveillance exam. Echocardiographic signs of reduced pump performance

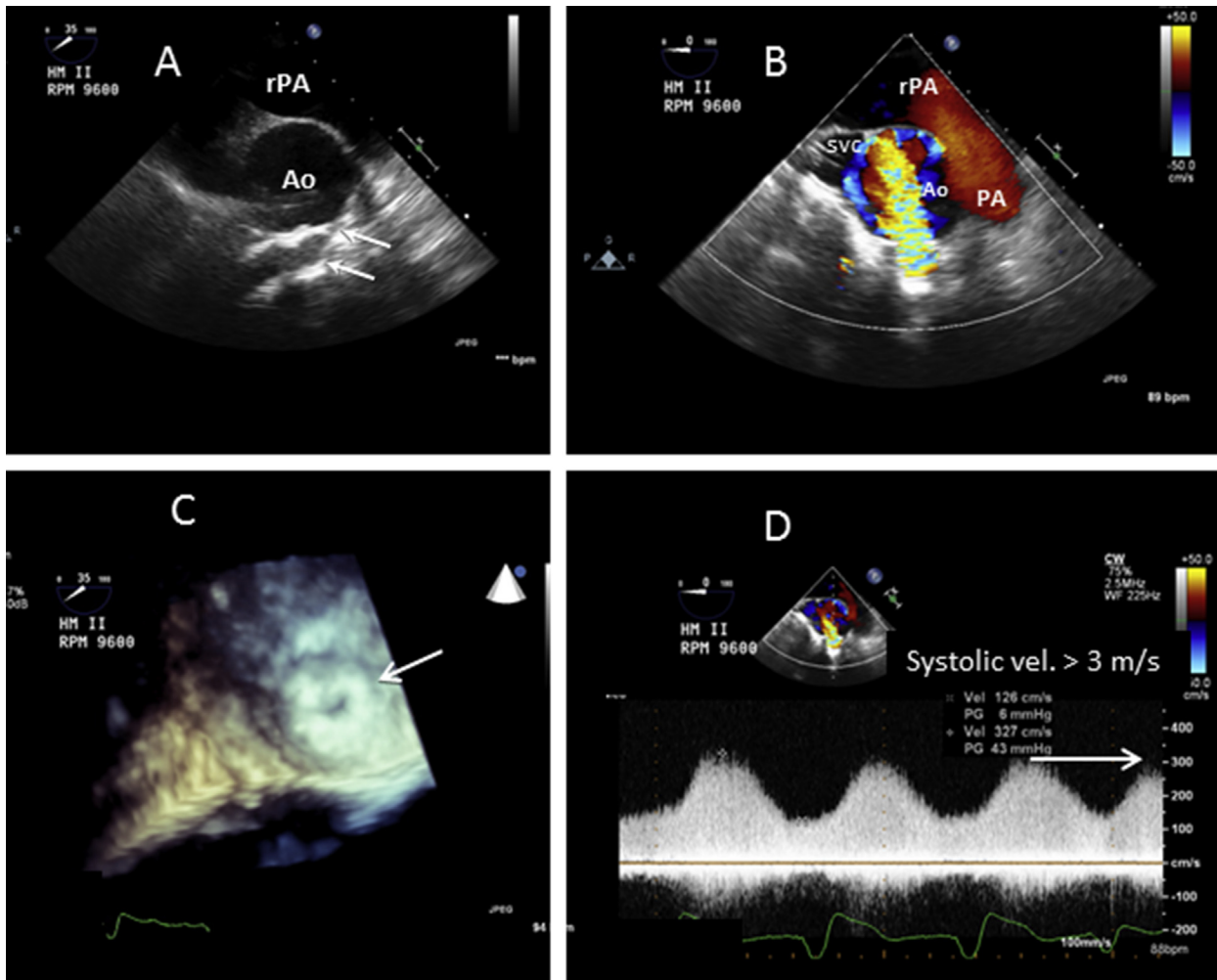


Figure 30 Progressive outflow-graft anastomotic obstruction identified more than 1 year after initiation of LVAD support. Increasing pump speeds were necessary for adequate LVAD flow, which was paradoxically associated with an increased, instead of a decreased, LV diameter at higher pump speeds without evidence of systemic hypertension. Pump alarms had not yet been activated. TEE, upper esophageal ascending aorta short-axis view: **(A)** irregular contour of the distal outflow graft (“kink” and oblique approach) with a small orifice size (arrows). See also [Video 45](#). **(B)** Color-Doppler flow is turbulent/aliased (compared with the normal appearance [[Figs. 6A, 13C, and 13D](#)]). See also [Video 46](#). **(C)** En face 3D view of the anastomosis (arrow) shows a small buttonhole orifice and suggests neointimal hyperplasia (compare with the normal appearance [[Fig. 6D](#)]). **(D)** Continuous-wave Doppler image with a peak systolic velocity of >3 m/s. Note that the outflow-graft anastomosis could not be visualized on TTE.

(reduced LV unloading) include an increased LVIDD, a septal shift towards the right ventricle and (depending on residual ventricular function), increased AV opening in comparison with previous findings, as defined in [Table 4](#). In patients with serologic evidence of possible intravascular hemolysis and/or proven internal pump thrombosis, diastolic inflow-cannula and outflow-graft velocities, as measured by Doppler, are typically decreased in association with increased inflow-cannula or outflow-graft peak systolic-to-diastolic flow-velocity ratios in comparison with those seen during the patient’s baseline (surveillance) exam.⁸⁰ Confirmatory evidence of coexisting pump dysfunction is provided by a subsequent speed-change or “ramp-study” phase of the LVAD problem-focused exam. Obstruction resulting from any cause (eg, internal impeller thrombosis, outflow-graft kinking, etc.) attenuates the expected changes in 2D and inflow-cannula or outflow-graft velocity at varying pump speeds. For example, when the pump speed is increased, the expected decrease in LVIDD, reduction in AV-opening frequency or

AV-opening duration, prolongation in MV deceleration time, and increase in RVOT stroke volume will not occur.^{77,79,80}

Significant AR may also be associated with a high estimated LVAD flow but with normal power. When added to normal mitral inflow, the aortic regurgitant volume can lead to an increased LV preload, which may result in increased native LVOT output and AV opening, with intermittent AR on color Doppler ([Figures 9H,9I](#)). Alternatively, the AR may be continuous if the contractile force is not sufficient to interrupt the regurgitant flow during systole ([Figure 9C](#)). With worsening AR, the LVIDD will progressively increase in comparison with that observed on previous surveillance exams, and there may be ventricular septal bowing towards the right ventricle. Doppler flow across the inflow cannula and outflow graft will be normal or increased due to the aorta–left ventricle–LVAD blind loop. However, the net forward cardiac output downstream from the LVAD-to-aorta anastomosis, as reflected by the RVOT VTI-derived cardiac output, will be reduced,^{70,73} even though flow is markedly increased within the



Figure 31 The Berlin Heart EXCOR VAD has variable pump sizes ranging from 10 to 60 mL. Image reproduced with the permission of Berlin Heart.

LVAD circuit proximal to the outflow graft-to-aorta anastomosis (Figure 13). Mitral regurgitation may also increase due to increased LV volume and filling pressure (Table 4).

Ventricular Recovery and/or Decreased LV Afterload. The combination of increased LVAD flow and *increased power* may also be due to *ventricular recovery* or an *abnormally decreased LV afterload*. Echocardiography can distinguish between these two conditions, *particularly when the data are compared with previous surveillance findings*. Increased LV filling (associated with LV recovery) or a decreased afterload (associated with arteriolar vasodilatation resulting from sepsis or other causes and associated with decreased LV filling) will generally be reflected by *increased flow and increased power*. Ventricular recovery is characterized by serial improvements in LV systolic function (eg, an increased LVEF and a reduced LV size, accompanied by an increased AV-opening duration and improved RVOT and native LVOT cardiac outputs) at baseline and lower pump speeds. Improvement in other manifestations of HF, such as functional MR, pulmonary hypertension, and TR, would be expected. Ventricular recovery can also be associated with decreased LVAD flow due to the fact that a greater portion of the cardiac output is being pumped through the AV by the improved left ventricle. The LV chamber size and MR severity may also decrease in the setting of abnormally reduced peripheral vascular resistance (decreased LV afterload) resulting from sepsis or other causes (eg, pharmacologic agents) without LV recovery. In this circumstance, Doppler interrogation of the LVAD inflow cannula and outflow graft may show increased systolic velocities with apparent improvement in the LVEF. However, the ventricular septum may continuously bow into the left ventricle, whereas LV recovery is associated with a normal ventricular septal orientation. The RVOT VTI-derived cardiac output will be increased in comparison to previous surveillance-exam findings.

LVAD Recovery Echo Exam

A small percentage of patients recover sufficient native LV function to allow LVAD explantation. An LVAD recovery or “weaning” protocol can play a pivotal role in the complex decision-making process regarding suitability for LVAD removal. The LVAD recovery echo exam is not frequently performed outside of MCS centers. However, it may be performed more often in the context of an organized research protocol that may include site-specific variations. As with some other aspects of LVAD management, there are few out-

comes data and little consensus surrounding this potentially important phase of patient care. Although a detailed standard LVAD recovery echo protocol cannot be recommended at this time, Appendix H and the following discussion of basic concepts may be useful for establishing a framework.

The LVAD recovery protocol can be considered when LVAD surveillance echocardiography suggests significant recovery of native LV function.⁷⁰ The initial phase of the LVAD recovery protocol should be the same as for any comprehensive LVAD echo exam performed at the baseline speed setting. Very low LVAD pump speeds are associated with retrograde device flow (Figure 26). After the echo exam at the baseline pump setting, gradual speed reductions are used to identify a pump speed at which there is no forward or reverse pump flow (net neutral flow). During most weaning protocols, spectral Doppler interrogation of the LVAD inflow cannula and of the outflow graft is used to determine the speed at which there is net neutral pump flow. Because of blood flow stasis within the entire LVAD system during this phase of the exam, the LVAD recovery protocol typically includes confirmation of adequate systemic anticoagulation before the exam is started. To test the patient’s native LV functional reserve, an exercise test (such as a 6-minute walking test or other cardiopulmonary test) should be considered at one or more time intervals at the net neutral low pump speed.^{84,85} At the conclusion of the exercise test, LV function parameters, including the LVEF, should again be assessed. Early termination of the test with restoration of the baseline LVAD speed is warranted if the patient becomes symptomatic. See Appendix H for a sample protocol.

LVADs for Pediatric and Adolescent Patients

Pediatric and adolescent patients with advanced HF have fewer MCS options than adults and until recently were treated primarily with ECMO. At this time, there are no approved intracorporeal VADs for small children. Two extracorporeal VADs, the Thoratec PediMag and the Berlin Heart EXCOR (see below), are FDA-approved for temporary and extended MCS, respectively. Currently, reports are very limited concerning the use of echocardiography for evaluating pediatric VADs, partly because so few of these patients are encountered at any one center.⁸⁶ It may be assumed that many of the same concepts of LVAD echocardiographic imaging apply to pediatric and adult patients. Furthermore, larger pediatric and adolescent patients may be candidates for MCS devices approved for use in adults. Specific details

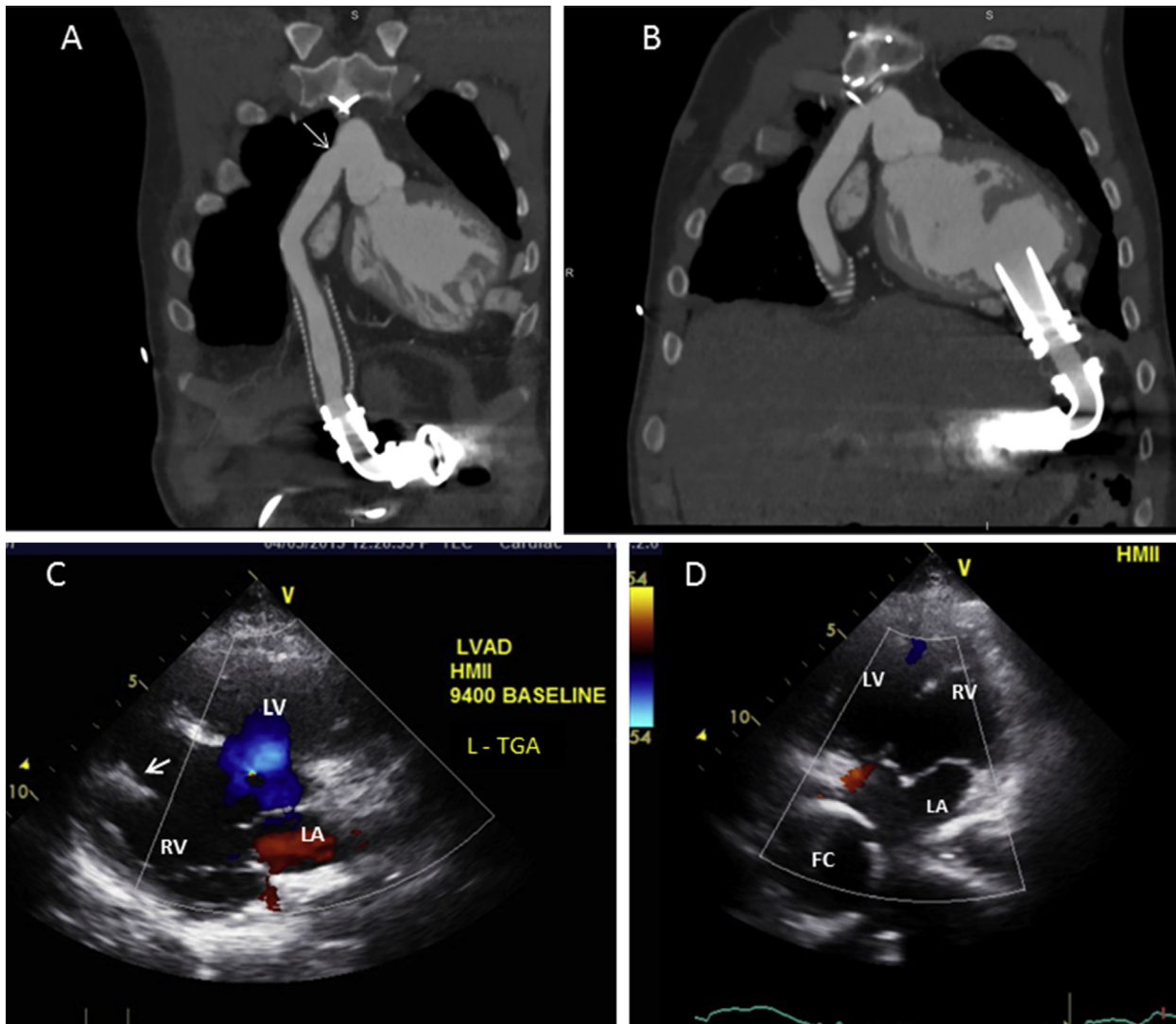


Figure 32 Complementary X-ray CT (**A, B**) and echocardiogram (**C, D**) from a 25-year-old man with single ventricle physiology: L-transposition of the great arteries (L-TGA), complete atrioventricular septal defect (AV canal defect) and subpulmonic stenosis, and a nonfenestrated Fontan conduit (placed at age 5 years). Although he initially received an HM-II LVAD for destination therapy, he eventually underwent cardiac transplantation after 2 years of VAD support (BTT conversion). (**A**) Coronal-plane CT shows a normal outflow graft, including the aortic anastomosis (*arrow*). (**B**) Near-sagittal-plane CT reveals an unobstructed inflow cannula. (**C**) Parasternal long-axis view of a nonrestrictive VSD (*blue color flow*) and inflow cannula (*arrow*) within the morphologic RV. See also [Video 47](#). (**D**) Apical 4-chamber view showing the Fontan conduit (FC). See also [Video 48](#).

concerning VAD suitability based on patient size are beyond the scope of this document. It should be noted that there are no benchmark normal LVAD inflow-cannula or outflow-graft flow velocities for smaller patients. In addition, smaller LV chamber sizes may result in an increased propensity for inflow-cannula obstruction and, in some cases, the need for surgical modification of the MV apparatus.

Short-Term VAD Support for Pediatric Patients. A miniaturized version of the CentriMag VAD (see Figure A-6), the **Thoratec PediMag** extracorporeal centrifugal CF blood pump (previously known as the Levitronix PediMag), is approved for short-term (acute bridge-to-recovery or bridge-to-decision) use as an LVAD, an RVAD, or a BiVAD in small children (FDA 510(k), October 2009). The pump is driven by a bearingless, magnetically levitated impeller and can deliver flows of up to 1.5 L/min. Its echocardiographic features

are expected to be similar to those of the other CF-LVADs previously discussed in this document.

Long-Term VAD Support for Pediatric Patients. The **Berlin Heart EXCOR Pediatric VAD** (Berlin Heart, Inc., The Woodlands, TX) is currently the only VAD approved for BTT therapy in infants and small children. Since this device received FDA approval in 2011, its use has grown significantly.⁸⁷ The EXCOR is an extracorporeal pneumatically driven pulsatile VAD that differs significantly from similarly designed adult devices in that it offers a wide range of graduated cannula and pump chamber sizes (10 to 60 mL) to accommodate the pediatric and adolescent population (Figure 31). In a prospective US multicenter cohort outcomes study of 204 pediatric patients, the 1-year survival rate was 75%: 64% of the patients underwent transplantation, 6% recovered and underwent device

removal, and 5% continued to undergo device support at 1 year.⁸⁷ These results represented a dramatic improvement over previously reported results of conventional management. The echocardiographic features of pulsatile pumps are characterized by inflow and outflow that is not timed with the cardiac cycle (intermittent LV assistance). In “automatic mode” (maximum support) a sensor detects passive chamber filling, which triggers ejection of blood. The device may be set to lower “fixed-rate” settings for lower levels of support. For a discussion of echocardiographic features that differ from those of CF-LVADs, please refer to Estep and coauthors.⁴⁹

KEY POINT

- In many respects, LVAD echocardiography in pediatric and adolescent patients is similar to LVAD echocardiography in adults, but there are important methodological differences; and age-, size-, and device-specific benchmark values have not yet been established.

Other Areas of Research

Current research in echocardiography includes the potential application of many parameters of myocardial function that have not been included in the recommended protocols. Many of the traditional variables used to assess systolic and diastolic function before MCS device implantation are exquisitely preload and afterload dependent, and the ability to extrapolate their usefulness in patients with continuous mechanical LV unloading is limited at this time. Of note, patients with recurrent HF after LVAD implantation may have an increased prevalence of a lower mitral deceleration index (deceleration time/mitral E) and of rightward interatrial-septal deviation suggestive of partial LV unloading. Recently a proposed diagnostic algorithm integrating simple and standard echocardiographic parameters (ie, mitral E/A ratio, RA pressure, systolic pulmonary artery pressure, left atrial volume index, and E/e') reliably distinguished between invasively measured normal and elevated LV filling pressures on baseline levels of LVAD support as evidence of partial LV unloading.⁸⁸ There are, however, no data to suggest that tailoring the pump speed setting to echo-derived diastolic parameters (eg, lowering the mitral inflow E velocity or prolonging the deceleration time by adjusting the pump speed) is associated with symptomatic improvement.

Newer echocardiographically derived mechanical metrics of myocardial function include myocardial displacement, velocity, deformation (strain), strain rate, twist, and dyssynchrony.¹⁹ Mechanical indices may be assessed in longitudinal, circumferential, and radial vectors or as static information using M-mode speckle tracking echocardiography (STE), spectral Doppler, integrated backscatter, or contrast agents. Increasing use of MCS devices provides a fertile ground for further research to test the clinical utility of traditional and emerging functional metrics that may be useful for predicting a patient's clinical trajectory. Because data regarding the clinical use of advanced mechanical metrics are limited or nonexistent at this time, we suggest that the recommended basic protocols provided for routine LVAD management be used as a framework to which more advanced data collection procedures can be added in a methodical site-specific fashion.

KEY POINT

- Increasing clinical use of LVADs provides a fertile ground for testing the clinical utility of traditional and emerging functional metrics in predicting and managing a patient's clinical trajectory.

Indications for Other Imaging Methods After LVAD Implantation

One limitation of echocardiography is its inability to view the entire outflow graft. On the other hand, CCT allows direct, complete visualization of the LVAD, including the inflow-cannula position and the entire course of the outflow graft (Figure 32). This is a robust technique for assessing CF-LVAD complications such as RV compression secondary to pericardial clot, cannula kinking and/or malposition, and thrombus.^{70,89,90} Using intraoperative findings as the gold standard, Raman and associates⁹⁰ demonstrated that the sensitivity and specificity of CCT in detecting cannula thrombosis or inflow-cannula malposition were 85% and 100%, respectively. A limitation of CCT relates to radiation exposure and the risk of nephrotoxicity resulting from an iodinated contrast agent. However, for LVAD patients with a serum creatinine level of <1.5 mg/dL and a glomerular filtration rate of >60 mL/min/1.73 m², CCT appears to be safe.⁹¹ In the presence of nondiagnostic TTE and TEE, indications for CCT in a CF-LVAD patient include (1) clinical concern about inflow-cannula malposition (ie, unexplained frequent LVAD suction events, recurring ventricular dysrhythmias independent of LVAD console parameter deviations, or residual HF due to partial LV unloading), (2) suspected pump thrombosis (involving the inflow and/or outflow graft) with clinical evidence of hemolysis, (3) suspected LVAD malfunction due to outflow-graft kinking, and (4) exclusion of an intracardiac and/or aortic root clot in patients with an unexplained transient ischemic attack or stroke. Echocardiography remains the first-line test to screen for myocardial recovery; however, if poor acoustic windows preclude accurate assessment of ventricular size and function, one may use either multiple-gated acquisition equilibrium radionuclide angiography or electrocardiographically gated CCT as a second-line alternative.^{4,70}

KEY POINT

- Echocardiography may be inconclusive for LVAD complications, including inflow-cannula malposition, pump thrombosis, outflow-graft kinking or obstruction, intra- or extracardiac thrombus, or cardiac compression (low flow) secondary to a pericardial or extrapericardial thoracic hematoma or effusion. In such cases, CCT can provide important complementary information for a more definitive diagnosis.

SUMMARY/DISCUSSION

Echocardiography is important in the management of LVAD patients. Guidance about when and how to perform echocardiography in these patients has previously been lacking. Because the field of MCS is relatively new, many of the recommendations made herein are partly based on consensus expert opinion from several large LVAD centers. In the literature, there is growing support for specific echocardiography parameters that may constitute contraindications or precautions before LVAD surgery. During and after LVAD implantation, one may use perioperative TEE and TTE/TEE, respectively, when needed, to confirm normal versus abnormal device function and to determine whether or not the native heart is responding to LVAD support as expected. For organizing these recommendations, we have used a *phase of care* approach, which includes (1) preoperative assessment, (2) perioperative TEE, (3) postoperative surveillance echocardiography, (4) postoperative problem-focused echocardiography, and (5) recovery protocols.

Patient Populations

The majority of patients who receive LVADs are adults with end-stage dilated cardiomyopathies, and many of our recommendations apply to this group. The role of echocardiography in the management of other, smaller populations is less established. These smaller (but potentially growing) populations include patients with infiltrative cardiomyopathies, pediatric and adolescent patients with dilated cardiomyopathies, and pediatric or adult patients with complex congenital heart disease (Figure 32). Because these smaller, less-studied groups may benefit from LVAD support, they are briefly discussed separately when they are thought to overlap with adult dilated cardiomyopathy patients with regard to patient selection, device type, and functional assessment after implantation. However, these special populations may require considerable individualized consideration with respect to patient and device selection and follow-up evaluation. Currently, published data about these populations are limited, and detailed recommendations are not included in this document. A separate pediatric LVAD discussion is included towards the end of the document.

Frequency and Extent of Echocardiography

The number of LVAD patients living in the outpatient, ambulatory environment has grown considerably over the past several years, and further growth is expected due to increasing patient survival and expansion of implant centers. A primary goal of these recommendations is to provide a framework for managing a busy ambulatory MCS center in an efficient manner. Figure 14 presents a reasonable strategy for organizing routine surveillance echocardiography examinations for patients who are doing well after LVAD implantation. Routine surveillance echocardiography is useful for confirming normal LVAD function and assessing the native cardiac response to LVAD support over time. These exams are analogous to appropriate echocardiograms performed in HF patients without LVADs to evaluate their response to guideline-based medical therapy. Many patients tolerate and even thrive on long-term LVAD support. However, routine follow-up surveillance echo exams are recommended to screen for the development of known LVAD complications that may begin in an occult fashion (before symptoms or device alarms), including (but not limited to) de novo or worsening AR, inappropriate speed settings due to either improvement or deterioration of native heart function, internal pump thrombosis, other conduit obstruction, aortic root thrombus, aortic cusp fusion, and ongoing/smoldering HF in inactive patients. Theoretically, early detection of LVAD complications or early intervention in smoldering persistent HF should improve patient outcomes and reduce hospital readmissions for overt HF or for problems that have activated device alarms. From an abundance of caution, some centers may perform too-frequent and/or too-detailed echocardiographic examinations. In such cases, these guidelines may be useful for establishing the optimal frequency of echocardiography examination, based on individual patient circumstances. These recommendations also may help establish a reasonable timetable for routine follow-up examination of patients who are doing well or who may be able to have an LVAD echo exam in a laboratory closer to their home. When a patient does develop overt signs or symptoms of HF or LVAD malfunction, the guidelines provide a framework for performing problem-focused echocardiography examinations.

Laboratory Resources and Extent of Examination

A frequent concern is whether or not “speed changes” should be incorporated into the LVAD echocardiography exam, as this could be an extremely labor- and time-intensive approach. Additionally, the distinct

echocardiography data elements obtained at each pump speed are not well defined. In general, either a surveillance or a problem-focused exam at the LVAD’s baseline pump speed should be equivalent to a comprehensive HF echocardiogram (not a limited study). Additional LVAD-specific imaging during the baseline exam simply includes (when possible) 2D and Doppler interrogation of the inflow cannula, outflow graft, and aortic anastomosis (using TEE if indicated). Thereafter, a “limited” exam at each pump speed is recommended. The extent of imaging required at each pump speed depends on the suspected problem and should be targeted. In stable, asymptomatic patients with normal LVAD function at baseline, subsequent pump speed data acquisition can proceed quite expediently and may even be optional for surveillance exams, depending on the center’s internal standards. A framework for minimal speed-change parameters is provided in the appendix section and can be adapted for each patient, depending on the situation at hand. Pump speed changes may be performed periodically in asymptomatic patients, as this can be a means of establishing a patient’s own benchmark data, which can be useful for comparison if suspected abnormalities are apparent on subsequent exams. Speed-change/ramp studies can be useful, if not critical, for a problem-focused exam (eg, screening for pump malfunction in the setting of hemolysis and suspected impeller thrombosis) and for the assessment of LV recovery. Special knowledge of contraindications for certain speed adjustments and of safety endpoints for speed changes is required by personnel performing, supervising, and interpreting the studies, and the necessary information is outlined in the text and listed in the tables and appendices.

Patient flow within busy LVAD clinics may be streamlined by advance scheduling of routine surveillance examinations so that the appropriate time, the necessary exam room space, and adequately trained sonographers are available, either within the facility’s dedicated echocardiography laboratory or within a dedicated satellite echocardiography laboratory in the HF/MCS center. When abnormalities are suspected, the type and extent of the examination can be more readily determined if the knowledgeable sonographer and echocardiographer are provided with a detailed indication for examination, as listed in the sample worksheet. In some cases, a limited confirmatory exam may be performed at the baseline pump speed, and a more detailed examination may be more appropriate after hospitalization. A new facet of examining LVAD patients is the need for arterial Doppler-derived BP measurement in many cases before starting the echocardiography exam and for ensuring safety and accurate interpretation when higher pump speed changes are included in the exam. In general, a primary goal of this document is to provide a framework for incorporating echocardiography more efficiently into both the routine follow-up care and the acute care of LVAD patients. In the absence of validation and outcomes studies, considerable room for adaptation of these recommendations is possible according to institutional internal standards and individual patient circumstances. However, the provision of adequately trained personnel, appropriate equipment, and quality-improvement measures is necessary for the implementation of echocardiography in these often complex cases, in which images are sometimes difficult to acquire and interpret.

Referring/Community Hospitals

Although LVAD expertise is required within device implantation and follow-up facilities, an increasing number of ambulatory LVAD patients can be expected to present at less experienced facilities because of either symptoms or device alarm reports. Therefore, an additional goal of this document is to provide an easily understood and available

key reference for non-expert echocardiographers. Ideally, such individuals will be able to quickly grasp key points, develop problem-solving skills, observe safety precautions, and effectively communicate with referral centers when examining unexpected LVAD patients. Potentially, local laboratories may develop the recommended level of sophistication for performing surveillance examinations that can be communicated to the tertiary implant center.

Other Devices

This document primarily addresses two FDA-approved, long-term, surgically implanted CF-LVADs (the HM-II and HVAD). However, echocardiographers may increasingly encounter temporary LVADs, which are briefly discussed in [Appendix A](#) in order to contextualize their use under the heading of MCS.

The Right Ventricle and Biventricular/RVAD Support

Right ventricular support is sometimes required, and outcomes may be improved when RVAD support is provided at the time of initial LVAD implantation. Development of echocardiographic predictors for RV failure after LVAD implantation has been the focus of relatively intensive clinical investigation, as discussed in some detail within this document. Unfortunately, recommendations for a single echocardiography parameter or set of parameters that can reliably predict the need for biventricular support cannot be made at this time. Instead, laboratories are encouraged to evaluate RV function as extensively as they can and to use an aggregate assessment of clinical and echocardiography parameters of RV dysfunction both pre- and postoperatively for clinical decision-making. A detailed discussion of the types of RVAD support that can be observed (when needed) and the use of echocardiography for assisting in the management of biventricular support is beyond the scope of this document, although a brief discussion is included in [Appendix A](#). An important role for echocardiography in patients with the *clinical* appearance of RV failure after LVAD implantation (low LVAD flow) is to exclude other causes, such as occult pericardial or thoracic tamponade.

In conclusion, the Writing Committee and its special contributors hope that this initial document will provide a framework for better incorporating echocardiography into the care of LVAD patients. There are other MCS devices under development that may be included in future versions of this report. We hope that this document will also provide a stimulus for related validation and outcomes studies in this emerging field.

NOTICE AND DISCLAIMER

This report is made available by the ASE as a courtesy reference source for its members. It contains recommendations only and should not be used as the sole basis for making medical practice decisions or for taking disciplinary action against any employee. The statements and recommendations contained in this report are based primarily on the opinions of experts rather than on scientifically verified data. The ASE makes no express or implied warranties regarding the completeness or accuracy of the information in this report, including the warranty of merchantability or fitness for a particular purpose. In no event shall the ASE be liable to you, your patients, or any other third parties for any decision made or action taken by you or such other parties in reliance on this information. Nor does your use of this information constitute the offering of medical advice by the

ASE or create any physician-patient relationship between the ASE and your patients or anyone else.

ACKNOWLEDGEMENTS

The Writing Committee would like to thank Virginia Fairchild, of the Texas Heart Institute's Department of Scientific Publications, for her expert editorial assistance with the preparation of this manuscript. In addition, Dr. Stainback acknowledges Dr. O. H. Frazier for his many years of LVAD clinical correlations.

SUPPLEMENTARY DATA

Supplementary data related to this article can be found at <http://dx.doi.org/10.1016/j.echo.2015.05.008>.

REFERENCES

1. Frazier OH, Rose EA, Macmanus Q, Burton NA, Lefrak EA, Poirier VL, et al. Multicenter clinical evaluation of the HeartMate 1000 IP left ventricular assist device. *Ann Thorac Surg* 1992;53:1080-90.
2. Rose EA, Gelijns AC, Moskowitz AJ, Heitjan DF, Stevenson LW, Dembitsky W, et al. Long-term use of a left ventricular assist device for end-stage heart failure. *N Engl J Med* 2001;345:1435-43.
3. Stewart GC, Givertz MM. Mechanical circulatory support for advanced heart failure: patients and technology in evolution. *Circulation* 2012;125:1304-15.
4. Feldman D, Pamboukian SV, Teuteberg JJ, Birks E, Lietz K, Moore SA, et al. The 2013 International Society for Heart and Lung Transplantation Guidelines for mechanical circulatory support: executive summary. *J Heart Lung Transpl* 2013;32:157-87.
5. Kirklin JK, Naftel DC, Pagani FD, Kormos RL, Stevenson LW, Blume ED, et al. Sixth INTERMACS annual report: a 10,000-patient database. *J Heart Lung Transpl* 2014;33:555-64.
6. Moazami N, Fukamachi K, Kobayashi M, Smedira NG, Hoercher KJ, Massiello A, et al. Axial and centrifugal continuous-flow rotary pumps: a translation from pump mechanics to clinical practice. *J Heart Lung Transpl* 2013;32:1-11.
7. Kar B, Basra SS, Shah NR, Loyalka P. Percutaneous circulatory support in cardiogenic shock: interventional bridge to recovery. *Circulation* 2012;125:1809-17.
8. Pagani FD, Miller LW, Russell SD, Aaronson KD, John R, Boyle AJ, et al. Extended mechanical circulatory support with a continuous-flow rotary left ventricular assist device. *J Am Coll Cardiol* 2009;54:312-21.
9. Slaughter MS, Rogers JG, Milano CA, Russell SD, Conte JV, Feldman D, et al. Advanced heart failure treated with continuous-flow left ventricular assist device. *N Engl J Med* 2009;361:2241-51.
10. Aaronson KD, Slaughter MS, Miller LW, McGee EC, Cotts WG, Acker MA, et al. Use of an intrapericardial, continuous-flow, centrifugal pump in patients awaiting heart transplantation. *Circulation* 2012;125:3191-200.
11. IAC accreditation: getting started. 2014. <http://www.intersocietal.org/iac/accreditation/gettingstarted.htm> Accessed April 10, 2014.
12. Introduction/Steering Committee, Task Force 1: Training in Ambulatory Consultative Longitudinal Cardiovascular Care, Task Force 2: Training in Preventive Cardiovascular Medicine, Task Force 3: Training in Electrocardiography, Ambulatory Electrocardiography, Exercise Testing, Task Force 4: Training in Multimodality Imaging, Task Force 5: Training in Echocardiography, et al. ACC 2015 Core Cardiovascular Training Statement (COCATS 4) (Revision of COCATS 3): A Report of the ACC Competency Management Committee. *J Am Coll Cardiol* 2015;65:1721-3.
13. Gardin JM, Adams DB, Douglas PS, Feigenbaum H, Forst DH, Fraser AG, et al. Recommendations for a standardized report for adult transthoracic

- echocardiography: a report from the American Society of Echocardiography's Nomenclature and Standards Committee and Task Force for a Standardized Echocardiography Report. *J Am Soc Echocardiogr* 2002;15:275-90.
14. Ventricular Assist Devices (VADs) as Destination Therapy (MM7220). Baltimore, MD: Centers for Medicare & Medicaid Services. October 30, <http://www.cms.gov/Outreach-and-Education/Medicare-Learning-Network-MLN/MLNMattersArticles/downloads/MM7220.pdf>; 2010.
 15. Levy WC, Mozaffarian D, Linker DT, Sutradhar SC, Anker SD, Cropp AB, et al. The Seattle Heart Failure Model: prediction of survival in heart failure. *Circulation* 2006;113:1424-33.
 16. Aaronson KD, Schwartz JS, Chen TM, Wong KL, Goin JE, Mancini DM. Development and prospective validation of a clinical index to predict survival in ambulatory patients referred for cardiac transplant evaluation. *Circulation* 1997;95:2660-7.
 17. Lang RM, Badano LP, Mor-Avi V, Afilalo J, Armstrong A, Ernande L, et al. Recommendations for cardiac chamber quantification by echocardiography in adults: an update from the American Society of Echocardiography and the European Association of Cardiovascular Imaging. *J Am Soc Echocardiogr* 2015;28:1-39. e14.
 18. Lang RM, Badano LP, Tsang W, Adams DH, Agricola E, Buck T, et al. EAE/ASE recommendations for image acquisition and display using three-dimensional echocardiography. *J Am Soc Echocardiogr* 2012;25:3-46.
 19. Mor-Avi V, Lang RM, Badano LP, Belohlavek M, Cardim NM, Derumeaux G, et al. Current and evolving echocardiographic techniques for the quantitative evaluation of cardiac mechanics: ASE/EAE consensus statement on methodology and indications endorsed by the Japanese Society of Echocardiography. *J Am Soc Echocardiogr* 2011;24:277-313.
 20. Porter TR, Abdelmoneim S, Belcik JT, McCulloch ML, Mulvagh SL, Olson JJ, et al. Guidelines for the cardiac sonographer in the performance of contrast echocardiography: a focused update from the American Society of Echocardiography. *J Am Soc Echocardiogr* 2014;27:797-810.
 21. Topolsky Y, Oh JK, Shah DK, Boilson BA, Schirger JA, Kushwaha SS, et al. Echocardiographic predictors of adverse outcomes after continuous left ventricular assist device implantation. *JACC Cardiovasc Imaging* 2011;4:211-22.
 22. Rudski LG, Lai WW, Afilalo J, Hua L, Handschumacher MD, Chandrasekaran K, et al. Guidelines for the echocardiographic assessment of the right heart in adults: a report from the American Society of Echocardiography endorsed by the European Association of Echocardiography, a registered branch of the European Society of Cardiology, and the Canadian Society of Echocardiography. *J Am Soc Echocardiogr* 2010;23:685-713. quiz 86-8.
 23. Fitzpatrick JR 3rd, Frederick JR, Hiesinger W, Hsu VM, McCormick RC, Kozin ED, et al. Early planned institution of biventricular mechanical circulatory support results in improved outcomes compared with delayed conversion of a left ventricular assist device to a biventricular assist device. *J Thorac Cardiovasc Surg* 2009;137:971-7.
 24. Kirklin JK, Naftel DC, Kormos RL, Stevenson LW, Pagani FD, Miller MA, et al. Fifth INTERMACS annual report: risk factor analysis from more than 6,000 mechanical circulatory support patients. *J Heart Lung Transplant* 2013;32:141-56.
 25. Matthews JC, Koelling TM, Pagani FD, Aaronson KD. The right ventricular failure risk score a pre-operative tool for assessing the risk of right ventricular failure in left ventricular assist device candidates. *J Am Coll Cardiol* 2008;51:2163-72.
 26. Kormos RL, Teuteberg JJ, Pagani FD, Russell SD, John R, Miller LW, et al. Right ventricular failure in patients with the HeartMate II continuous-flow left ventricular assist device: incidence, risk factors, and effect on outcomes. *J Thorac Cardiovasc Surg* 2010;139:1316-24.
 27. Grant AD, Smedira NG, Starling RC, Marwick TH. Independent and incremental role of quantitative right ventricular evaluation for the prediction of right ventricular failure after left ventricular assist device implantation. *J Am Coll Cardiol* 2012;60:521-8.
 28. Vivo RP, Cordero-Reyes AM, Qamar U, Garikipati S, Trevino AR, Aldeiri M, et al. Increased right-to-left ventricle diameter ratio is a strong predictor of right ventricular failure after left ventricular assist device. *J Heart Lung Transplant* 2013;32:792-9.
 29. Kato TS, Jiang J, Schulze PC, Jorde U, Uriel N, Kitada S, et al. Serial echocardiography using tissue Doppler and speckle tracking imaging to monitor right ventricular failure before and after left ventricular assist device surgery. *JACC Heart Fail* 2013;1:216-22.
 30. Potapov EV, Stepanenko A, Dandel M, Kukucka M, Lehmkühl HB, Weng Y, et al. Tricuspid incompetence and geometry of the right ventricle as predictors of right ventricular function after implantation of a left ventricular assist device. *J Heart Lung Transplant* 2008;27:1275-81.
 31. Raina A, Seetha Rammohan HR, Gertz ZM, Rame JE, Woo YJ, Kirkpatrick JN. Postoperative right ventricular failure after left ventricular assist device placement is predicted by preoperative echocardiographic structural, hemodynamic, and functional parameters. *J Card Fail* 2013;19:16-24.
 32. Zoghbi WA, Enriquez-Sarano M, Foster E, Grayburn PA, Kraft CD, Levine RA, et al. Recommendations for evaluation of the severity of native valvular regurgitation with two-dimensional and Doppler echocardiography. *J Am Soc Echocardiogr* 2003;16:777-802.
 33. Baumgartner H, Hung J, Bermejo J, Chambers JB, Evangelista A, Griffin BP, et al. Echocardiographic assessment of valve stenosis: EAE/ASE recommendations for clinical practice. *J Am Soc Echocardiogr* 2009;22:1-23. quiz 101-2.
 34. Zoghbi WA, Chambers JB, Dumesnil JG, Foster E, Gottdiener JS, Grayburn PA, et al. Recommendations for evaluation of prosthetic valves with echocardiography and doppler ultrasound: a report from the American Society of Echocardiography's Guidelines and Standards Committee and the Task Force on Prosthetic Valves, developed in conjunction with the American College of Cardiology Cardiovascular Imaging Committee, Cardiac Imaging Committee of the American Heart Association, the European Association of Echocardiography, a registered branch of the European Society of Cardiology, the Japanese Society of Echocardiography and the Canadian Society of Echocardiography, endorsed by the American College of Cardiology Foundation, American Heart Association, European Association of Echocardiography, a registered branch of the European Society of Cardiology, the Japanese Society of Echocardiography, and Canadian Society of Echocardiography. *J Am Soc Echocardiogr* 2009;22:975-1014. quiz 82-4.
 35. Park SJ, Liao KK, Segurolo R, Madhu KP, Miller LW. Management of aortic insufficiency in patients with left ventricular assist devices: a simple coaptation stitch method (Park's stitch). *J Thorac Cardiovasc Surg* 2004;127:264-6.
 36. Shah NR, Lam WW, Rodriguez FH 3rd, Ermis PR, Simpson L, Frazier OH, et al. Clinical outcomes after ventricular assist device implantation in adults with complex congenital heart disease. *J Heart Lung Transplant* 2013.
 37. Shapiro GC, Leibowitz DW, Oz MC, Weslow RG, Di Tullio MR, Homma S. Diagnosis of patent foramen ovale with transesophageal echocardiography in a patient supported with a left ventricular assist device. *J Heart Lung Transplant* 1995;14:594-7.
 38. Kilger E, Strom C, Frey L, Felbinger TW, Pichler B, Tichy M, et al. Intermittent atrial level right-to-left shunt with temporary hypoxemia in a patient during support with a left ventricular assist device. *Acta Anaesthesiol Scand* 2000;44:125-7.
 39. Ammar KA, Umland MM, Kramer C, Sulemanjee N, Jan MF, Khandheria BK, et al. The ABCs of left ventricular assist device echocardiography: a systematic approach. *Eur Heart J Cardiovasc Imaging* 2012;13:885-99.
 40. Hiratzka LF, Bakris GL, Beckman JA, Bersin RM, Carr VF, Casey DE Jr, et al. 2010 ACCF/AHA/AATS/ACR/ASA/SCA/SCAI/SIR/STS/SVM Guidelines for the diagnosis and management of patients with thoracic aortic disease. A Report of the American College of Cardiology Foundation/American Heart Association Task Force on Practice Guidelines, American Association for Thoracic Surgery, American College of Radiology, American Stroke Association, Society of Cardiovascular Anesthesiologists, Society for Cardiovascular Angiography and Interventions, Society of Interventional Radiology, Society of Thoracic Surgeons, and Society for Vascular Medicine. *J Am Coll Cardiol* 2010;55:e27-129.

41. American Society of Anesthesiologists and Society of Cardiovascular Anesthesiologists Task Force on Transesophageal Echocardiography. Practice guidelines for perioperative transesophageal echocardiography. An updated report by the American Society of Anesthesiologists and the Society of Cardiovascular Anesthesiologists Task Force on Transesophageal Echocardiography. *Anesthesiology* 2010;112:1084-96.
42. Hahn RT, Abraham T, Adams MS, Bruce CJ, Glas KE, Lang RM, et al. Guidelines for performing a comprehensive transesophageal echocardiographic examination: recommendations from the American Society of Echocardiography and the Society of Cardiovascular Anesthesiologists. *J Am Soc Echocardiogr* 2013;26:921-64.
43. Ryan T, Armstrong WF, Khandheria BK. American Society of E. Task force 4: training in echocardiography endorsed by the American Society of Echocardiography. *J Am Coll Cardiol* 2008;51:361-7.
44. Cahalan MK, Abel M, Goldman M, Pearlman A, Sears-Rogan P, Russell I, et al. American Society of Echocardiography and Society of Cardiovascular Anesthesiologists task force guidelines for training in perioperative echocardiography. *Anesth Analg* 2002;94:1384-8.
45. Cahalan MK, Stewart W, Pearlman A, Goldman M, Sears-Rogan P, Abel M, et al. American Society of Echocardiography and Society of Cardiovascular Anesthesiologists task force guidelines for training in perioperative echocardiography. *J Am Soc Echocardiogr* 2002;15:647-52.
46. Greim CA, Trautner H, Kramer K, Zimmermann P, Apfel CC, Roewer N. The detection of interatrial flow patency in awake and anesthetized patients: a comparative study using transnasal transesophageal echocardiography. *Anesth Analg* 2001;92:1111-6.
47. Gin KG, Huckell VF, Pollick C. Femoral vein delivery of contrast medium enhances transthoracic echocardiographic detection of patent foramen ovale. *J Am Coll Cardiol* 1993;22:1994-2000.
48. Woods TD, Patel A. A critical review of patent foramen ovale detection using saline contrast echocardiography: when bubbles lie. *J Am Soc Echocardiogr* 2006;19:215-22.
49. Estep JD, Stainback RF, Little SH, Torre G, Zoghbi WA. The role of echocardiography and other imaging modalities in patients with left ventricular assist devices. *JACC Cardiovasc Imaging* 2010;3:1049-64.
50. Shah NR, Cevik C, Hernandez A, Gregoric ID, Frazier OH, Stainback RF. Transthoracic echocardiography of the HeartWare left ventricular assist device. *J Card Fail* 2012;18:745-8.
51. Bennett MK, Roberts CA, Dordunoo D, Shah A, Russell SD. Ideal methodology to assess systemic blood pressure in patients with continuous-flow left ventricular assist devices. *J Heart Lung Transplant* 2010;29:593-4.
52. Lanier GM, Orlanes K, Hayashi Y, Murphy J, Flannery M, Te-Frey R, et al. Validity and reliability of a novel slow cuff-deflation system for noninvasive blood pressure monitoring in patients with continuous-flow left ventricular assist device. *Circ Heart Fail* 2013;6:1005-12.
53. HeartWare Ventricular Assist System: Instructions for Use. Miami Lakes, FL: HeartWare, Inc., October 5, 2014, http://www.heartware.com/sites/default/files/uploads/docs/ifu00001_rev_15.pdf; 2012.
54. Markham DW, Drazner MH. Measuring nonpulsatile blood pressure: say goodbye to the Doppler? *Circ Heart Fail* 2013;6:879-80.
55. Topilsky Y, Oh JK, Atchison FW, Shah DK, Bichara VM, Schirger JA, et al. Echocardiographic findings in stable outpatients with properly functioning HeartMate II left ventricular assist devices. *J Am Soc Echocardiogr* 2011;24:157-69.
56. Lam KM, Ennis S, O'Driscoll G, Solis JM, Macgillivray T, Picard MH. Observations from non-invasive measures of right heart hemodynamics in left ventricular assist device patients. *J Am Soc Echocardiogr* 2009;22:1055-62.
57. Garcia-Alvarez A, Fernandez-Friera L, Lau JF, Sawit ST, Mirelis JG, Castillo JG, et al. Evaluation of right ventricular function and postoperative findings using cardiac computed tomography in patients with left ventricular assist devices. *J Heart Lung Transplant* 2011;30:896-903.
58. Sauer AJ, Meehan K, Gordon R, Abicht T, Rich JD, Anderson AS, et al. Echocardiographic markers of left ventricular unloading using a centrifugal-flow rotary pump. *J Heart Lung Transplant* 2014;33:449-50.
59. Schiller NB, Shah PM, Crawford M, DeMaria A, Devereux R, Feigenbaum H, et al. Recommendations for quantitation of the left ventricle by two-dimensional echocardiography. American Society of Echocardiography Committee on Standards, Subcommittee on Quantitation of Two-Dimensional Echocardiograms. *J Am Soc Echocardiogr* 1989;2:358-67.
60. Quinones MA, Waggoner AD, Reduto LA, Nelson JG, Young JB, Winters WL Jr, et al. A new, simplified and accurate method for determining ejection fraction with two-dimensional echocardiography. *Circulation* 1981;64:744-53.
61. Mancini DM, Benjaminovitz A, Levin H, Catanese K, Flannery M, DiTullio M, et al. Low incidence of myocardial recovery after left ventricular assist device implantation in patients with chronic heart failure. *Circulation* 1998;98:2383-9.
62. Nagueh SF, Appleton CP, Gillebert TC, Marino PN, Oh JK, Smiseth OA, et al. Recommendations for the evaluation of left ventricular diastolic function by echocardiography. *J Am Soc Echocardiogr* 2009;22:107-33.
63. Topilsky Y, Hasin T, Oh JK, Borgeson DD, Boilson BA, Schirger JA, et al. Echocardiographic variables after left ventricular assist device implantation associated with adverse outcome. *Circ Cardiovasc Imaging* 2011;4:648-61.
64. Lee S, Kamdar F, Madlon-Kay R, Boyle A, Colvin-Adams M, Pritzker M, et al. Effects of the HeartMate II continuous-flow left ventricular assist device on right ventricular function. *J Heart Lung Transplant* 2010;29:209-15.
65. Raina A, Vaidya A, Gertz ZM, Susan C, Forfia PR. Marked changes in right ventricular contractile pattern after cardiothoracic surgery: implications for post-surgical assessment of right ventricular function. *J Heart Lung Transplant* 2013;32:777-83.
66. Slaughter MS, Pagani FD, Rogers JG, Miller LW, Sun B, Russell SD, et al. Clinical management of continuous-flow left ventricular assist devices in advanced heart failure. *J Heart Lung Transplant* 2010;29:S1-s39.
67. Mudd JO, Cuda JD, Halushka M, Soderlund KA, Conte JV, Russell SD. Fusion of aortic valve commissures in patients supported by a continuous axial flow left ventricular assist device. *J Heart Lung Transplant* 2008;27:1269-74.
68. Cowger J, Pagani FD, Haft JW, Romano MA, Aaronson KD, Kolias TJ. The development of aortic insufficiency in left ventricular assist device-supported patients. *Circ Heart Fail* 2010;3:668-74.
69. Pak SW, Uriel N, Takayama H, Cappelman S, Song R, Colombo PC, et al. Prevalence of de novo aortic insufficiency during long-term support with left ventricular assist devices. *J Heart Lung Transplant* 2010;29:1172-6.
70. Estep JD, Chang SM, Bhimaraj A, Torre-Amione G, Zoghbi WA, Nagueh SF. Imaging for ventricular function and myocardial recovery on nonpulsatile ventricular assist devices. *Circulation* 2012;125:2265-77.
71. Hatano M, Kinugawa K, Shiga T, Kato N, Endo M, Hisagi M, et al. Less frequent opening of the aortic valve and a continuous flow pump are risk factors for postoperative onset of aortic insufficiency in patients with a left ventricular assist device. *Circ J* 2011;75:1147-55.
72. Toda K, Fujita T, Domae K, Shimahara Y, Kobayashi J, Nakatani T. Late aortic insufficiency related to poor prognosis during left ventricular assist device support. *Ann Thorac Surg* 2011;92:929-34.
73. Jorde UP, Uriel N, Nahumi N, Bejar D, Gonzalez-Costello J, Thomas SS, et al. Prevalence, significance, and management of aortic insufficiency in continuous flow left ventricular assist device recipients. *Circ Heart Fail* 2014;7:310-9.
74. Aggarwal A, Raghuvir R, Eryazici P, Macaluso G, Sharma P, Blair C, et al. The development of aortic insufficiency in continuous-flow left ventricular assist device-supported patients. *Ann Thorac Surg* 2013;95:493-8.
75. Horton SC, Khodaverdian R, Chatelain P, McIntosh ML, Horne BD, Muhlestein JB, et al. Left ventricular assist device malfunction: an approach to diagnosis by echocardiography. *J Am Coll Cardiol* 2005;45:1435-40.
76. Schwarz KQ, Parikh SS, Chen X, Farrar DJ, Steinmetz S, Ramamurthi S, et al. Non-invasive flow measurement of a rotary pump ventricular assist device using quantitative contrast echocardiography. *J Am Soc Echocardiogr* 2010;23:324-9.
77. Uriel N, Morrison KA, Garan AR, Kato TS, Yuzefpolskaya M, Latif F, et al. Development of a novel echocardiography ramp test for speed optimization and diagnosis of device thrombosis in continuous-flow left ventricular assist devices: the Columbia ramp study. *J Am Coll Cardiol* 2012;60:1764-75.

78. HeartMate II LVAS: Clinical Operation & Patient Management. Pleasanton, CA: Thoratec Corporation. October 5, 2014, http://www.thoratec.com/_assets/download-tracker/HM_II_Clin_Op_&_Pt_Mgt_104185B_ENGLISH.pdf; 2011.
79. Estep JD, Vivo RP, Cordero-Reyes AM, Bhimaraj A, Trachtenberg BH, Torre-Amione G, et al. A simplified echocardiographic technique for detecting continuous-flow left ventricular assist device malfunction due to pump thrombosis. *J Heart Lung Transplant* 2014;33:575-86.
80. Fine NM, Topilsky Y, Oh JK, Hasin T, Kushwaha SS, Daly RC, et al. Role of echocardiography in patients with intravascular hemolysis due to suspected continuous-flow LVAD thrombosis. *JACC Cardiovasc Imaging* 2013;6:1129-40.
81. Lund LH, Gabrielsen A, Tiren L, Hallberg A, El Karlsson K, Eriksson MJ. Derived and displayed power consumption, flow, and pulsatility over a range of HeartMate II left ventricular assist device settings. *ASAIO J* 2012;58:183-90.
82. Cowger JA, Romano MA, Shah P, Shah N, Mehta V, Haft JW, et al. Hemolysis: a harbinger of adverse outcome after left ventricular assist device implant. *J Heart Lung Transplant* 2014;33:35-43.
83. Shah P, Mehta VM, Cowger JA, Aaronson KD, Pagani FD. Diagnosis of hemolysis and device thrombosis with lactate dehydrogenase during left ventricular assist device support. *J Heart Lung Transplant* 2014;33:102-4.
84. George RS, Sabharwal NK, Webb C, Yacoub MH, Bowles CT, Hedger M, et al. Echocardiographic assessment of flow across continuous-flow ventricular assist devices at low speeds. *J Heart Lung Transplant* 2010;29:1245-52.
85. George RS, Yacoub MH, Tasca G, Webb C, Bowles CT, Tansley P, et al. Hemodynamic and echocardiographic responses to acute interruption of left ventricular assist device support: relevance to assessment of myocardial recovery. *J Heart Lung Transplant* 2007;26:967-73.
86. Sachdeva R, Frazier EA, Jaquiss RD, Imamura M, Swearingen CJ, Vyas HV. Echocardiographic evaluation of ventricular assist devices in pediatric patients. *J Am Soc Echocardiogr* 2013;26:41-9.
87. Almond CS, Morales DL, Blackstone EH, Turrentine MW, Imamura M, Massicotte MP, et al. Berlin Heart EXCOR pediatric ventricular assist device for bridge to heart transplantation in US children. *Circulation* 2013;127:1702-11.
88. Estep JD, Vivo RP, Krim SR, Cordero-Reyes AM, Elias B, Loebe M, et al. Echocardiographic evaluation of hemodynamics in patients with systolic heart failure supported by a continuous-flow LVAD. *J Am Coll Cardiol* 2014;64:1231-41.
89. Acharya D, Singh S, Tallaj JA, Holman WL, George JF, Kirklin JK, et al. Use of gated cardiac computed tomography angiography in the assessment of left ventricular assist device dysfunction. *ASAIO J* 2011;57:32-7.
90. Raman SV, Sahu A, Merchant AZ, Louis LB, Firstenberg MS, Sun B. Noninvasive assessment of left ventricular assist devices with cardiovascular computed tomography and impact on management. *J Heart Lung Transplant* 2010;29:79-85.
91. Chang SM, Kassi M, Sharifeh TMA, Wang H, Elias BA, Bhimaraj A, et al. Diagnostic utility and safety of contrast enhanced gated multislices cardiac computed tomography (CT) for evaluation of patients with left ventricular assist device (LVAD). *Circulation* 2012;126:A18981.
92. Levine GN, Bates ER, Blankenship JC, Bailey SR, Bittl JA, Cercek B, et al. 2011 ACCF/AHA/SCAI Guideline for Percutaneous Coronary Intervention. A report of the American College of Cardiology Foundation/American Heart Association Task Force on Practice Guidelines and the Society for Cardiovascular Angiography and Interventions. *J Am Coll Cardiol* 2011;58:e44-122.
93. Impella 2.5 with the Impella Console: Instructions for Use & Clinical Reference Manual. Document No. 0046-9005, Rev D. Danvers, Massachusetts: ABIOMED, Inc.; 2011. March 17, 2014.

APPENDIX A**Other FDA-Approved Pumps that may be Encountered by Sonographers and Echocardiographers, Including Percutaneous, Extracorporeal, and Right Ventricular Assist Devices****Percutaneous LVADs for Temporary Support**

A percutaneous LVAD (PVAD) can be expediently deployed in the cath lab with the aid of fluoroscopic guidance, either urgently to treat cardiogenic shock or preemptively to provide back-up support during certain high-risk percutaneous coronary interventions.⁹² Currently, two types of FDA-approved PVADs are available: the *Impella System* (Abiomed, Inc., Danvers, MA) and the *TandemHeart System* (CardiacAssist, Inc., Pittsburgh, PA).

Impella. The Impella 2.5 (FDA 510(k), 2008) and the slightly larger (up to 4 L/min) Impella CP (Cardiac Power) (FDA 510(k), 2012) are implanted via a traditional femoral arterial approach. The larger Impella 5.0 (FDA 510(k), 2009) delivers flows of up to 5 L/min and requires surgical placement via a left axillary artery graft. The role of echocardiography and the echocardiographic appearance is the same for all three device sizes. The distal portion of the Impella system consists of a microaxial CF pump housed within a cannula that draws blood into an LV inflow port and expels the blood through an aortic root outlet port (intracardiac blood flow circuit) (Figure A1).

Echocardiography Before Deployment.—Significant AR is a relative contraindication, and ventricular thrombus and severe AS or MS are contraindications for use of the Impella. Echocardiography may be used to screen for these conditions and otherwise to confirm the extent and etiology of HF.

Echocardiography After Deployment.—Device console alarms or hemodynamic instability may prompt an urgent or “stat” echo exam to determine the source of the problem. Patient movement (eg, bed transfer, resuscitation, etc.) can cause catheter migration. The Impella is ideally imaged in its entirety in LVOT long-axis views by TTE or TEE. The visible inflow port should be positioned 3.5 to 4.0 cm from the aortic annulus. The pump’s characteristic color-flow artifact should lie distal to the annulus. The cannula has a 45-degree angle to better track the normal LVOT course. However, this design can also predispose to entanglement of the distal pigtail portion of the device within the submitral apparatus (Figure A2). This complication may result in worse MR, inability to properly advance the device within the left ventricle and/or “low flow” alarms if the adjacent MV leaflets obstruct the inflow zone. As with other LVADs, the AV may be closed or only partially open after device deployment, and net forward flow can be determined by calculating the RVOT stroke volume and cardiac output with Doppler methods. Additional instructive information regarding echocardiography of the Impella systems is available online.⁹³

TandemHeart. The TandemHeart PVAD (FDA 510(k), 2006) is inserted via a femoral vein and requires an atrial transseptal puncture to access the left atrium. The extracorporeal centrifugal pump receives left atrial blood and delivers it to the femoral artery (via an extracardiac blood flow circuit), providing up to 4 or 5 L/min of flow depending on the size of the transseptal inflow cannula (Figure A3).

Echocardiography Before Deployment.—Left atrial thrombus is a potential contraindication for TandemHeart deployment. This device may be useful for cardiogenic shock—including severe postinfarction

VSD, severe MR, or severe AS—or in patients for whom the more easily deployed Impella device is contraindicated (eg, by severe AR or LV thrombus). Echocardiography may be used to screen for these conditions and to otherwise confirm the severity and etiology of HF before device deployment.

Echocardiography After Deployment.—The only visible device component is the transseptal cannula, which may be seen throughout its course from the left atrium, interatrial septum, right atrium, and inferior vena cava, using standard echo views. Color Doppler evaluation can confirm the presence of CF. In addition to verifying the cannula position, the post-deployment echo exam is useful for assessing the native heart’s response to circulatory support and the ability to withdraw temporary LVAD support. The net forward flow can be calculated from the RVOT stroke volume by Doppler methods. The transseptal cannula often enters the left atrial appendage. Because the cannula has 14 side holes, normal flow will occur even if the catheter tip abuts the wall of the left atrium or left atrial appendage (Figure A3C). Because the left ventricle may be completely bypassed, the sonographer should be alert for possible LV thrombus formation (Figure A4) and for aortic root thrombus when the AV remains closed.

Surgically Implanted Extracorporeal Ventricular Assist Devices for Temporary Support

Thoratec Paracorporeal Ventricular Assist Device (VAD). The Thoratec Paracorporeal VAD (Thoratec Corporation, Pleasanton, CA) is a first-generation, pneumatically driven, pulsatile displacement pump with FDA 510(c) approval for BTT therapy (1995) and postcardiotomy recovery (1998). As shown in Figure A5, three potential VAD configurations may be used for LVAD or BiVAD support. The inflow cannula may be implanted within the left atrium, and this approach may be useful for emergent surgical implantation by surgeons not experienced with the more challenging procedure of off-pump LV cannulation. Although the device was also configured for intracorporeal support, this role has been supplanted by the third-generation CF-LVADs. The echocardiographic features of pulsatile pumps are characterized by inflow and outflow that is not timed with the cardiac cycle (intermittent LV assist). In “automatic mode” (maximum support), a sensor detects passive chamber filling, which triggers ejection of blood. The device may be set to lower “fixed-rate” settings for lower levels of support. For a discussion of echocardiographic features that differ from those of CF-LVADs, please refer to Estep and coauthors.⁴⁹

Thoratec CentriMag (previously Levitronix CentriMag). The CentriMag is approved for short-term LVAD, RVAD, or BiVAD support. The extracorporeal centrifugal CF pump (Figure A6) is driven by a bearingless, magnetically levitated impeller that can provide flows of up to 9.9 L/min. The inflow cannula and outflow graft are placed surgically, usually via a midline sternotomy. The CentriMag is suitable for transporting patients between facilities. Difficulties encountered by sonographers include possible suboptimal imaging windows related to lack of sternal wiring (closure) and to patient intubation. When used for LVAD support, the inflow cannula may be placed in either the right superior pulmonary vein (which may not be visible on echo) or in the left ventricle (which is visible on echo). When the inflow cannula is placed in the right superior pulmonary vein, the left ventricle may be completely “bypassed” if the AV does not open. As noted with the TandemHeart device (above), LV blood stasis (Figure A4) increases the risk of LV thrombus formation, which

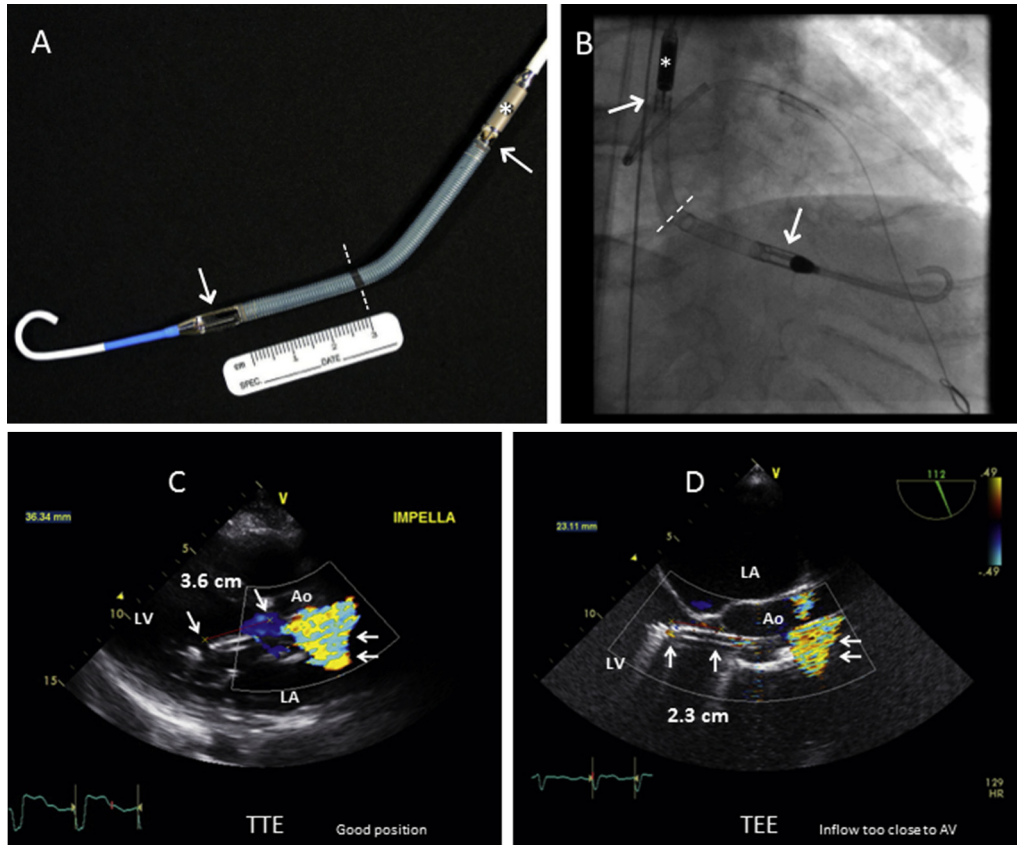


Figure A1 (A) Photograph of the Impella CP Percutaneous LVAD, showing the pump impeller housing (*), blood-inflow zone (*downward arrow*) and blood-outflow zone (*upward arrow*) zones, with the distal pigtail catheter component. (B) Fluoroscopic X-ray image of the Impella CP device in situ. Blood-inflow zone (*downward arrow*), blood-outflow zone (*upward arrow*), impeller housing (*). The radiopaque marker (*immediately below dotted line*) indicates the desired aortic annulus level, which is 3.5 cm from the middle of the inflow zone. (C) TTE parasternal long-axis view. The Impella device crosses the AV. The distance from the blood inflow area (*left single arrow*) to the aortic annulus (*right single arrow*) is approximately 3.6 cm. (D) On TEE, the distance from the inflow area (*left single arrow*) to the aortic annulus (*right single arrow*) is 2.3 cm; this is not far enough into the left ventricle to provide a safety margin, although the device is functioning normally). In views C and D, the double arrows indicate a typical pump-impeller aliased color-Doppler artifact. See also [Videos 49](#) and [50](#).

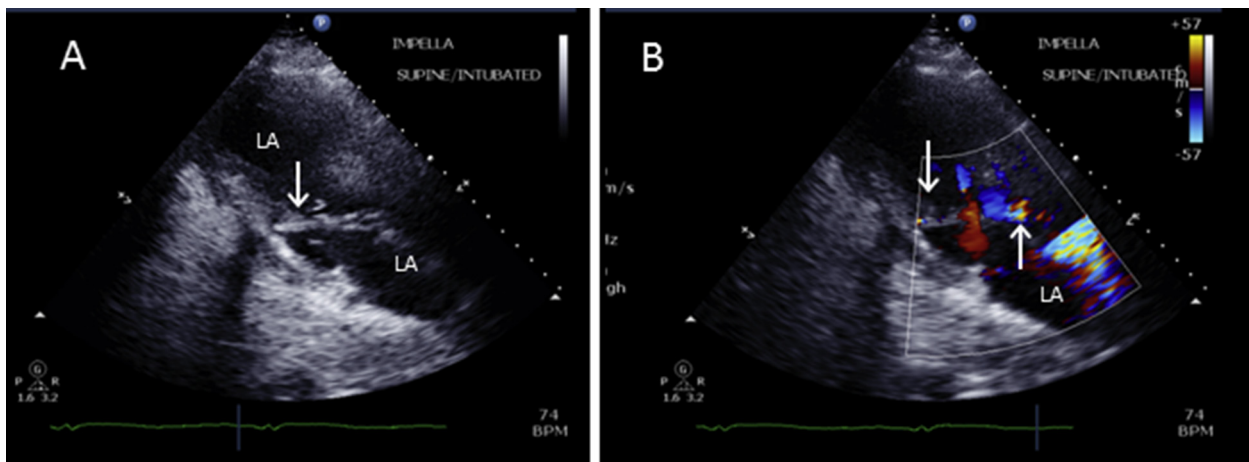


Figure A2 The Impella CP Percutaneous LVAD (A,B), modified TTE parasternal long-axis view, showing the distal pigtail lodged in the submitral apparatus (*downward arrow*) with the inflow zone (cage) adjacent to the MV anterior leaflet and too close to the aortic annulus (*upward arrow*, view B).

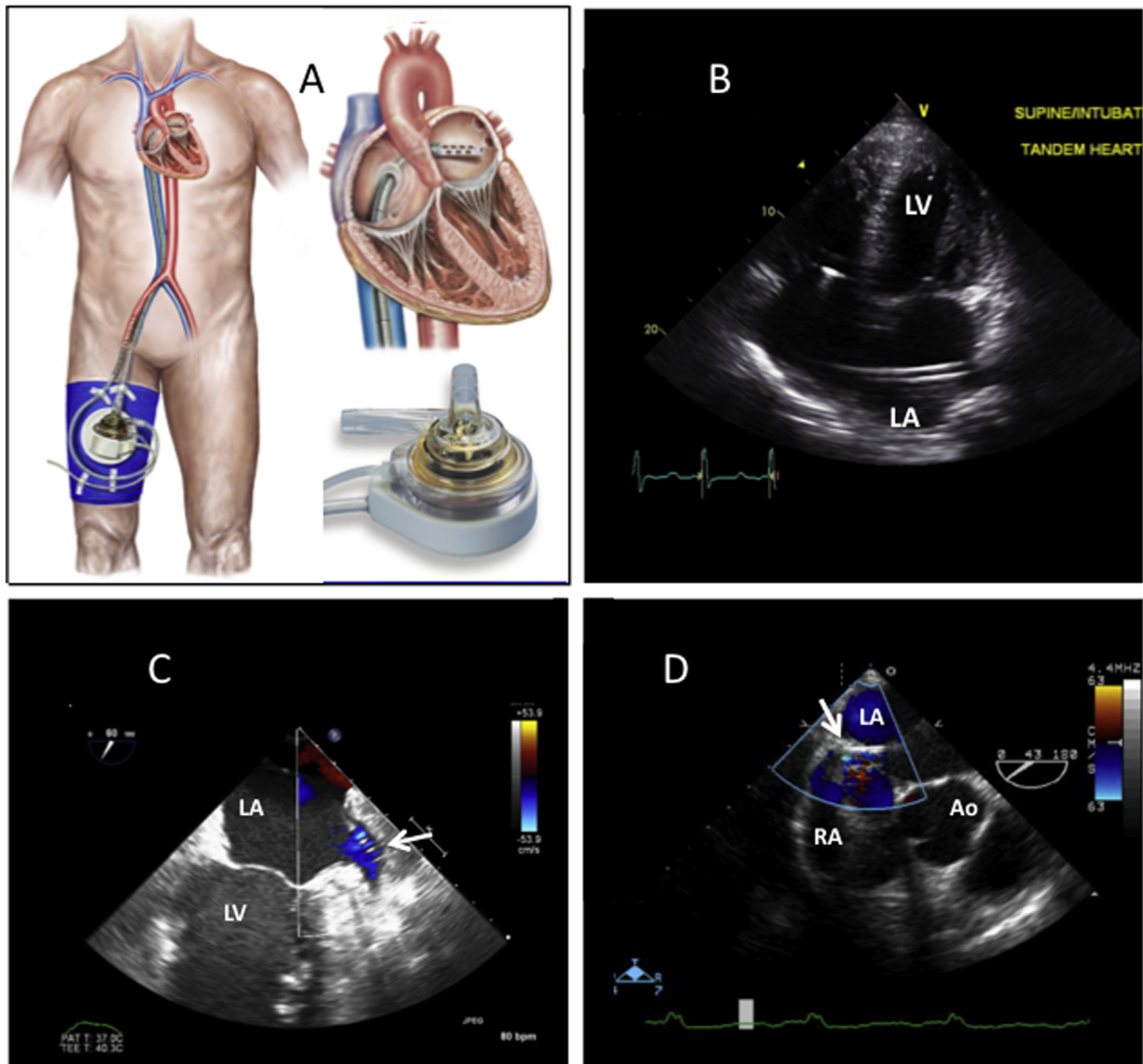


Figure A3 (A) Illustration of the TandemHeart PVAD (Images courtesy of CardiacAssist, Inc.). The CF pump is extracorporeal (*outside the body*). (B) TTE apical 4-chamber view shows the device's inflow conduit within the left atrium. See also [Video 51](#). (C) TEE shows the distal cannula's multiple-port inflow zone within the left atrial appendage (*arrow*). See also [Video 52](#). (D) TEE shows the transatrial septal portion of the inflow conduit (*arrow*). See also [Video 53](#).

can be identified echocardiographically. In other respects, the device's imaging characteristics are similar to those of long-term intracorporeal devices, as previously discussed in detail.

Right Ventricular Assist Devices

As previously noted, the primary population addressed in this guideline consists of patients undergoing LVAD support alone. A brief description of RVADs is included, as echocardiographers may encounter patients with RVAD (BiVAD) support. In the acute setting, including the period after LVAD implantation, an RVAD may be needed. Right ventricular failure is difficult to manage long-term. The ability to predict the development of RV failure prospectively after LVAD implantation is limited, and in some cases right-sided failure

can develop even if preimplantation RV function was seemingly adequate. When optimization of LVAD function and medical management have failed, the Impella, TandemHeart, HM-II, and HVAD pumps have been used as RVADs (without FDA approval), and the Thoratec PVAD, Berlin Heart EXCOR, CentriMag, and PediMag have been used as RVADs with FDA approval. Other, less frequently used devices may also be available, and new systems are on the horizon. When an RVAD and LVAD are functioning simultaneously, many caveats are involved that are beyond the scope of this document. However, an important point is to observe both the RV and LV size, as both under-filling and over-pumping of either chamber may occur, potentially compromising device inflow or mechanically distorting the adjacent ventricle. Balance between the interventricular septum and interatrial septum is important.

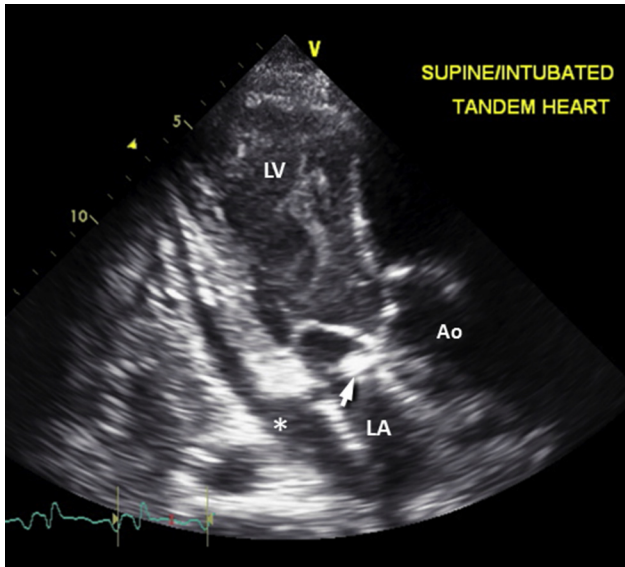


Figure A4 Severe left ventricle (LV) spontaneous echocardiography contrast in a patient with complete LV “bypass” (no aortic valve opening) during TandemHeart support. The risk of LV thrombus is high without systemic anticoagulation therapy. Left Atrium (LA), Aortic Root (Ao), pericardial effusion (*), TandemHeart inflow cannula (arrow). See also [Video 54](#).

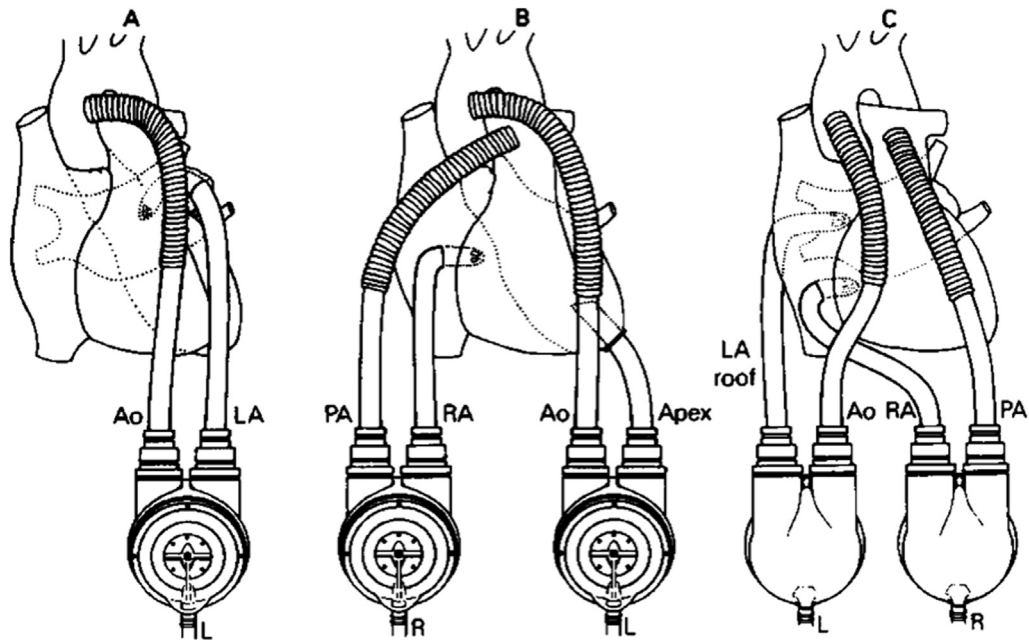


Figure A5 Drawing of the Thoratec Paracorporeal Ventricular Assist Device (VAD) and three cannulation approaches for univentricular left heart support (panel **A**) and biventricular support (panels **B** and **C**). Ao=aorta, LA=left atrial appendage, PA=pulmonary artery, RA=right atrium, Apex=left ventricular apex, IAG=cannula inserted via the interatrial groove and directed towards the LA roof. Note that VADs in Panel **C** are turned over and are on the sides of the chest that are opposite of those in Panel **B**. (Permission from Farrar DJ et al. *N Engl J Med* 1988; 318:333-340).




Figure A6 The Thoratec CentriMag extracorporeal centrifugal CF pump. The arrows indicate the blood-flow direction.

Appendix B Recommended Pre-LVAD-Implantation TTE Protocol (with embedded red flags)

Parasternal Long-Axis View Image acquisition

LV size
Red-flag findings: Small LV size, particularly with increased LV trabeculations
Global and regional LV function
M-mode evaluation of left ventricle and left atrium/aorta (if lab standard)
2D evaluation of AV, MV, TV (TV by RV inflow tract view)
Red-flag finding: any prosthetic valve
Color-flow Doppler evaluation of MV and AV
RV inflow view
CW Doppler (TR)
High left parasternal view of ascending aorta
Red-flag findings: Ascending aortic aneurysm, dissection, or atheroma

Recommended measurements

LV internal dimension at end-diastole
LV internal dimension at end-systole
Posterior wall thickness
Interventricular septal thickness
LV ejection fraction
LVOT diameter
LA dimension
Aortic root dimension
Ascending aorta dimension
CW Doppler TR velocity for RVSP

Parasternal Short-Axis View Image acquisition

2D short-axis view at AV level and RVOT
2D short-axis view of left ventricle at basal, mid, and apical levels
Red-flag findings: VSD
Global and regional LV function
Color-flow Doppler evaluation of PV, AV, and TV
Spectral Doppler evaluation of RVOT, PV, pulmonary trunk
Red-flag findings: Moderate or greater PS or PR; PDA, prosthetic valve
M-mode evaluation (if lab standard)

Recommended measurements

RVOT velocity
PV velocity

Apical Four-Chamber View Image acquisition

2D imaging of the four chambers (maximizing LV length)
Red-flag findings: LV thrombus, LV apical aneurysm, any congenital heart disease
“Dedicated RV view”
Red-flag findings: RV dilatation
Global and regional LV and RV function
Red-flag findings: RV systolic dysfunction
Color-flow Doppler of valvular inflow and regurgitation
Color-flow Doppler interrogation of interventricular and interatrial septum
Red-flag findings: VSD, PFO, or ASD
Pulsed Doppler of MV
Pulsed Doppler of pulmonary veins
Doppler tissue imaging
LV and RV strain (optional)

(Continued)

Appendix B (Continued)

CW Doppler to evaluate valves, native or prosthetic (use multiple views to obtain highest flow velocities)

Red-flag findings:

MV: \geq moderate MS
AV: $>$ mild AR
TV: \geq moderate TR or $>$ mild TS
PV: \geq moderate PS or PR

Agitated saline contrast at rest and with release of Valsalva maneuver to evaluate intracardiac or intrapulmonary shunting

Red-flag findings: PFO, significant intrapulmonary shunt

Recommended measurements

LV systolic function: 2D/3D volumetrics for EF
LV diastolic function: mitral E/A, DT, medial and lateral MV annulus DTI
RV function: RV strain, TAPSE, TV DTI
LA volume index/RA area

Apical Five-Chamber View Image acquisition

2D imaging
Color-flow Doppler of LVOT
Pulsed Doppler of LVOT
CW Doppler of AV if aortic stenosis is present or suspected

Recommended measurements

LV systolic function: LVOT stroke volume, cardiac output/index

Apical Two-Chamber View Image acquisition

2D imaging
Red-flag findings: LA appendage thrombus
Global and regional LV function
Color-flow Doppler of MV

Recommended measurements

LA volume

Apical Long-Axis View Image acquisition

2D imaging
Global and regional LV function
Color-flow Doppler of MV and AV
Pulsed Doppler of LVOT
CW Doppler of AV if aortic stenosis is present or suspected

Recommended measurements

LV systolic function: LVOT stroke volume, cardiac output/index

Subcostal Views Four-chamber

2D imaging, including assessment of interatrial septum
Red-flag findings: VSD, PFO, or ASD
Color-flow Doppler of valvular inflow and for regurgitation
Color-flow Doppler of interventricular and interatrial septum to assess for shunt

Short-axis

Complementary to parasternal views
IVC assessment to estimate RA pressure (IVC size and response to inspiration)
Doppler of hepatic veins, when appropriate

Suprasternal Notch View

Long-axis view of aortic arch (short-axis view if indicated)
Color-flow Doppler of aortic arch and isthmus
Red-flag findings: aortic pathology (PDA, coarctation)
Pulsed Doppler in descending aorta in cases of aortic regurgitation

(Continued)

Appendix B (Continued)

CW Doppler of AV if aortic stenosis is present or suspected
SVC

Other Views**Right parasternal window**

Long-axis view to evaluate ascending aorta
CW Doppler of aortic valve if aortic stenosis is present or suspected

Right supraclavicular window

SVC
CW Doppler of aortic valve if aortic stenosis is present or suspected

2D, two-dimensional; *3D*, three-dimensional; *A*, mitral valve late peak diastolic velocity; *ASD*, atrial septal defect; *AV*, aortic valve; *CW*, continuous-wave; *DT*, deceleration time; *DTI*, Doppler tissue imaging; *E*, mitral valve early peak diastolic velocity; *EF*, ejection fraction; *IVC*, inferior vena cava; *LA*, left atrial; *LV*, left ventricular; *LVOT*, left ventricular outflow tract; *MV*, mitral valve; *PDA*, patent ductus arteriosus; *PFO*, patent foramen ovale; *PR*, pulmonary regurgitation; *PS*, pulmonary stenosis; *PV*, pulmonary valve; *RA*, right atrial; *RV*, right ventricular; *RVOT*, right ventricular outflow tract; *RVSP*, right ventricular systolic pressure; *SVC*, superior vena cava; *TAPSE*, tricuspid annular-plane systolic excursion; *TR*, tricuspid regurgitation; *TS*, tricuspid stenosis; *TTE*, transthoracic echocardiography; *TV*, tricuspid valve; *VSD*, ventricular septal defect.

Appendix C Perioperative TEE Protocol/Checklist

Two-part exam. For standard views, see previous guidelines Hahn, et al.⁴²

1. Preimplantation Perioperative TEE Exam

Goals: confirm previous echocardiography (TTE or TEE) findings; detect unexpected abnormal findings before and after LVAD implantation

Blood pressure: via arterial line; for hypotension, consider vasopressor agent to assess AR severity

LV: size, systolic function, assess for thrombus

LA: size, assess for LA appendage/LA thrombus

RV: size, systolic function, catheters/leads

RA: size, assess for thrombus, catheters/leads

Interatrial septum: detailed 2D, color Doppler, IV saline contrast; **red flag:** PFO/ASD

Systemic veins: assess SVC, IVC

Pulmonary veins

Aortic valve: **red flags:** > mild AR, prosthetic valve

Mitral valve: **red flags:** \geq moderate mitral stenosis, prosthetic mitral valve

Pulmonary valve: **red flags:** > mild PS, \geq moderate PR, if RVAD planned; prosthetic valve

Pulmonary trunk: **red flags:** congenital anomaly (PDA, pulmonary atresia or aneurysm)

Tricuspid valve: TR, systolic PA pressure by TR velocity; **red flags:** \geq moderate TR, > mild TS, prosthetic valve

Pericardium: screen for effusion; consider constrictive physiology

Aorta: root, ascending, transverse, and descending thoracic aorta; screen for aneurysm, congenital anomaly, dissection, or complex atheroma at each level

2. Postimplantation Perioperative TEE Exam

Goals: monitor for intracardiac air; rule out shunt; confirm device and native heart function

Pump type:

Pump speed:

Blood pressure: via arterial line; for hypotension (MAP of <60 mmHg), consider vasopressor agent before assessing AR severity and other hemodynamic variables

Intracardiac air: left-sided chambers and aortic root during removal from CPB

LV: size, inflow-cannula position and flow velocities, septal position; **red flags:** small LV (over-pumping or RV failure), right-to-left septal shift; large LV (obstructed or inadequate pump flows)

Inflow-cannula position: 2D/3D, assess for possible malposition

Inflow-cannula flow: spectral and color Doppler (**red flag:** abnormal flow pattern/high/low velocities, especially after sternal closure)

LA: Assess LA appendage

RV: size, systolic function; **red flags:** signs of RV dysfunction

RA: size, assess for thrombus, catheters/leads

Interatrial septum: repeat IV saline test and color Doppler evaluation of IAS (**red flags:** PFO/ASD)

Systemic veins: (SVC, IVC)

Pulmonary veins: inspect

Aortic valve: degree of AV opening and degree of AR (**red flags:** > mild AR)

Mitral valve: exclude inflow-cannula interference with submitral apparatus; assess MR

Pulmonary valve: assess PR, measure RVOT SV if able

Pulmonary trunk: (if applicable, demonstrate RVAD outflow by color Doppler); assess PR

Tricuspid valve: assess TR (**red flags:** \geq moderate TR); systolic PA pressure by TR velocity (if not severe TR)

Pericardium: screen for effusion/hematoma

Aorta: exclude iatrogenic dissection

Outflow graft: identify conduit path adjacent to RV/RA with color and spectral Doppler (when able)

Outflow graft-to-aorta anastomosis: assess patency/flow by color and spectral Doppler (when able) **red flags:** kinked appearance/turbulent flow/velocity >2 m/sec, particularly after sternal closure

2D, Two-dimensional; 3D, three-dimensional; AR, aortic regurgitation; ASD, atrial septal defect; AV, aortic valve; CPB, cardiopulmonary bypass; IAS, interatrial septum; IV, intravenous; IVC, inferior vena cava; LA, left atrium; LV, left ventricle; LVAD, left ventricular assist device; LVOT, left ventricular outflow tract; MAP, mean arterial pressure; MR, mitral regurgitation; PA, pulmonary artery; PFO, patent foramen ovale; PDA, patent ductus arteriosus; PR, pulmonary regurgitation; PS, pulmonary stenosis; RA, right atrium; RV, ventricle; RVAD, right ventricular assist device; RVOT, right ventricular outflow tract; SV, stroke volume; SVC, superior vena cava; TEE, transesophageal echocardiography; TR, tricuspid regurgitation; TS, tricuspid stenosis; TTE, transthoracic echocardiography.

Appendix D Magnitude and Time Course of Echo LV Parameter Changes Induced by CF-LVAD Unloading

Variable	Pre-LVAD Study 1 (N=21) Study 2 (N=63) Study 3 (N=80)	Post-LVAD 1 mo Study 1 (N=21) — Study 3 (N=68)	Post-LVAD 3 mo — Study 2 (N=63) Study 3 (N=47)	Post-LVAD 6 mo Study 1 (N=10) Study 2 (N=63) Study 3 (N=32)	Post-LVAD 12 mo — — Study 3 (N=20)
LV parameters					
LV diastolic diameter					
Study 1 (mm)	66 ± 11	55 ± 11**	—	52 ± 11*	—
Study 2 (mm)	68 ± 9	—	56 ± 11*	57 ± 12	—
Study 3 (cm/m ²)	3.2 (2.9, 3.6)	2.8 (2.3, 3.2)	2.9 (2.4, 3.4)	2.8 (2.2, 3.4)	2.6 (2.2, 3.0)*
LV systolic diameter					
Study 1 (mm)	58 ± 10	47 ± 12	—	43 ± 13	—
Study 2 (mm)	61 ± 9	—	47 ± 13*	49 ± 13	—
Study 3 (cm/m ²)	3.0 (2.6, 3.3)	2.6 (2.0, 3.1)	2.6 (2.1, 3.1)	2.5 (1.8, 2.9)	2.3 (1.9, 2.8)*
LV end-diastolic volume					
Study 1 (mL)	242 ± 108	127 ± 68*	—	113 ± 45*	—
Study 2	—	—	—	—	—
Study 3 (mL/m ²)	113 (94, 141)	77 (54, 109)*	86 (62, 106)*	86 (52, 108)*	69 (45, 93)*
LV end-systolic volume					
Study 1 (mL)	191 ± 93	100 ± 66*	—	82 ± 42*	—
Study 2	—	—	—	—	—
Study 3 (mL/m ²)	3.0 (2.6, 3.3)	2.6 (2.0, 3.1)*	2.6 (2.1, 3.1)	2.5 (1.8, 2.9)*	2.3 (1.9, 2.8)*
LV ejection fraction (%)					
Study 1	22 ± 5	25 ± 13	—	29 ± 10	—
Study 2	19 ± 7	—	26 ± 12*	27 ± 14	—
Study 3	17 (14, 23)	20 (15, 30)	20 (14, 26)	25 (18, 33)*	22 (15, 31)
LV mass					
Study 1	—	—	—	—	—
Study 2(g)	383 ± 113	—	295.9 ± 188*	314 ± 134	—
Study 3 (g/m ²)	114 (93, 146)	95 (71, 114)**	92 (63, 118)**	111 (74, 134)	77 (50, 104)*
LV diastolic parameters					
LA size					
Study 1 (mm)	47 ± 7	37 ± 9**	—	42 ± 13	—
Study 2 (mL/m ²)	69 ± 30	—	42 ± 15*	—	—
Study 3 (mL/m ²)	46 (35, 54)	28 (22, 36)*	32 (23, 38)*	25 (19, 39)*	28 (18, 38)*
E-wave					
Study 1 (cm/s)	96 ± 23	73 ± 27**	—	66 ± 12**	—
Study 2 (cm/s)	98 ± 35	—	100 ± 160	80 ± 20	—
Study 3 (cm/s)	100 (80, 110)	80 (60, 100)*	80 (70, 100)	80 (70, 110)	100 (60, 120)
E/A ratio					
Study 3	2.8 (2.1, 4.1)	2.2 (1.2, 3.6)	1.5 (1.0, 2.9)*	1.6 (1.3, 2.2)**	1.7 (1.0, 3.3)
Mitral DT					
Study 1	124 ± 39	180 ± 53**	—	164 ± 24	—
Study 2	132 ± 27	—	188 ± 70*	166 ± 48	—
Study 3	133 (112, 165)	175 (137, 220)*	178 (141, 212)*	172 (121, 220)*	170 (157, 225)
Tissue Doppler e' (cm/s)					
Study 1	—	—	—	—	—
Study 2 (septal e')	4 ± 1	—	4 ± 1	—	—
Study 3 (septal e')	4 (3, 6)	6 (5, 9)*	7(5,9)*	7 (4, 9)*	7 (6, 10)**
(lateral e')	8 (5, 11)	9 (7, 10)	9(6,11)	10 (7, 13)	12 (8, 12)

(Continued)

Appendix D (Continued)

Variable	Pre-LVAD	Post-LVAD 1 mo	Post-LVAD 3 mo	Post-LVAD 6 mo	Post-LVAD 12 mo
	Study 1 (N=21) Study 2 (N=63) Study 3 (N=80)	Study 1 (N=21) — Study 3 (N=68)	— Study 2 (N=63) Study 3 (N=47)	Study 1 (N=10) Study 2 (N=63) Study 3 (N=32)	— — Study 3 (N=20)
E/ e' (ratio)					
Study 1	—	—	—	—	—
Study 2 (septal e')	26 ± 11	—	20 ± 9**	13 ± 7	—
Study 3 (septal e')	23 (16, 30)	13 (9, 19)*	12 (9, 16)*	12 (9, 19)*	15 (7, 17)**
(lateral e')	14 (9, 19)	9 (16, 13)**	10 (6, 12)	9 (7, 13)	10 (6, 11)

Study 1, Lam et al. JASE 2009⁵²; Study 2, Topilsky et al. JASE 2011⁵¹; Study 3, Drakos et al. JACC 2013;61:1985-94. Values are mean ± SD for Studies 1 and 2 and median (25th, 75th percentiles) for Study 3; *P < .01 versus Pre-LVAD; **P < .05 versus Pre-LVAD. Study 2 P values only provided comparing Pre-LVAD and Post-LVAD 3-mo measurements. A, mitral valve late peak diastolic velocity; CF, continuous-flow; DT, deceleration time; E, mitral valve early peak diastolic velocity; e', mitral annular velocity; LA, left atrial; LV, left ventricle; LVAD, left ventricular assist device.

Appendix E LVAD Surveillance Echo Protocol: Standard Comprehensive TTE (or TEE) with Additional LVAD-Specific Parameters

Blood pressure (if no pulse, Doppler-derived mean arterial pressure)

Pump type and baseline speed

Degree of aortic valve opening/closure

Ventricular and interatrial septal position

LV inflow cannula

- Location
- Note optimal view for visualization
- Flow type
- Flow direction
- Peak systolic and diastolic flow velocities (pulsed Doppler)
- Velocity flow pattern

LV outflow graft

- Location/Note optimal view for visualization
- Flow type
- Flow direction
- Peak systolic and diastolic flow velocities (pulsed Doppler)
- Velocity flow pattern

LVAD output

- Outflow-graft pulsed Doppler VTI
- Cross-sectional area as calculated from the measured cannula diameter or from the known cannula diameter

Total cardiac output

- RVOT pulsed Doppler VTI
- Calculated cross-sectional area from the RVOT diameter

Pericardium: effusion/hematoma

Post-VAD Placement “Red Flag” Echo Findings

- Ventricular and/or atrial septal shift from mid-line
- Intracardiac shunt
- Excessive increase in cannula velocities
- Mechanical cannula obstruction
- Cannula suction event
- Worsening aortic or mitral regurgitation
- Cardiac thrombus
- Pericardial hematoma/effusion, with or without tamponade
- RV dysfunction (multiple parameters in aggregate)
 - Enlarged RV cavity size
 - RV systolic dysfunction (quantitative, if possible)
 - Moderate or severe TR
 - Elevated RA pressure

LV, Left ventricular; LVAD, left ventricular assist device; RA, right atrial; RV, right ventricular; RVOT, right ventricular outflow tract; TEE, transesophageal echocardiography; TR, tricuspid regurgitation; TTE, transthoracic echocardiography; VTI, velocity-time integral.

Refer to [Table 2](#) for guidance regarding the possible implications of abnormal / “red-flag” findings.

Appendix F LVAD Optimization/Ramp Echo Protocol

Perform baseline LVAD surveillance study (annotate BP, pump type, baseline pump speed)

At baseline pump speed, acquire the following:

- LVIDd in the parasternal long-axis view
- RV VTI (to calculate cardiac output) in the parasternal short-axis view
- AV opening by 2D and M-mode in the parasternal long-axis view (color Doppler M-mode if needed)
- 2D imaging in the parasternal long- and short-axis views
- Color Doppler examination of AR and MR in the parasternal long-axis and apical views
- Color Doppler examination of TR in the RV inflow and apical four-chamber view
- Standard mitral valve PW Doppler inflow parameters
- Positioning of the interventricular and interatrial septa

Decrease pump speed to as low as 8000 rpm (for HM-II)

or

Decrease pump speed to as low as 2400 rpm (for HVAD)

- Wait 2 minutes
- Repeat data acquisition

Increase pump speed by 400 rpm (for HM-II)

or

Increase pump speed by 20-40 rpm (for HVAD)

- Wait 2 minutes
- Repeat data acquisition

HM-II:

Continue to increase pump speed in **400-rpm** increments to a pump speed of up to **12,000 rpm** or until endpoint (below), acquiring data at each stage

HVAD:

Continue to increase pump speed in **20-40 rpm** increments to a pump speed of up to **3,200 rpm**, or until endpoint (below), acquiring data at each stage

Endpoints

- Completion of test
- Suction event: decrease in LV size (typically <3 cm), +/- ventricular ectopy, +/- inflow- cannula intermittent obstruction, leftward ventricular septal shift, worsening TR
- Symptoms including, but not limited to, palpitations, dizziness, chest pain, shortness of breath, or headache
- Hypertension (eg, MAP > 100 mm Hg or symptoms)
- Hypotension (eg, MAP < 60 mm Hg or symptoms)

2D, Two-dimensional; AR, aortic regurgitation; AV, aortic valve; BP, blood pressure; HM-II, HeartMate II; HVAD, HeartWare ventricular assist system; LV, left ventricular; LVAD, left ventricular assist device; LVIDd, left ventricular internal diameter at end-diastole; MAP, mean arterial pressure; MR, mitral regurgitation; PLAX, parasternal long-axis; PW, pulsed Doppler; RV, right ventricular; TR, tricuspid regurgitation; TV, tricuspid valve; VTI, velocity-time integral.

Note: Inflow-cannula color and spectral Doppler (including CW Doppler) should be evaluated at each pump speed to test for obstruction. Outflow-graft Doppler evaluation is needed at baseline but is optional at speed changes if LVAD function is normal. When abnormal conditions are being evaluated, additional parameters may be assessed when possible, such as outflow-graft velocity profile/stroke volume (eg, for obstruction or to assess AR volume) and outflow-graft-to-aortic anastomosis to assess obstruction or flow reversal.

Appendix G Speed Changes: LVAD Optimization or Problem-Focused (Ramp) Protocol Worksheet

Speed Changes: LVAD Optimization or Problem-Focused (Ramp) Protocol Worksheet

CF-LVAD type: **Implant date:** **[PT INR = ____ PTT = ____]**

Previous echo exam date and significant findings:

- **Optimization protocol.** Optimal speed based on MCS center’s own standard; sample order sets include the following: (a) Attain at least intermittent AV opening, or (b) attain neutral IVS position and/or mild or less MR, or (c) attain complete AV closure to maximize LV unloading or (d) adjust speed to below the maximum speed associated with complete AV closure and the minimum speed associated with more prominent MR and rightward IVS.
- **Problem-focused protocol.** *Indication for exam:* Sample order sets include the following indications:
 - a. Smoldering left- and/or right-sided heart failure.
 - b. Screen for pump function in setting of hemolysis and suspected pump thrombosis.
 - c. Other LVAD-alarm trouble-shooting.

Pump Speed (rpm)	BP	AV Opening (y/n/intermittent)	LVIDd (cm)	RVOT VTI (cm)	Signif AR (y/n)	Signif MR (y/n)	Signif TR (y/n)	TR Velocity (m/s)	MV Peak E Velocity (m/sec), DT (ms)	IVS Direction L/R/Neutral	a. Symptoms (y/n) b. Evidence of Inflow-Cannula Obstruction (y/n)

Reason for termination: (eg, signs of inflow-cannula obstruction, hypotension, hypertension, worsening RV or LV function, etc.)
Final speed setting = ____ rpm
Final BP = ____ mmHg

AR, Aortic regurgitation; AV, aortic valve; BP, blood pressure; CF, continuous-flow; DT, deceleration time; E, early diastole; INR, international normalized ratio; IVS, interventricular septum; LV, left ventricular; LVAD, left ventricular assist device; LVIDd, left ventricular internal diameter at end-diastole; MCS, mechanical circulatory support; MR, mitral regurgitation; MV, mitral valve; PT, prothrombin time; PTT, partial thromboplastin time; RVOT, right ventricular outflow tract; TR, tricuspid regurgitation; VTI, velocity-time integral.

Note: Parameters measured at each speed setting may vary according to an implant center’s internal standards. After examination at the baseline pump speed, most of the needed parameters at subsequent pump speeds may be obtained primarily from parasternal views in most cases, as a limited exam.

Appendix H LVAD Recovery Protocol Worksheet

LVAD Recovery Protocol Worksheet

CF-LVAD type: _____ **Implant date:** _____

Previous echo exam date and significant findings: _____

PT INR = _____ (ensure ≥ 2.0); PTT = _____ (heparin to be used if INR is < 2.0 per institutional protocol)

Baseline speed setting = _____ rpm;

Low speed testing target achieved:

6000 rpm (HM-II) by increments of 1000 rpm from baseline

1800 rpm (HVAD) by increments of 100 rpm from baseline

Echocardiographic Measurements

Pump Speed (rpm)	BP	Direction of Inflow-Cannula/Outflow-Graft Flow: Forward (f) Neutral (n) Reverse (r)	AV Opening (y/n/intermittent) vs milliseconds (M-mode)	LVEF	LVIDd (cm)	RV systolic function normal? (y/n)	RV size normal (y/n)	RVOT VTI (cm)	Signif AR (y/n)	Signif MR (y/n)	Signif TR (y/n)/TR Velocity (m/s)	MV Peak E Velocity (m/s), DT (ms)	Exercise Test (y/n)	Symptoms (y/n)

Baseline pump speed
Low pump speed
At intervals per institutional standards

The above echo measurements will be obtained at baseline and low pump speed at different time intervals:
i. After 5 min of low speed
ii. After 15 min of low speed
iii. After 6-min walk*

Hemodynamic measurements (rest \pm exercise) per institutional standards

eg, systolic BP, diastolic BP, mean BP, HR, and Swan-Ganz catheter measurements at the following intervals:
i. Baseline rpm
ii. 0 min of low speed
iii. 5 min of low speed
iv. 10 min of low speed
v. 15 min of low speed
vi. After 6-min walk at low speed

Reason for termination (circle)

Shortness of breath, chest pain, blurred vision, dizziness, abdominal pain (perform 12-lead ECG if chest pain is noted)

Final speed setting = _____ rpm
Final BP = _____ mmHg
Final clinical status: _____

AR, Aortic regurgitation; AV, aortic valve; BP, blood pressure; CF, continuous-flow; DT, deceleration time; E, early diastole; ECG, electrocardiography; HM-II, HeartMate left ventricular assist device; HR, heart rate; HVAD, HeartWare ventricular assist system; INR, international normalized ratio; IVS, interventricular septum; LV, left ventricular; LVAD, left ventricular assist device; LVEF, left ventricular ejection fraction; LVIDd, left ventricular internal diameter at end-diastole; MCS, mechanical circulatory support; MR, mitral regurgitation; MS, mitral stenosis; MV, mitral valve; PT, prothrombin time; PTT, partial thromboplastin time; RVOT, right ventricular outflow tract; TR, tricuspid regurgitation; VTI, velocity-time integral.
Note: Parameters measured at each speed setting and the type and timing of physiologic/exercise testing performed may vary according to an implant center's internal standards. After examination at the baseline pump speed, most of the needed parameters at subsequent pump speeds may be obtained primarily from parasternal views in most cases, as a limited exam. If a quantitative LVEF (preferred) is not obtainable, a qualitative LVEF should be provided.

*Institutional standards regarding spare batteries, second controller availability, and alarm-off mode settings should be followed and confirmed with the LVAD team.