31st Annual State of the Art Echocardiography | San Diego, CA

February 18, 2018 | 5:00 – 5:15 PM | 15 min

Percutaneous Therapy for Calcific Mitral Valve Disease

Muhamed Sarić MD, PhD, MPA
Director of Noninvasive Cardiology | Echo Lab
Associate Professor of Medicine

NYU Langone MEDICAL CENTER

Disclosures

Speakers Bureau (Philips, Medtronic)
Advisory Board (Siemens)

Calcific Mitral Valve Disease

- **Mitral annular calcification (MAC)** is the primary form of calcific nonrheumatic mitral valve disease
- Calcifications often extend to **other parts of the mitral apparatus**
- Unlike rheumatic stenosis, MAC-associated stenosis has **no commissural fusion**
- May lead to **mitral stenosis** and/or **mitral regurgitation**
- **Degenerative disease** associated with aging, atherosclerosis, aortic stenosis and renal disease

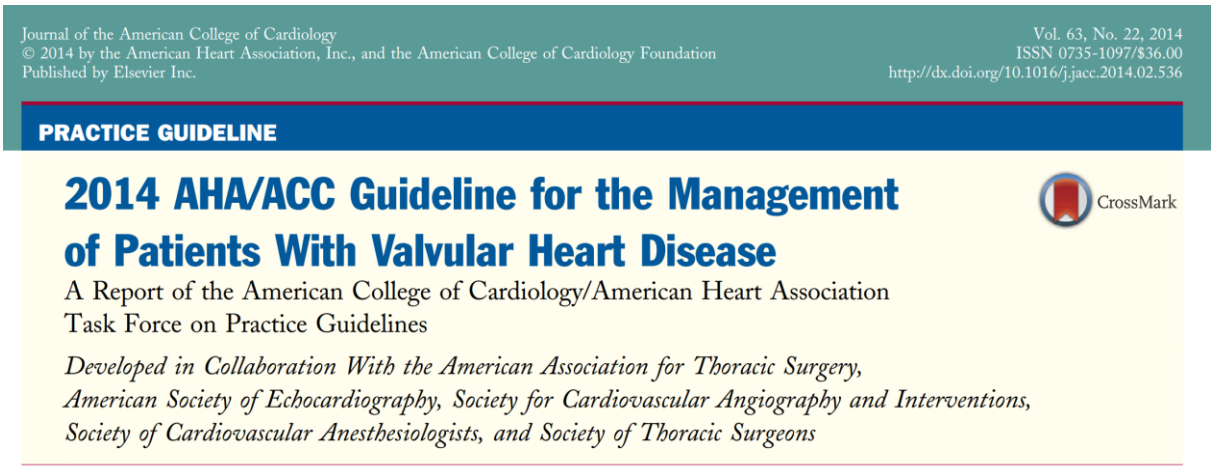

Nonrheumatic Calcific Mitral Disease

- **Natural History**
  - Data are relatively sparse on the natural history of senile calcific mitral stenosis.

- **Mitral Stenosis Diagnosis**
  - **Mean pressure gradient** from Doppler echocardiography is accurate
  - However, mitral valve area calculation by **pressure half-time** is uncertain in this population

- **Treatment**
  - Patients with calcification are often elderly and debilitated, have multiple comorbidities, and are at **high risk** for percutaneous or surgical intervention
  - Intervention should be **delayed** until symptoms are severely limiting and cannot be managed with diuresis and heart rate control

TTE

TTE: Nonrheumatic Calcific MV Disease

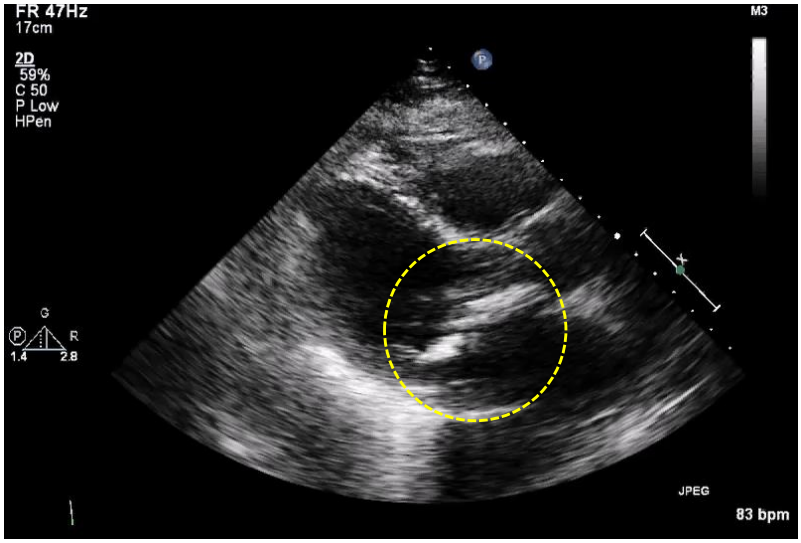

TTE: Nonrheumatic Calcific MV Disease

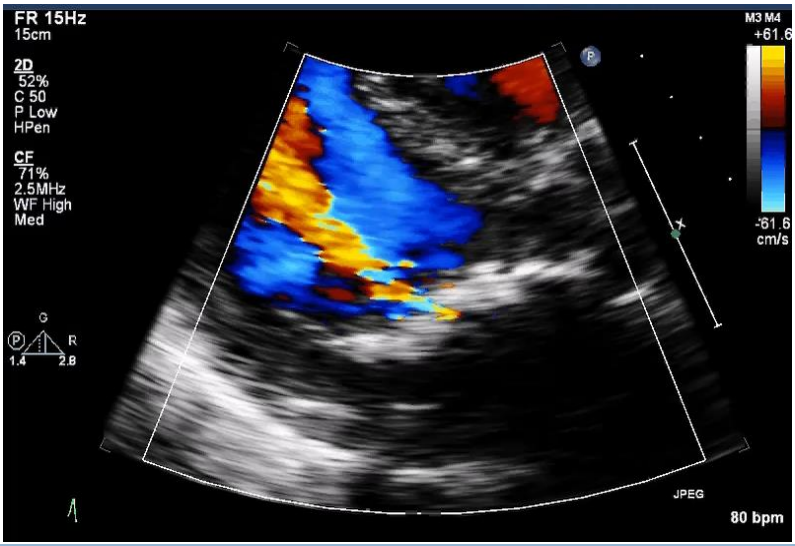

TTE: Nonrheumatic Calcific MV Disease

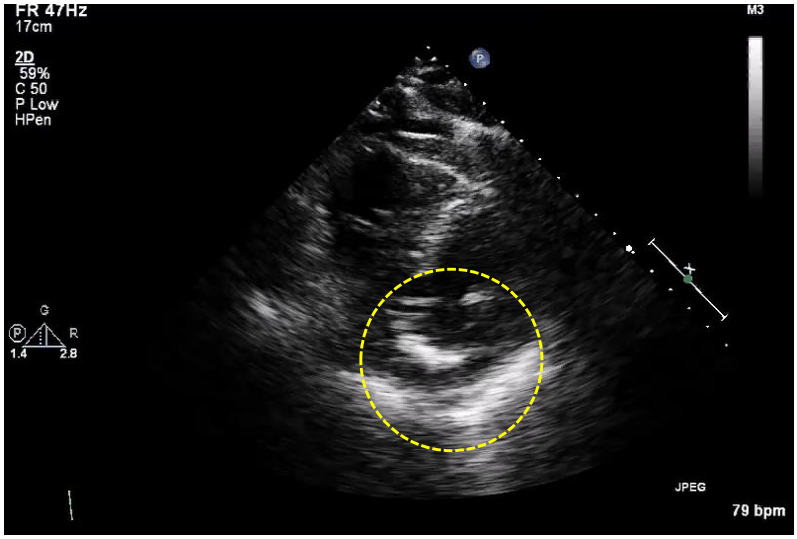

TTE: Nonrheumatic Calcific MV Disease

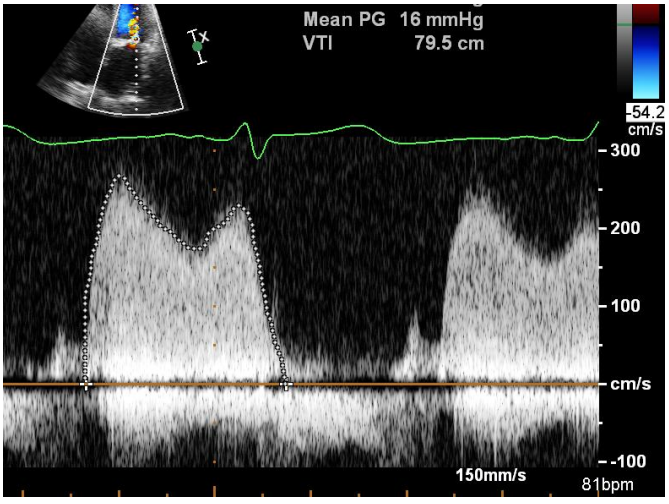

MEAN MITRAL DIASTOLIC GRADIENT
16 mm Hg at HR 81 bpm

TTE: Nonrheumatic Calcific MV Disease

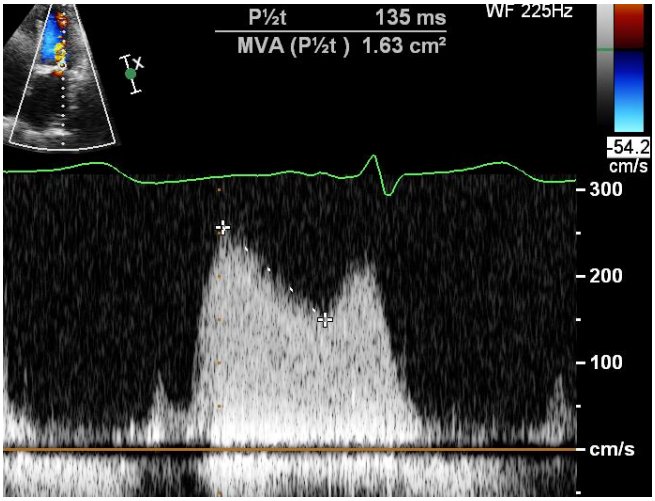

PRESSURE HALF-TIME METHOD
Should **NOT** be used
for this form of mitral stenosis!

2D & 3D TEE

2D TEE: Nonrheumatic Calcific MV Disease

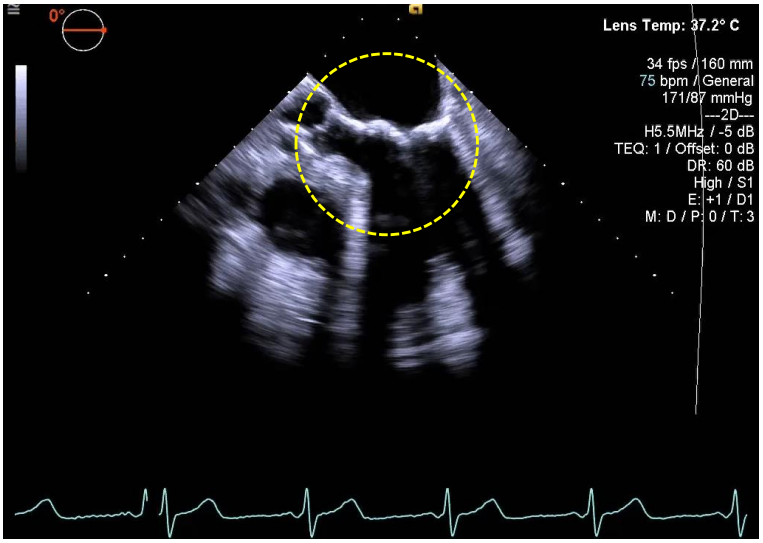

3D TEE: Nonrheumatic Calcific MV Disease

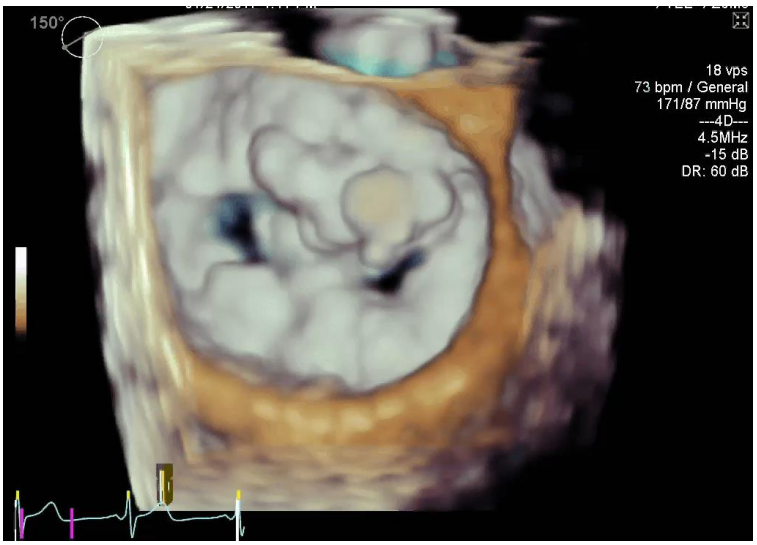

3D TEE: Nonrheumatic Calcific MV Disease

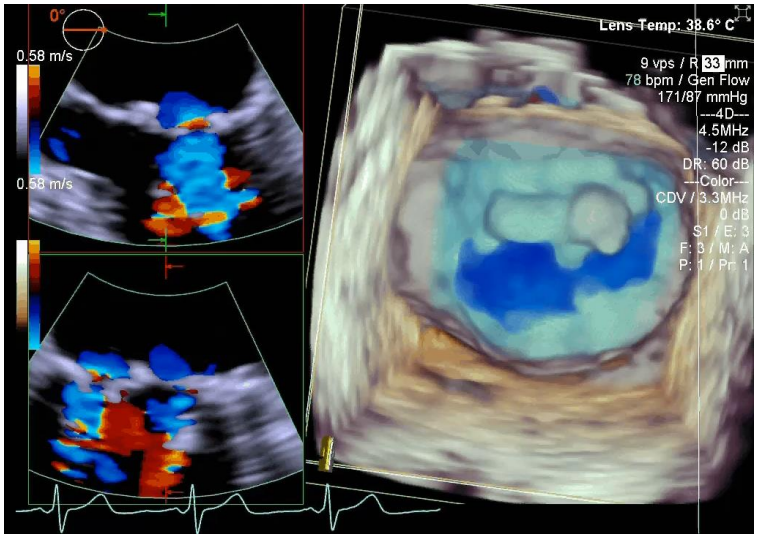

CT

CT: Nonrheumatic Calcific MV Disease

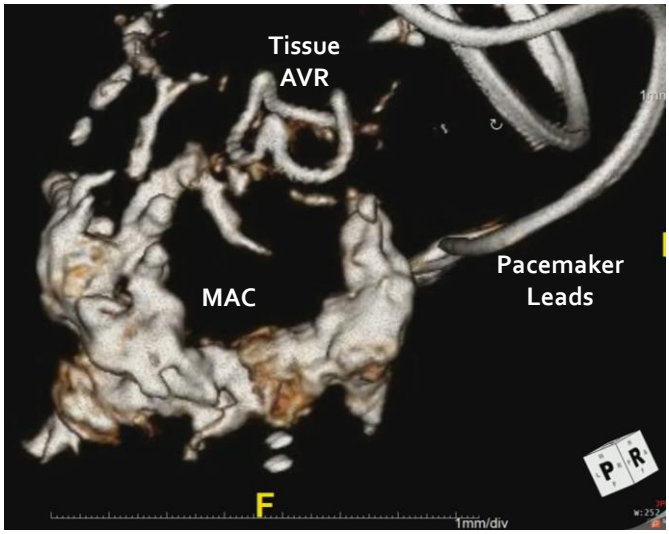

CT: Nonrheumatic Calcific MV Disease

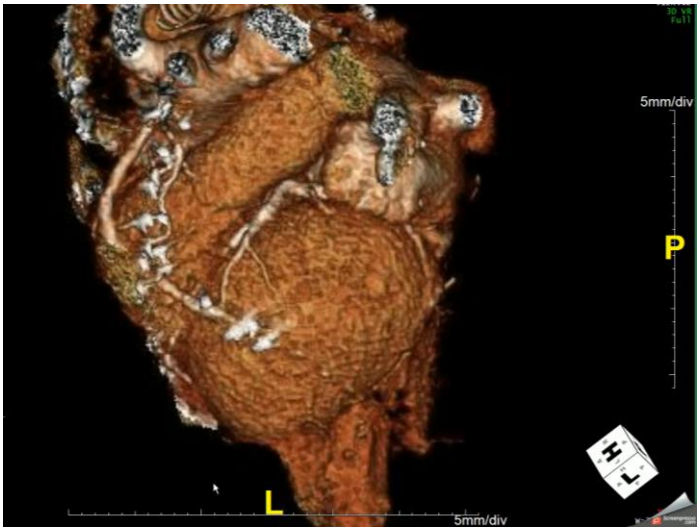

Nonmedical Treatment Options

- **Definitely Not Candidate For**
  - Percutaneous mitral balloon valvuloplasty (PMBV)
- **Likely Not Candidate For**
  - Transcatheter mitral valve replacement (TMVR)
- **Possibly Candidate For**
  - Mitral valve surgery
  - Percutaneous **valve-in-MAC** procedure

Not An Option: Balloon Valvuloplasty

DWIGHT HARKEN
(1910 – 1993)
Iowa-born
Cardiac Surgeon

Coined the term
Mitral Valvuloplasty

CHARLES BAILEY
(1910 – 1993)
New Jersey-born
Cardiac Surgeon

Coined the term
Mitral Commissurotomy

Normal MV vs. Rheumatic Mitral Stenosis

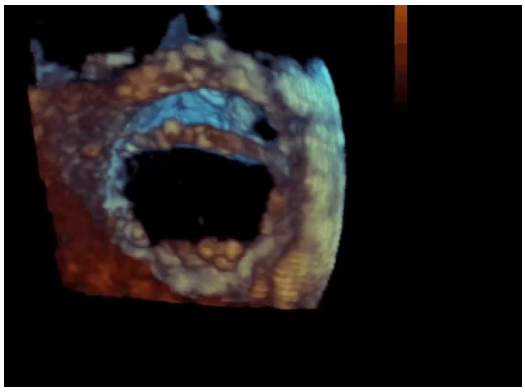

Normal mitral valve

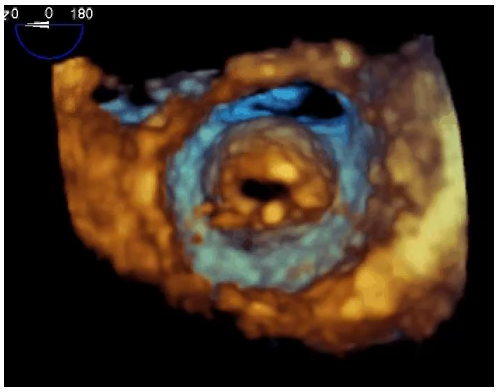

Severe rheumatic mitral stenosis

Commissural fusion is hallmark
of RHEUMATIC mitral stenosis

Mitral Balloon Valvuloplasty

Inoue balloon is reinforced with a nylon micromesh. Its shape changes in 3 stages, depending on the extent of inflation.

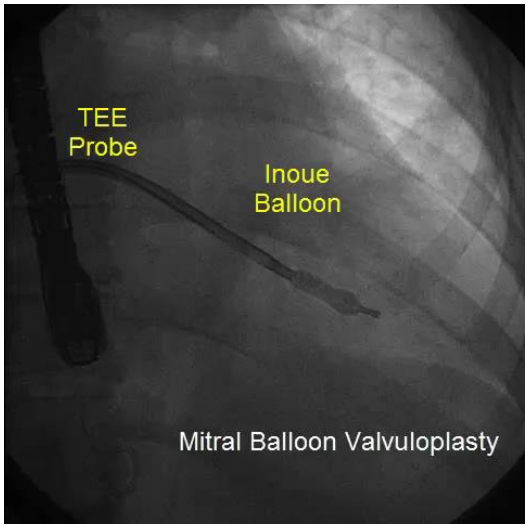

Rheumatic Mitral Stenosis: Balloon Valvuloplasty

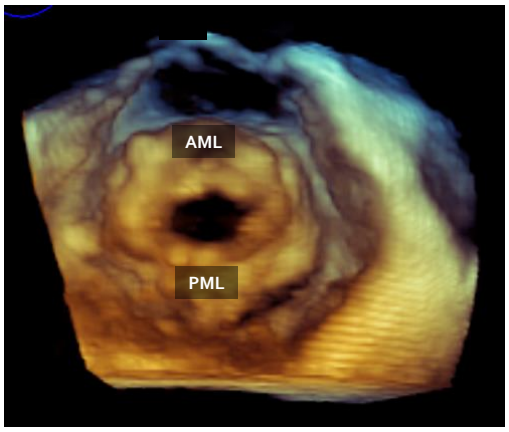

Before Valvuloplasty

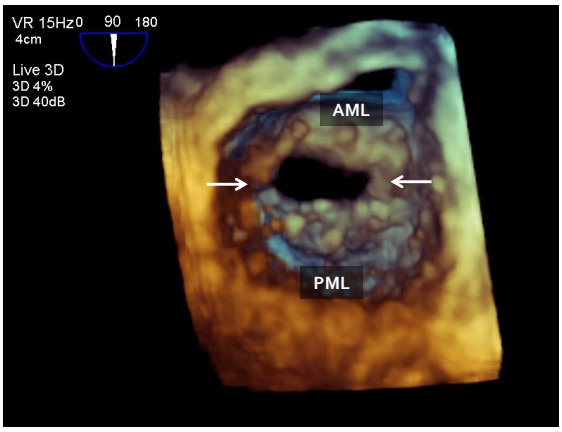

After Valvuloplasty

Question

Balloon valvuloplasty is NOT indicated
for calcific nonrheumatic valve disease. Why?

Answer

- Valvuloplasty (commissurotomy) works by disrupting commissural fusion.
- Commissural fusion is NOT a feature of calcific nonrheumatic mitral valve disease.
- Thus, commissurotomy does NOT work for calcific nonrheumatic mitral valve disease.

Likely Not an Option: Transcatheter MV Replacement

Caisson TMVR

Transvenous / Transseptal Implantation

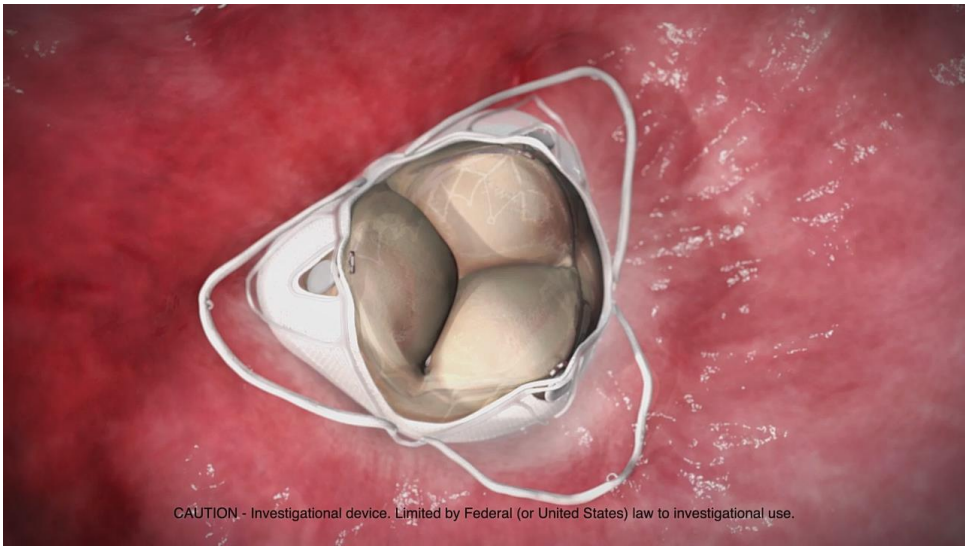

3D TEE & Angio Fusion Guidance

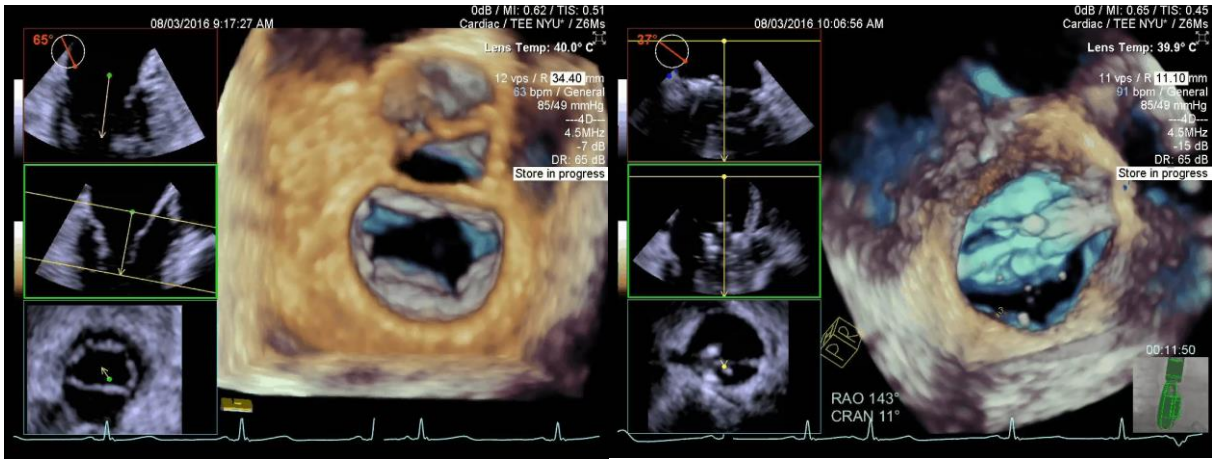

Precise Diagnosis of MV Disease **Accurate Procedural Guidance**

3D TEE & Angio Fusion Guidance

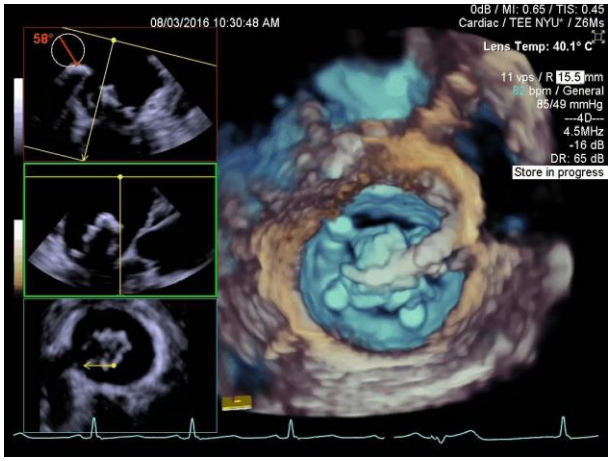

Precise TMVR Anchor Placement Guidance

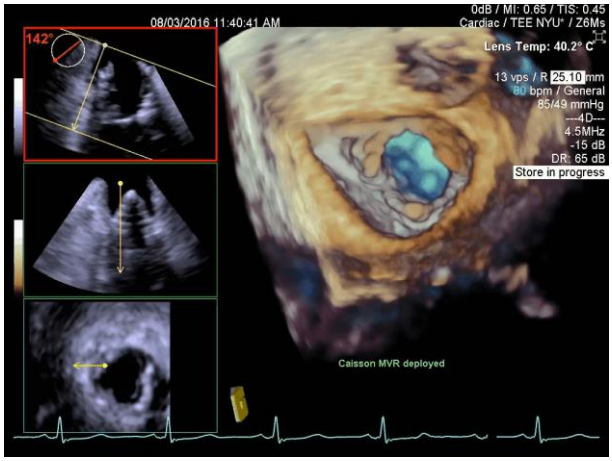

Successful TMVR Deployment

Intrepid TMVR

Transapical Implantation

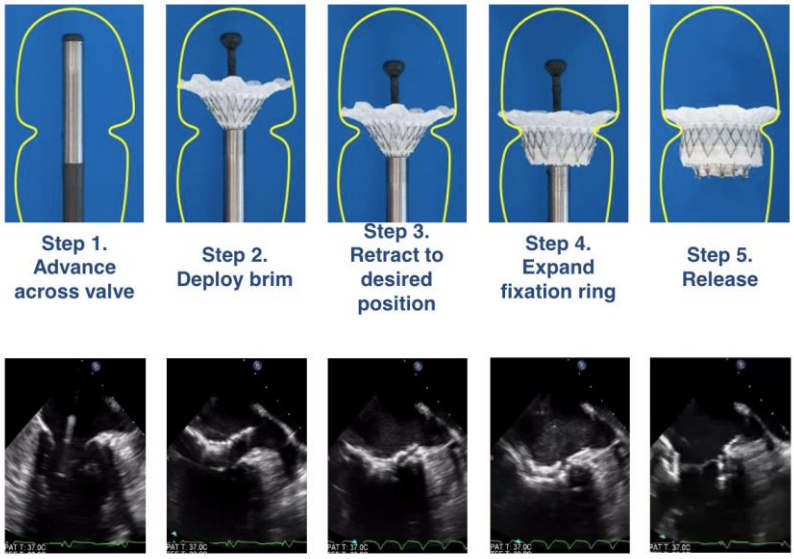

Intrepid TMVR

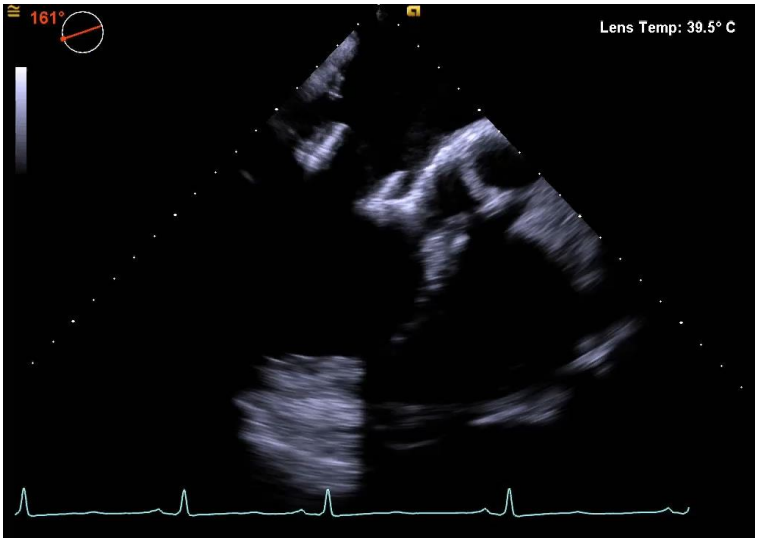

Intrepid TMVR

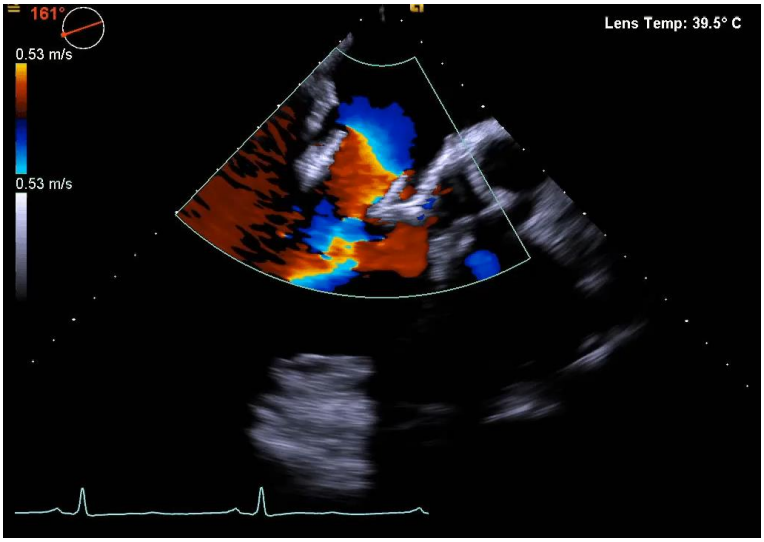

Intrepid TMVR

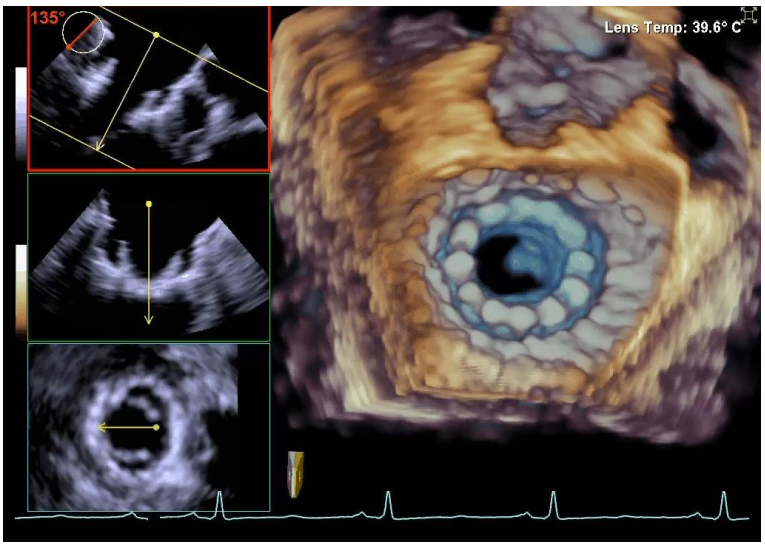

Question

Patients with calcific nonrheumatic valve disease are typically exluded from TMVR trials. Why?

Answer

Marked mitral annular calcification is typically an exclusion criterion for TMVR trials

Not a Great Option: Mitral Valve Surgery

Surgery for Calcific Nonrheumatic MV Disease

- **2014 ACC/AHA Valvular Disease Guidelines**
  - Severe mitral annular calcification causes **problems in securely attaching the prosthetic valve**
  - **Supra-annular insertion** and other innovative techniques can be used, such as placement of a **felt patch around the valve orifice to anchor the prosthesis**; however, this only works if the mitral orifice is adequate. If the annular calcification narrows the orifice, it has to be debrided.
  - The other alternative is **left atrial to ventricular bypass with a valved conduit** in extreme cases of calcification both of the leaflet and the annulus.
  - Patients with calcification are often elderly and debilitated, have multiple comorbidities, and are at **high risk for surgery**.

Possible Option: Valve-in-MAC

Valve-in-MAC Concept

Placement of a TAVR valve (typically a Sapien valve)
in a fashion similar to mitral valve-in-valve procedure.

MAC conceptually plays the same role as
the surgical bioprosthetic sewing ring
in standard mitral valve-in-valve procedure.

Mitral Valve-in-Valve Procedure

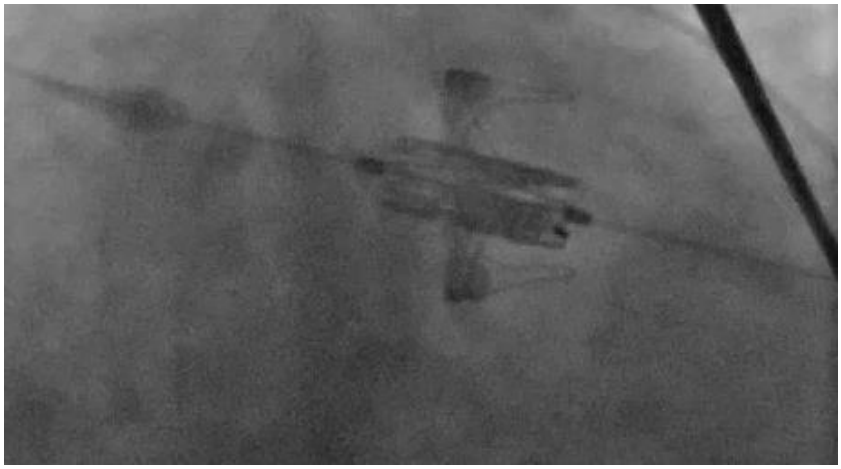

Mitral Valve-in-Valve Procedure

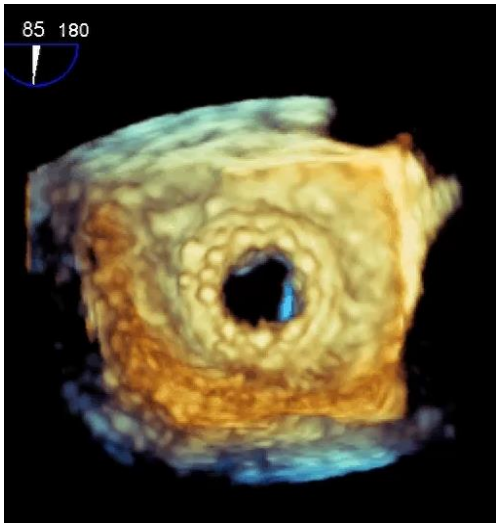

Valve-in-MAC

Step #1
Transseptal Puncture

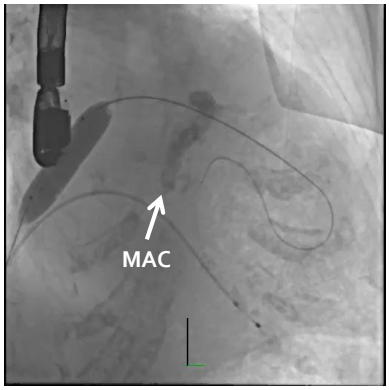

Step #2
Prosthetic Valve Positioning

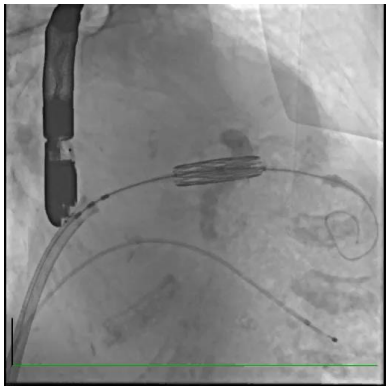

Step #3
Valve Deployed in MAC

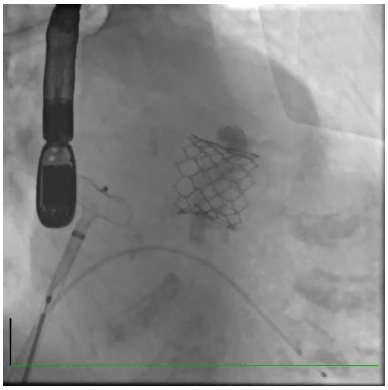

Prior to Valve-in-MAC

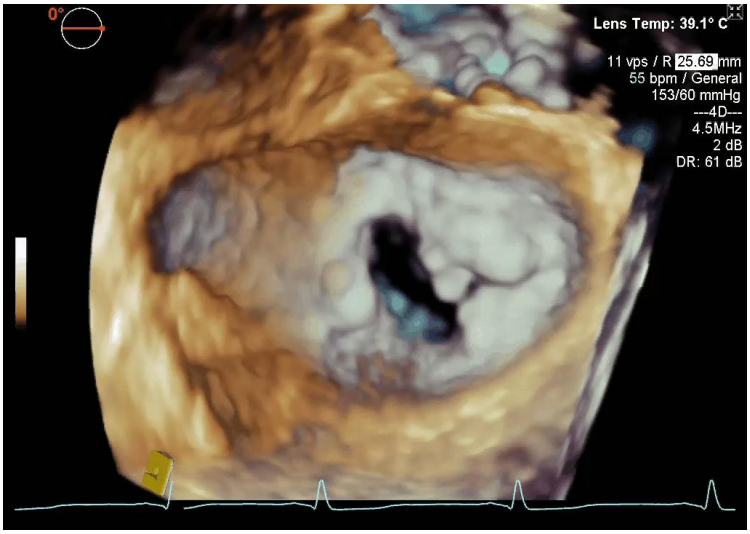

After Valve-in-MAC

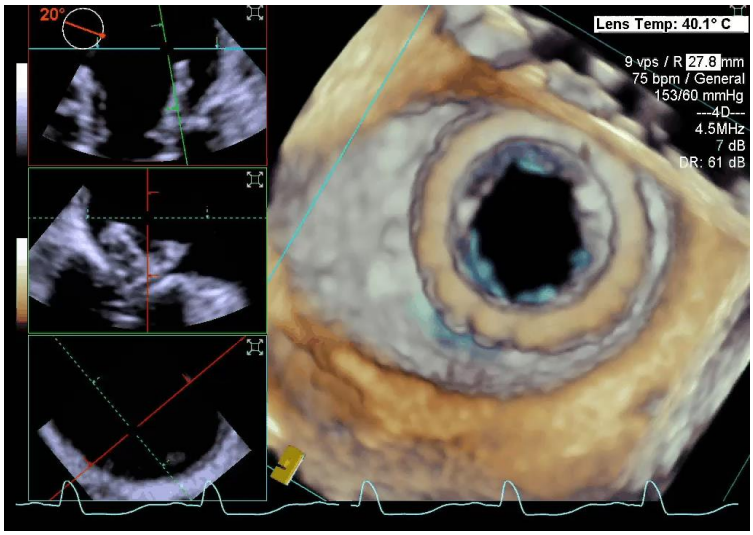

JACC: CARDIOVASCULAR INTERVENTIONS
© 2016 BY THE AMERICAN COLLEGE OF CARDIOLOGY FOUNDATION
PUBLISHED BY ELSEVIER

VOL. 9, NO. 13, 2016
ISSN 1936-8798/$36.00
http://dx.doi.org/10.1016/j.jcin.2016.04.022

STRUCTURAL

Transcatheter Mitral Valve Replacement in Native Mitral Valve Disease With Severe Mitral Annular Calcification

Results From the First Multicenter Global Registry

ABSTRACT

OBJECTIVES This study sought to evaluate the outcomes of the early experience of transcatheter mitral valve replacement (TMVR) with balloon-expandable valves in patients with severe mitral annular calcification (MAC) and reports the first large series from a multicenter global registry.

BACKGROUND The risk of surgical mitral valve replacement in patients with severe MAC is high. There are isolated reports of successful TMVR with balloon-expandable valves in this patient population.

METHODS We performed a multicenter retrospective review of clinical outcomes of patients with severe MAC undergoing TMVR.

RESULTS From September 2012 to July of 2015, 64 patients in 32 centers underwent TMVR with compassionate use of balloon-expandable valves. Mean age was 73 ± 13 years, 66% were female, and mean Society of Thoracic Surgeons score was 14.4 ± 9.5%. The mean mitral gradient was 11.45 ± 4.4 mm Hg and the mean mitral area was 1.18 ± 0.5 cm^2. SAPIEN valves (Edwards Lifesciences, Irvine, California) were used in 7.8%, SAPIEN XT in 59.4%, SAPIEN 3 in 28.1%, and Inovare (Braile Biomedica, Brazil) in 4.7%. Access was transatrial in 15.6%, transapical in 43.8%, and transseptal in 40.6%. Technical success according to Mitral Valve Academic Research Consortium criteria was achieved in 46 (72%) patients, primarily limited by the need for a second valve in 11 (17.2%). Six (9.3%) had left ventricular tract obstruction with hemodynamic compromise. Mean mitral gradient post-procedure was 4 ± 2.2 mm Hg, paravalvular regurgitation was mild or absent in all. Thirty-day all-cause mortality was 29.7% (cardiovascular = 12.5% and noncardiac = 17.2%); 84% of the survivors with follow-up data available were in New York Heart Association functional class I or II at 30 days (n = 25).

CONCLUSIONS TMVR with balloon-expandable valves in patients with severe MAC is feasible but may be associated with significant adverse events. This strategy might be an alternative for selected high-risk patients with limited treatment options. (J Am Coll Cardiol Intv 2016;9:1361–71) © 2016 by the American College of Cardiology Foundation.

Valve-in-MAC Challenges

Paravalvular Leak

Valve-in-MAC: Paravalvular Leak

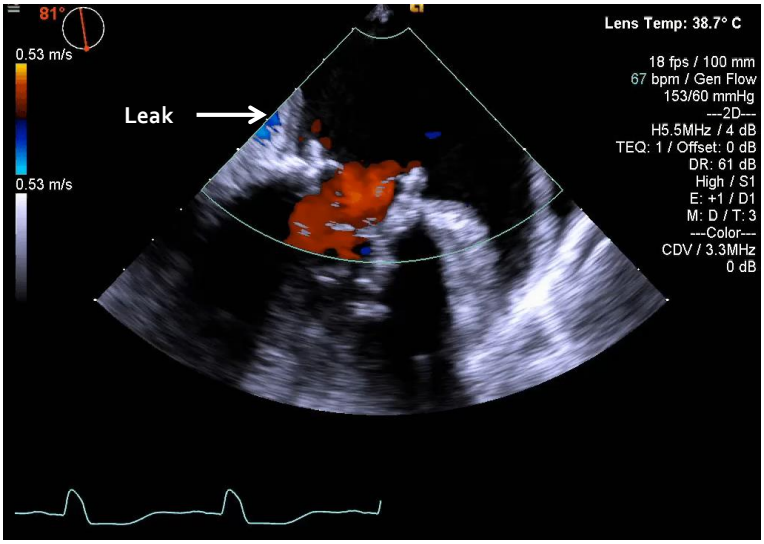

Valve-in-MAC Challenges

Valve Dislodgment

Valve-in-MAC: Valve Dislodgement

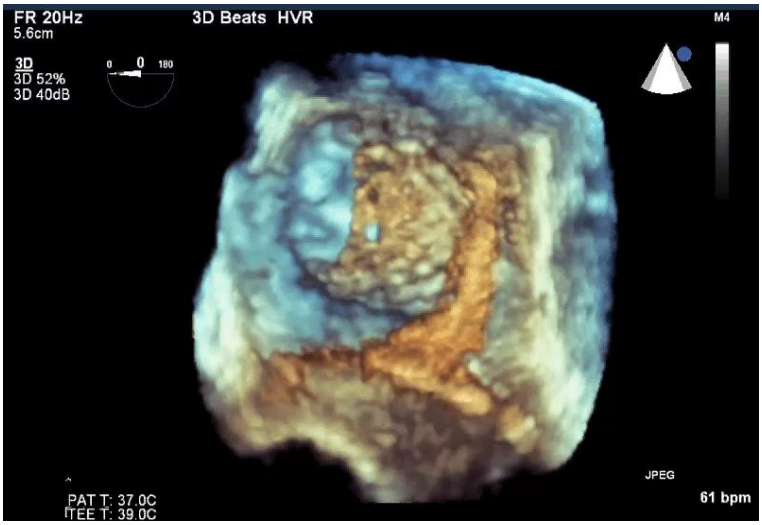

Surgical Retrieval of Dislodged Valve-in-MAC

Thank You!

New York University Langone Medical Center