

## CASE STUDIES: COMPLICATIONS OF MYOCARDIAL INFARCTION

Judy Hung, MD  
Cardiology Division  
Massachusetts General Hospital  
Boston, MA

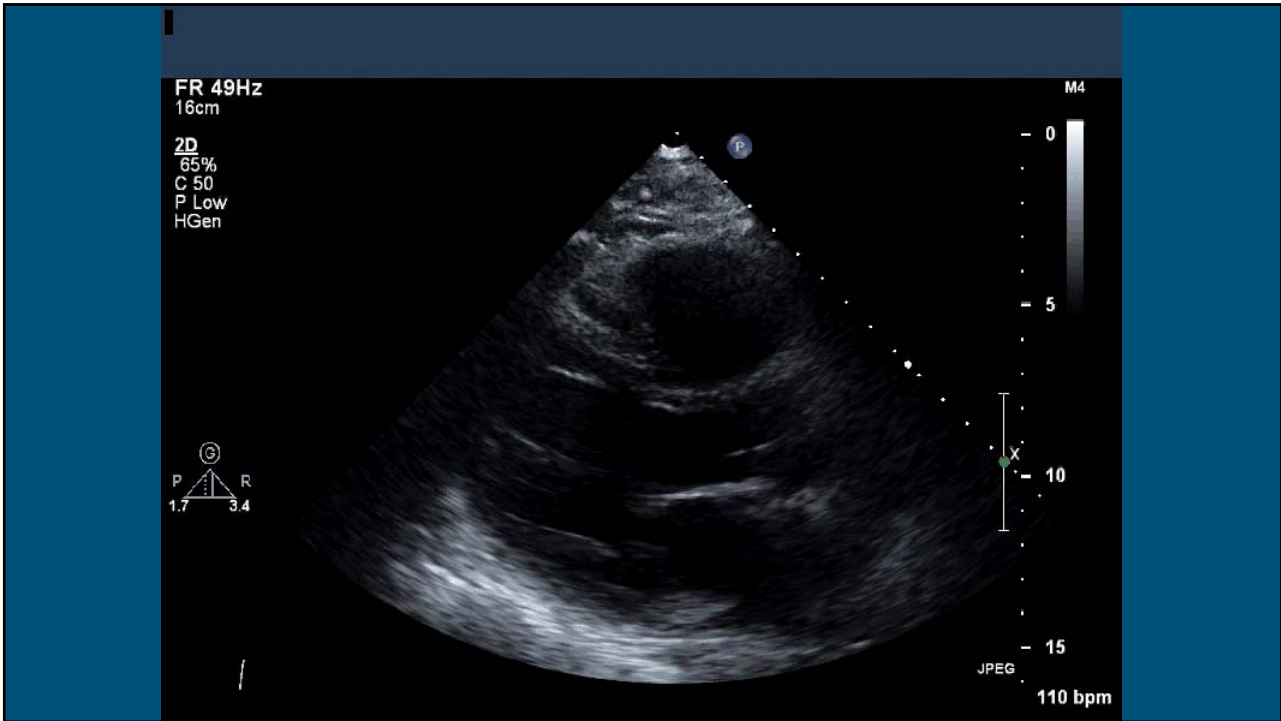
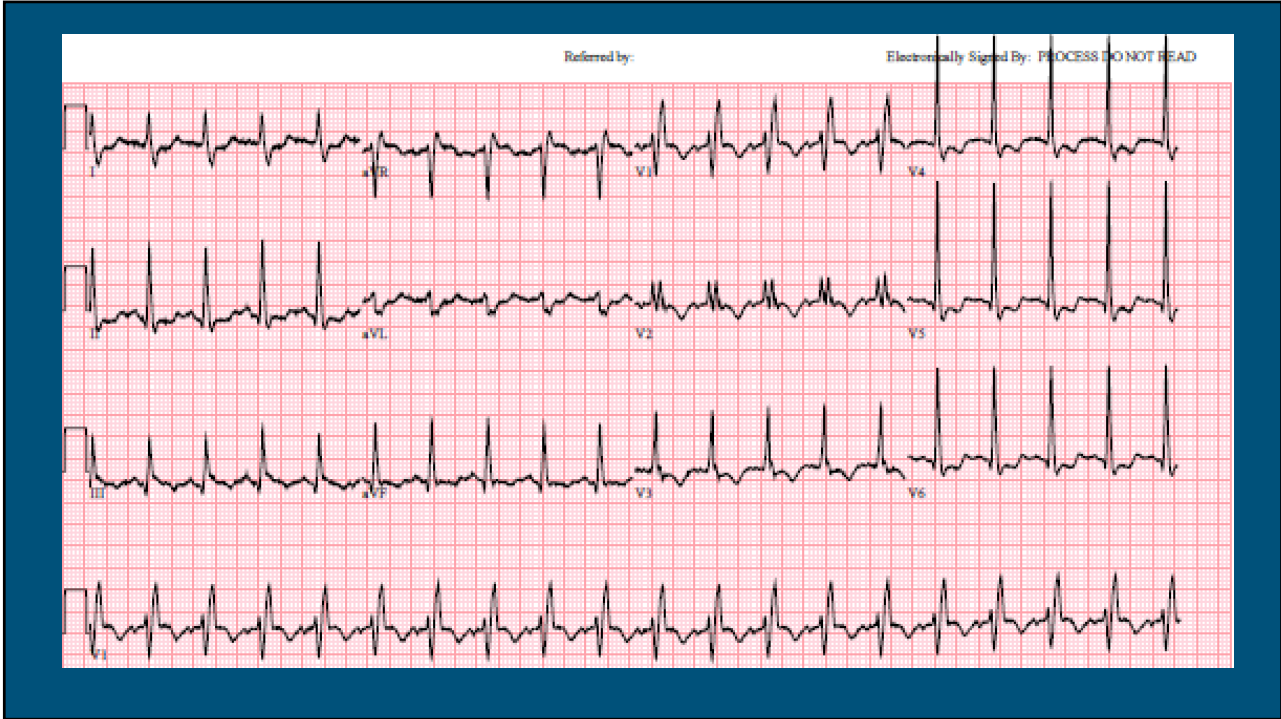
### CASE I

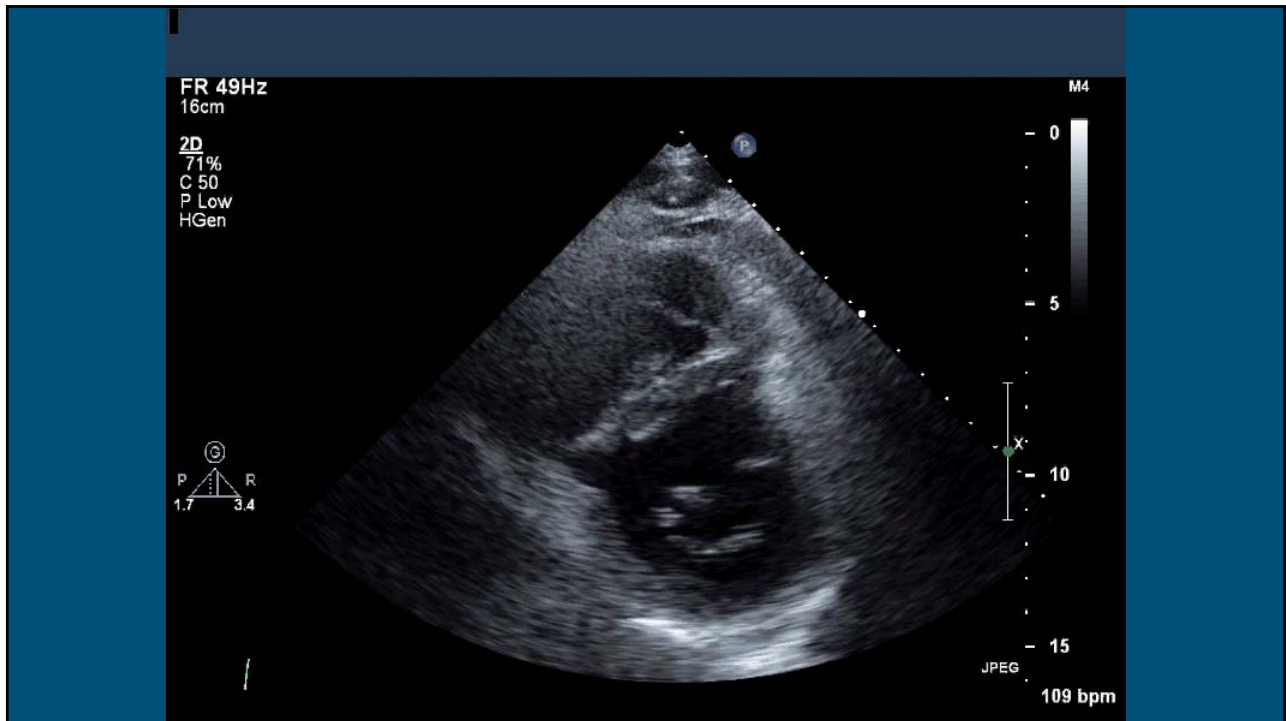
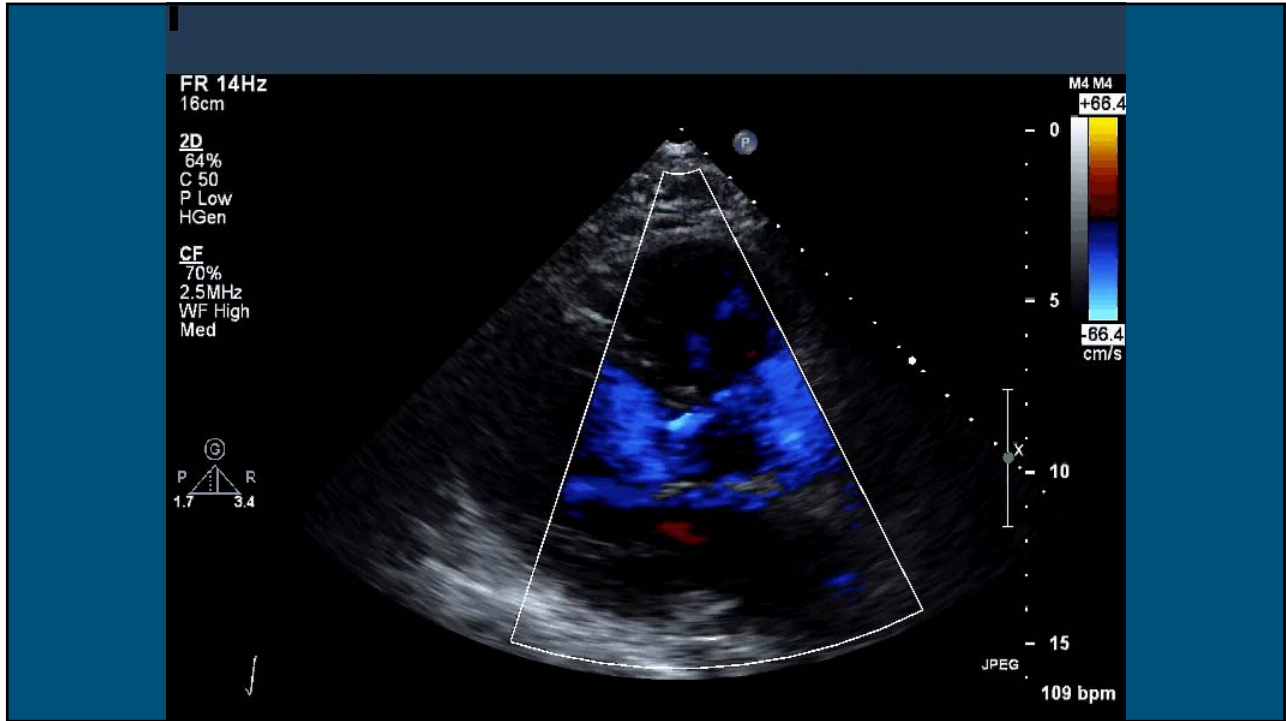
## PRESENTATION

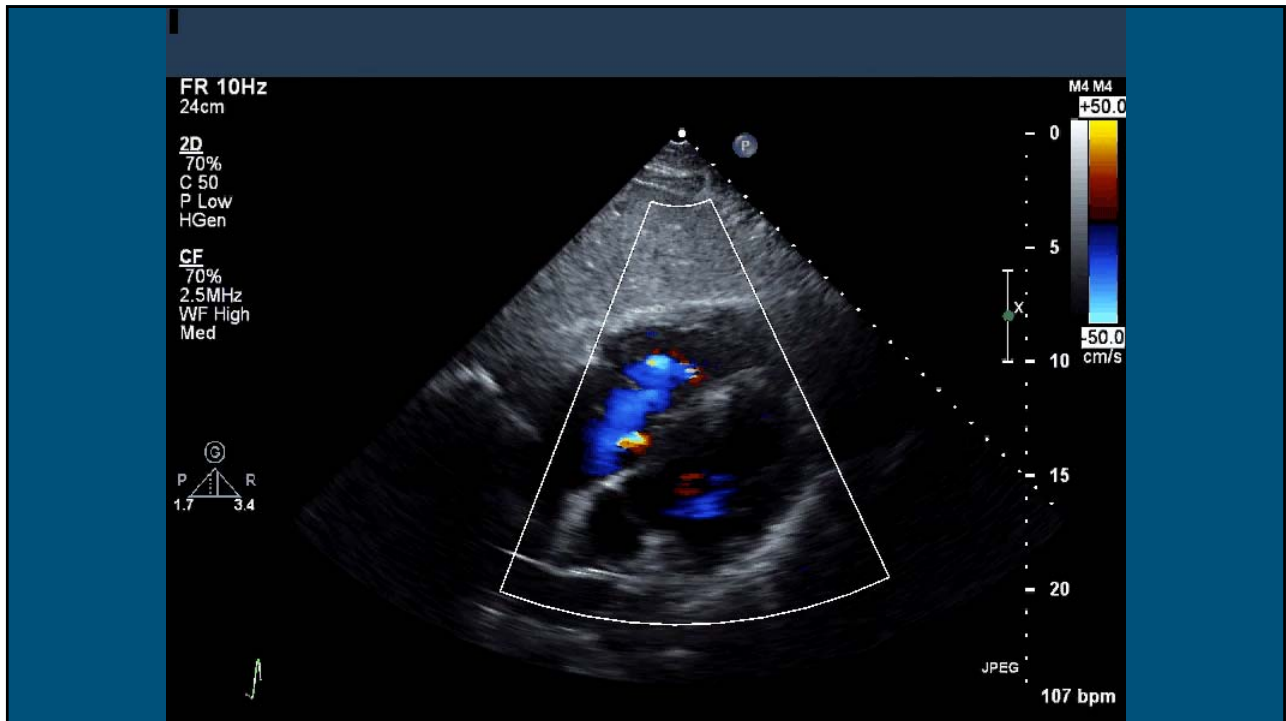
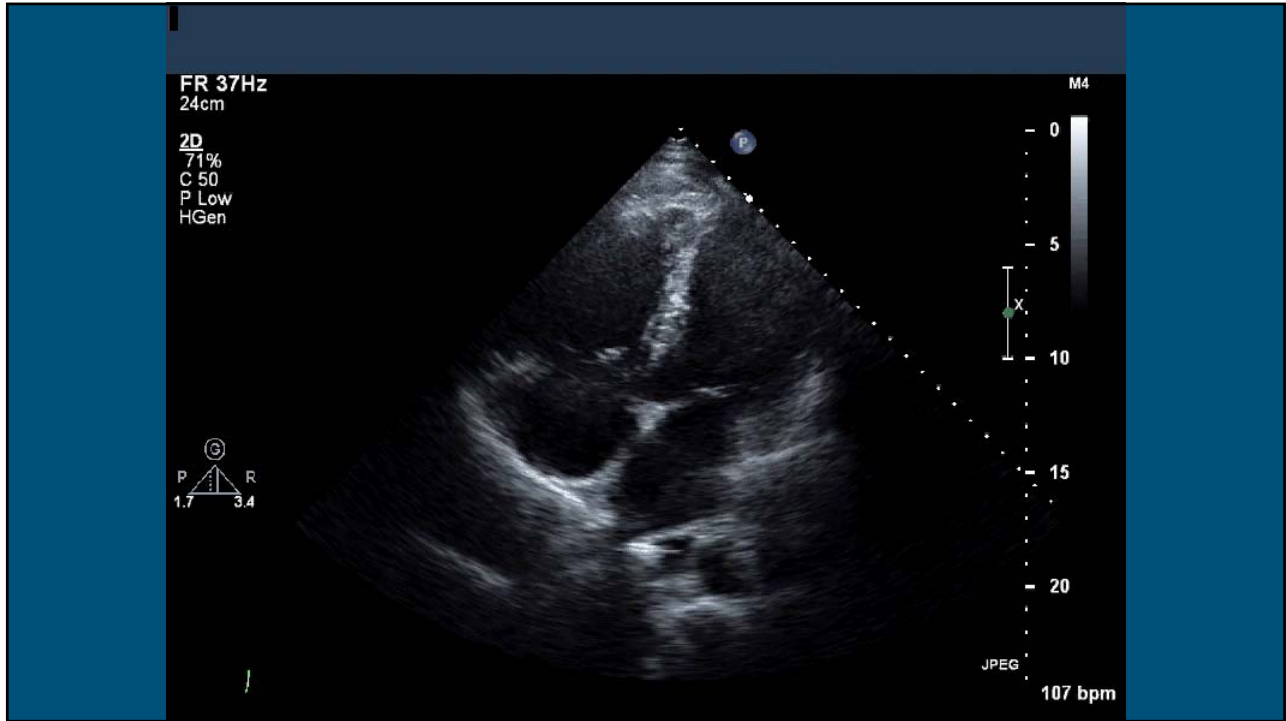
- 57 yo male with a past medical history of hypertension presented with fatigue and dyspnea on exertion
- 4 days prior to presentation the patient developed chest, back, and upper shoulder pain while digging a grave for his pet
- The next day he continued to not feel well with fatigue, nausea, and vomiting
- The next morning the patient reported that he felt better; however, the following morning he again started to feel unwell with fatigue and dyspnea on exertion
- The patient contacted his primary care physician who recommended that the patient be evaluated in the emergency department

## PRESENTATION

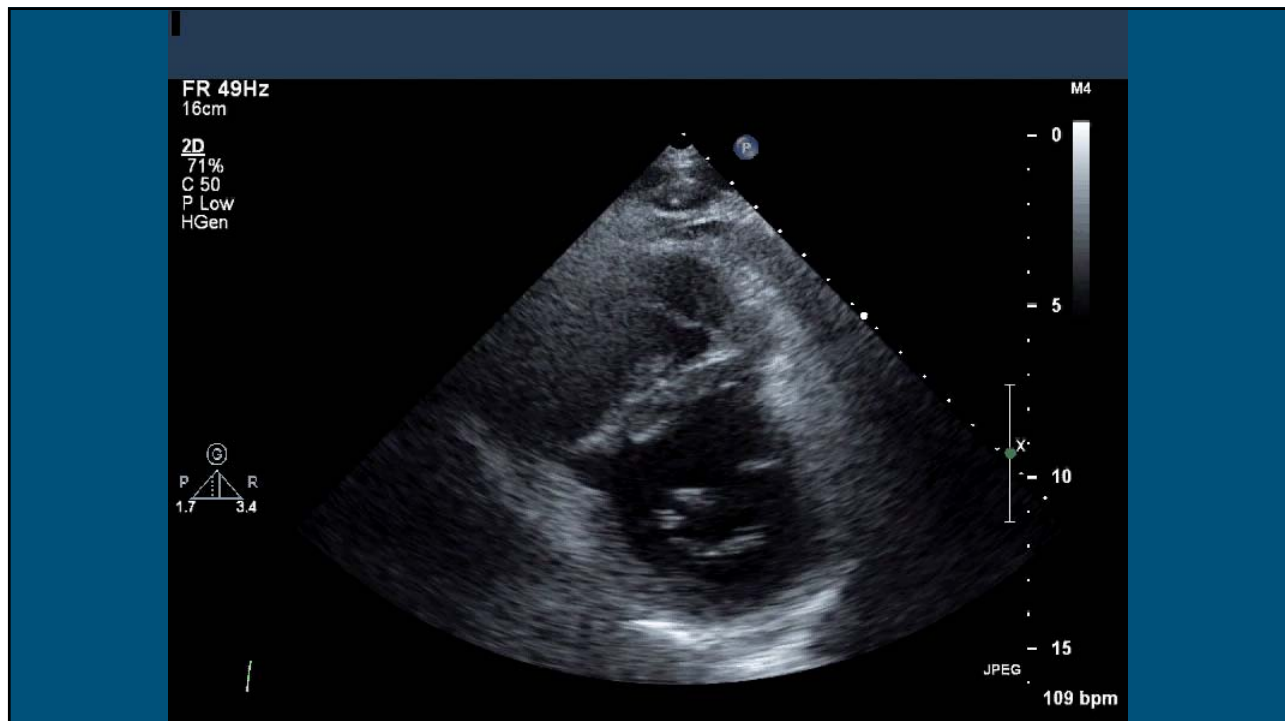
- The patient's vital signs upon arrival to the emergency department were: T: 97.6, HR: 116, BP: 116/84, RR: 24, SpO2: 98% RA
- Physical exam was notable for a harsh, holosystolic murmur heard throughout the precordium
- Initial lab work was notable for a troponin I of 5.6 ng/ml and elevated BUN/Cr of 72/4.2

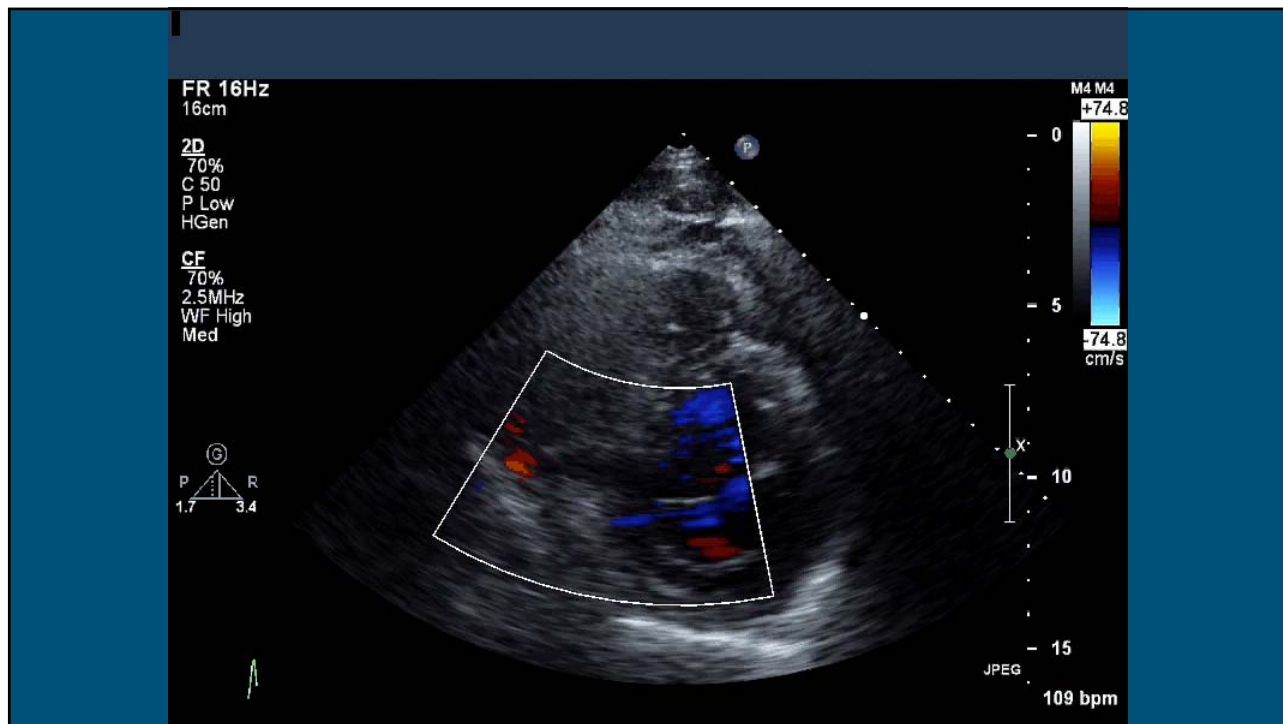






BASED UPON THIS  
ECHOCARDIOGRAM WHAT IS THE  
MOST LIKELY ETIOLOGY OF THE  
PATIENT'S SYMPTOMS?

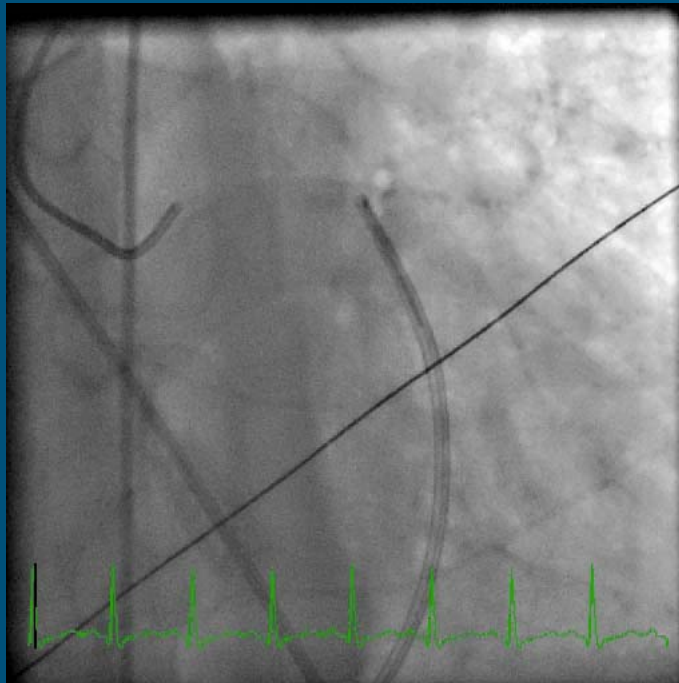



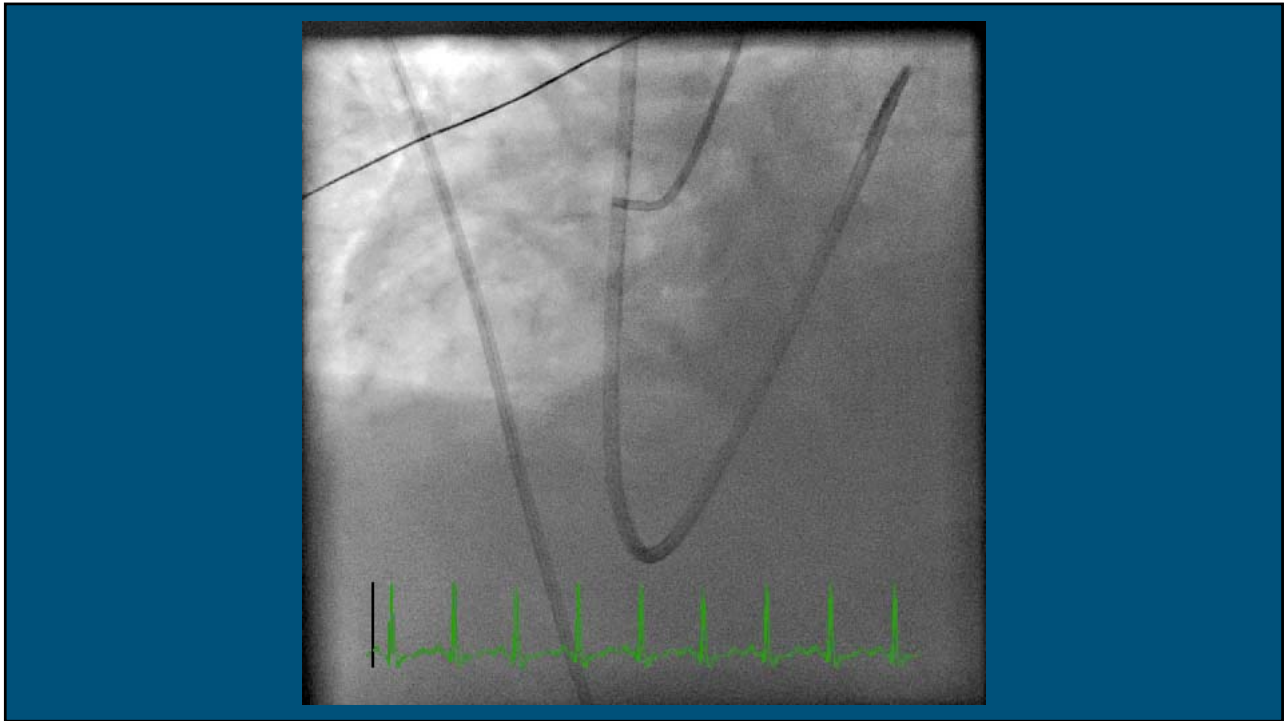
## PRESENTATION

- The patient was sent for a right heart catheterization and coronary angiogram
- RHC
  - O2 Sat:
    - SVC: 46.3%
    - IVC: 54.4%
    - High RA: 47%
    - Low RA: 56%
    - RV: 85%
    - PA: 79%
  - Hemodynamics:
    - RA: 18, RV: 62/17, PA: 62/24/26, PCWP: 23 (with V waves to 60)

A BLOCKAGE IN WHICH  
CORONARY ARTERY IS MOST LIKELY  
RESPONSIBLE FOR THIS PATIENT'S  
VENTRICULAR SEPTAL DEFECT?







## VENTRICULAR SEPTAL DEFECTS

- Epidemiology and Natural History:
  - With increased coronary reperfusion, incidence has declined to 0.2%
  - 50% occur with anterior MIs (VSD located in the apical septum) and 50% occur with inferior MIs (VSD located in the basal inferior septum)
  - Risk factors: single vessel disease, first myocardial infarction (due to lack of collaterals), and extensive myocardial damage
  - Increased mortality with inferobasal VSDs compared with anterior apical VSDs.

## VENTRICULAR SEPTAL DEFECTS

- Clinical Manifestations:
  - Chest pain
  - Shortness of breath without frank pulmonary congestion
  - Tachycardia and hypotension
  - Signs of right-sided heart failure including elevated jugular venous pressure, right-sided S3, and/or RV lift
  - New, harsh holosystolic murmur with widespread radiation
  - Thrill (50% of patients)

## VENTRICULAR SEPTAL DEFECTS

- Diagnosis:
  - Two-dimensional echocardiography alone only has a sensitivity of 40%
  - The sensitivity of two-dimensional echocardiography is increased with the addition of Doppler color flow mapping
  - Turbulent Doppler color flow may be the only clue to a VSD as some VSDs are narrow, irregular, and serpiginous (especially in the basal inferior septum)
  - Confirmation can be made through a RHC with shunt run which shows a step-up at the ventricular level as well as giant pulmonary capillary pressure V waves because of volume overload in the setting of reduced LA compliance.

## VENTRICULAR SEPTAL DEFECTS

- Treatment:
  - Medical: vasodilators, diuretics, IABP
  - Surgical<sup>\*\*</sup>: patch repair +/- coronary artery bypass grafting
  - Percutaneous closure<sup>\*\*</sup>  
(\*<sup>\*\*</sup> in the absence of cardiogenic shock the optimal timing for repair is still controversial)

## CLINICAL COURSE

- The patient underwent a surgical repair of the VSD with coronary artery bypass grafting (LIMA-LAD, SVG-RCA)
- The patient did well post-operatively and was ultimately discharged home

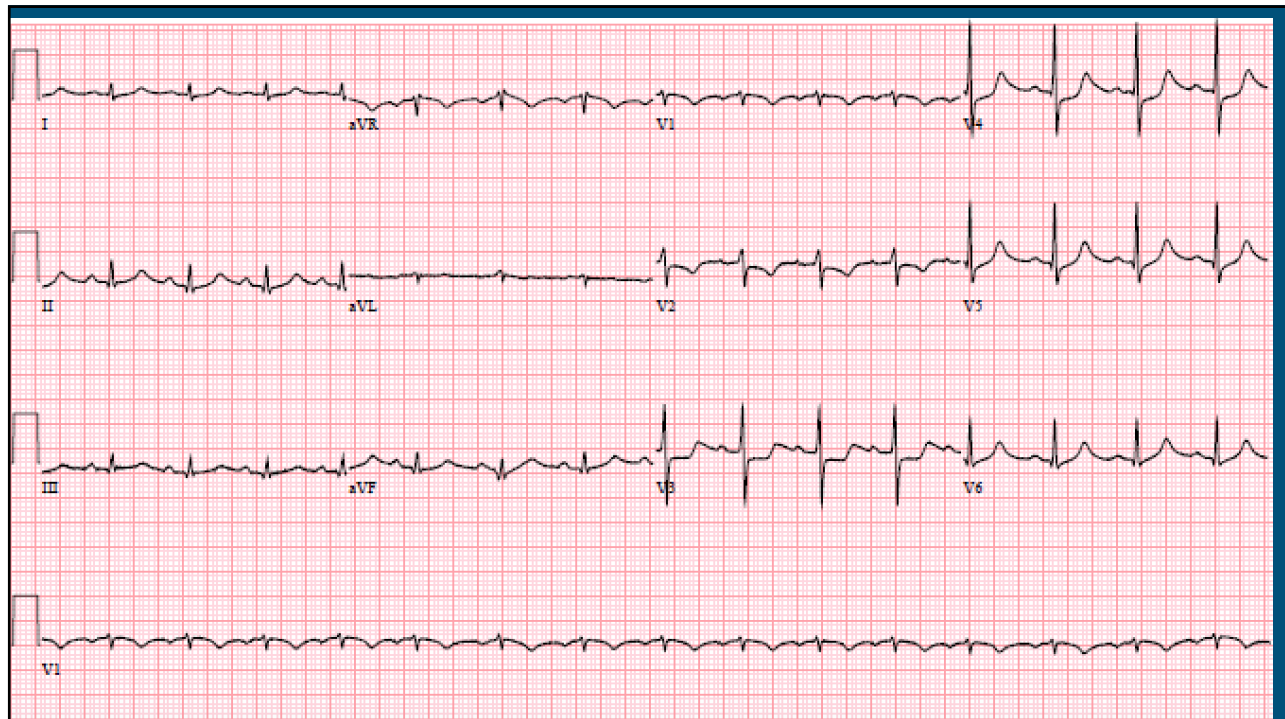
## CASE 2

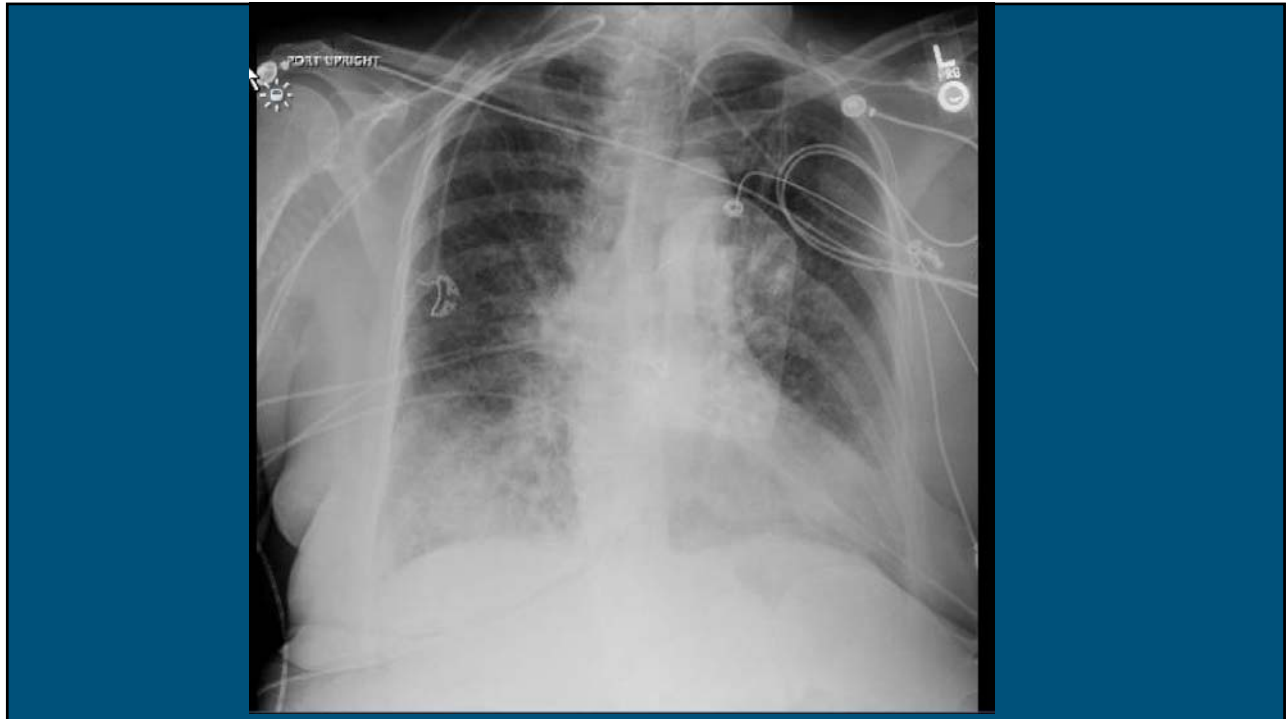
### PRESENTATION

- 67 yo female with a past medical history of hypertension, hyperlipidemia, and tobacco use presented with acute onset shortness of breath
- 4-5 days prior to admission the patient developed “flu-like” symptoms with fatigue, myalgias, back and shoulder pain, and shortness of breath
- On the morning of admission the patient developed acute worsening of her shortness of breath so she presented to the emergency department

## PRESENTATION

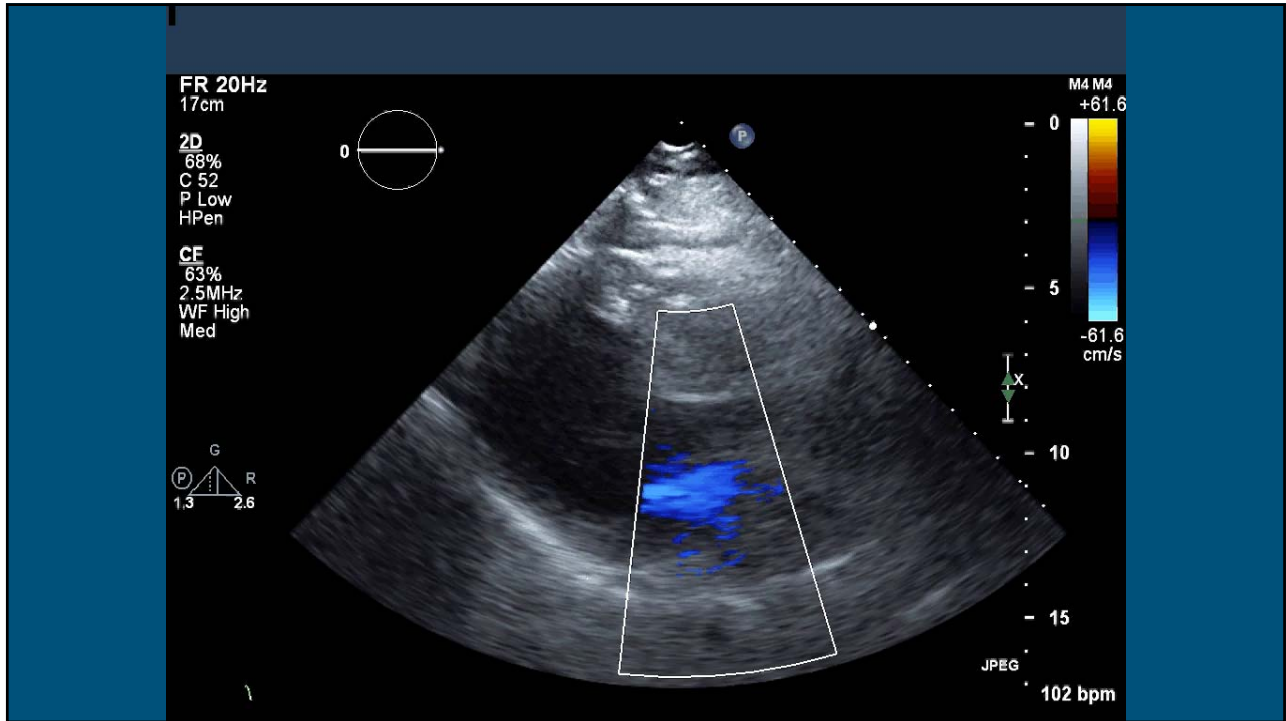
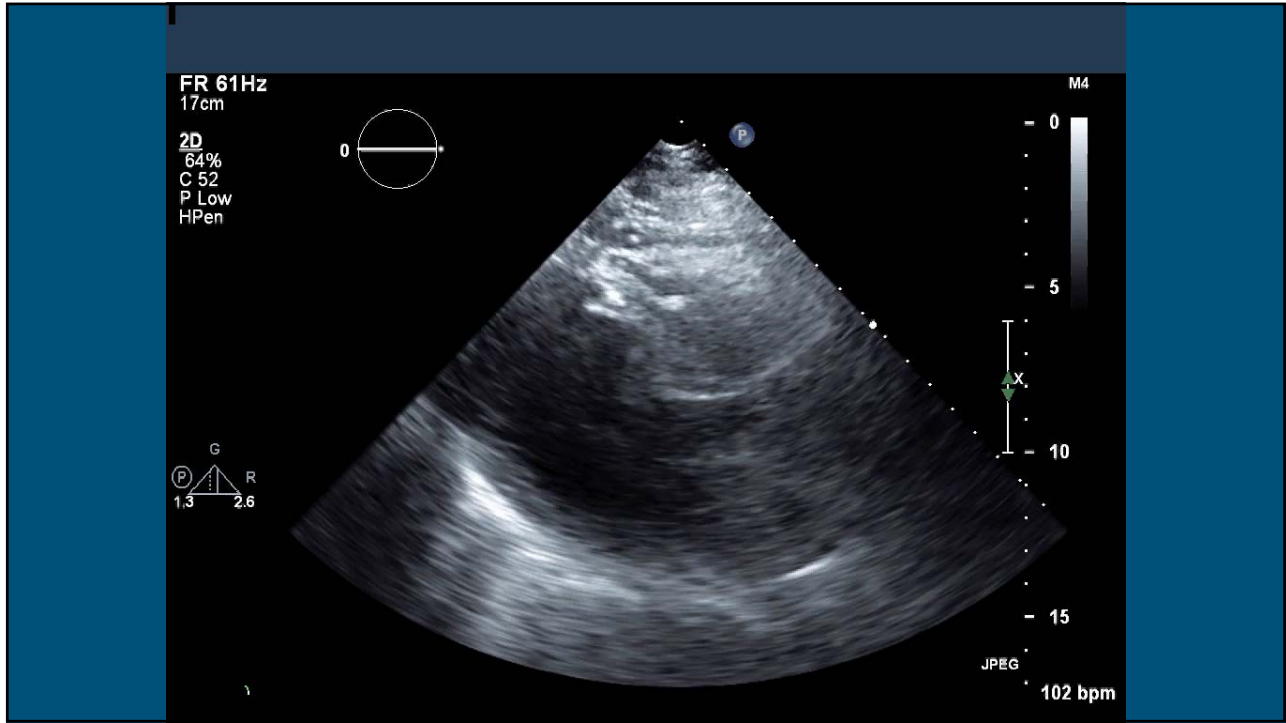
- The patient's vital signs upon arrival to the emergency department were notable for a systolic blood pressure of 90 mmHg and an oxygenation saturation of 70% on RA
- Physical exam was notable for a III/VI holosystolic murmur heard over the apex, coarse rhonchi R>L, and mottled cold extremities
- Initial lab work was notable for a lactate of 14.8 mmol/L, central venous O<sub>2</sub> Sat 85.8%, troponin T of 3.53 ng/ml, and a WBC of 22.89 K/uL

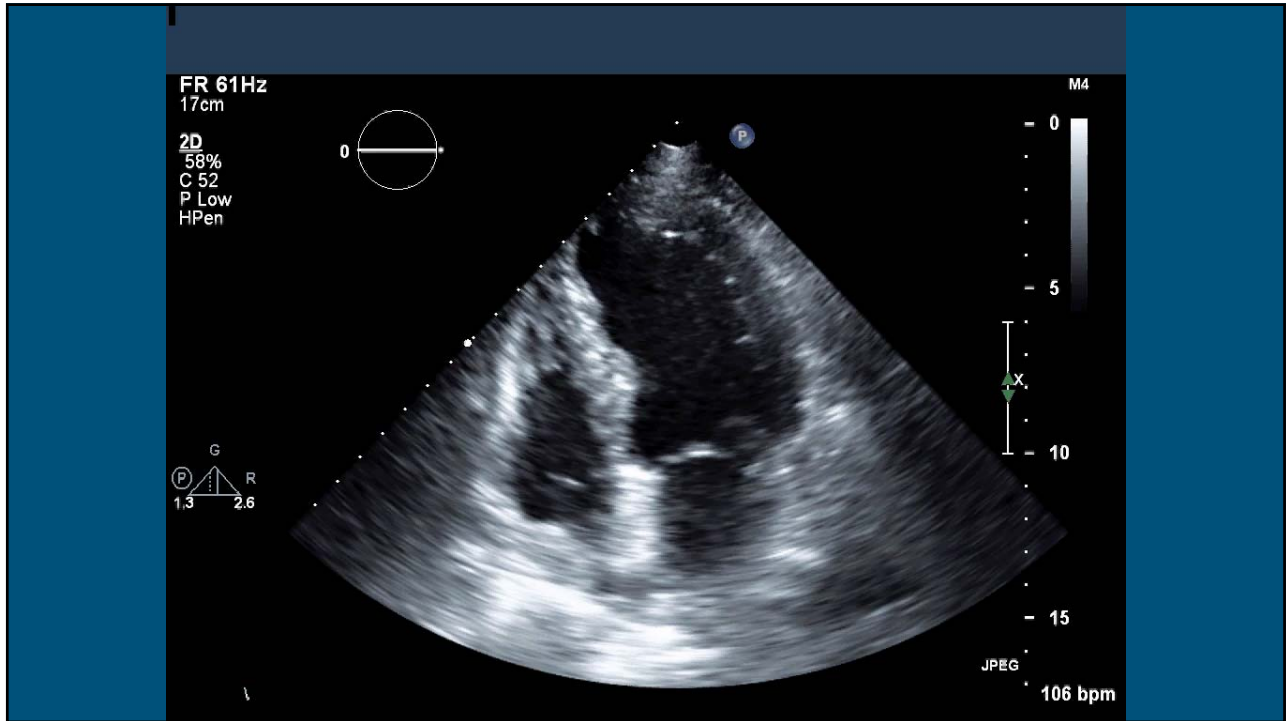
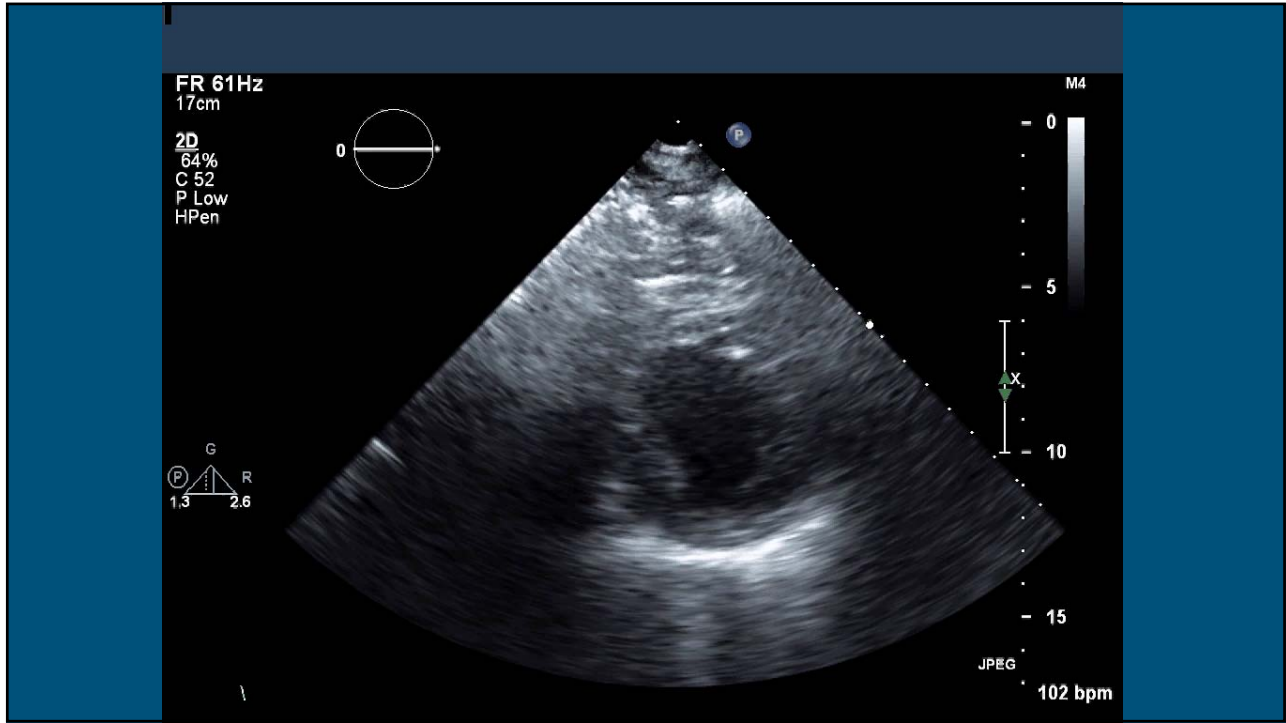




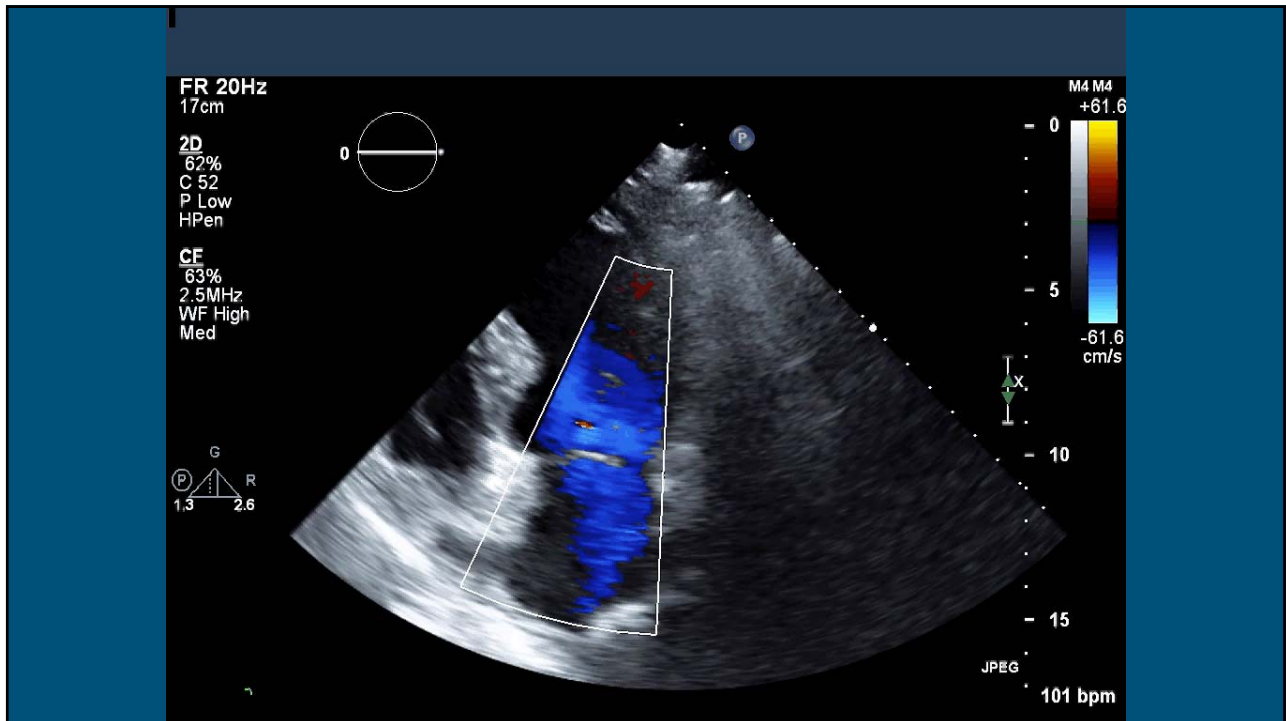
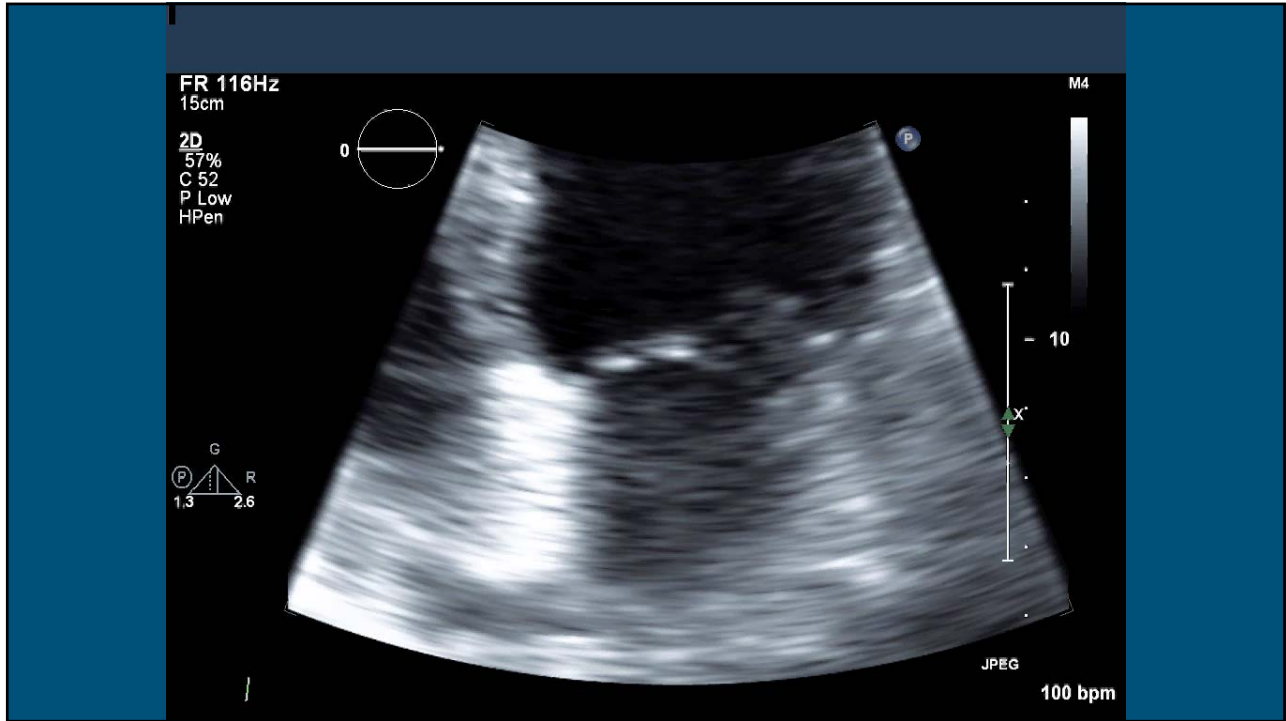
## PRESENTATION

- The patient was diagnosed with septic shock from a right lower lobe pneumonia and started on ceftriaxone and azithromycin
- Over the next 6 hours the patient developed worsening hypoxemic respiratory failure and hypotension
- She was sent for a PE protocol CT scan of the chest which showed: no evidence of pulmonary embolism or aortic dissection and extensive groundglass opacities, worst at the right lower lobe, consistent with multifocal pneumonia
- A TTE was requested to evaluate cardiac function

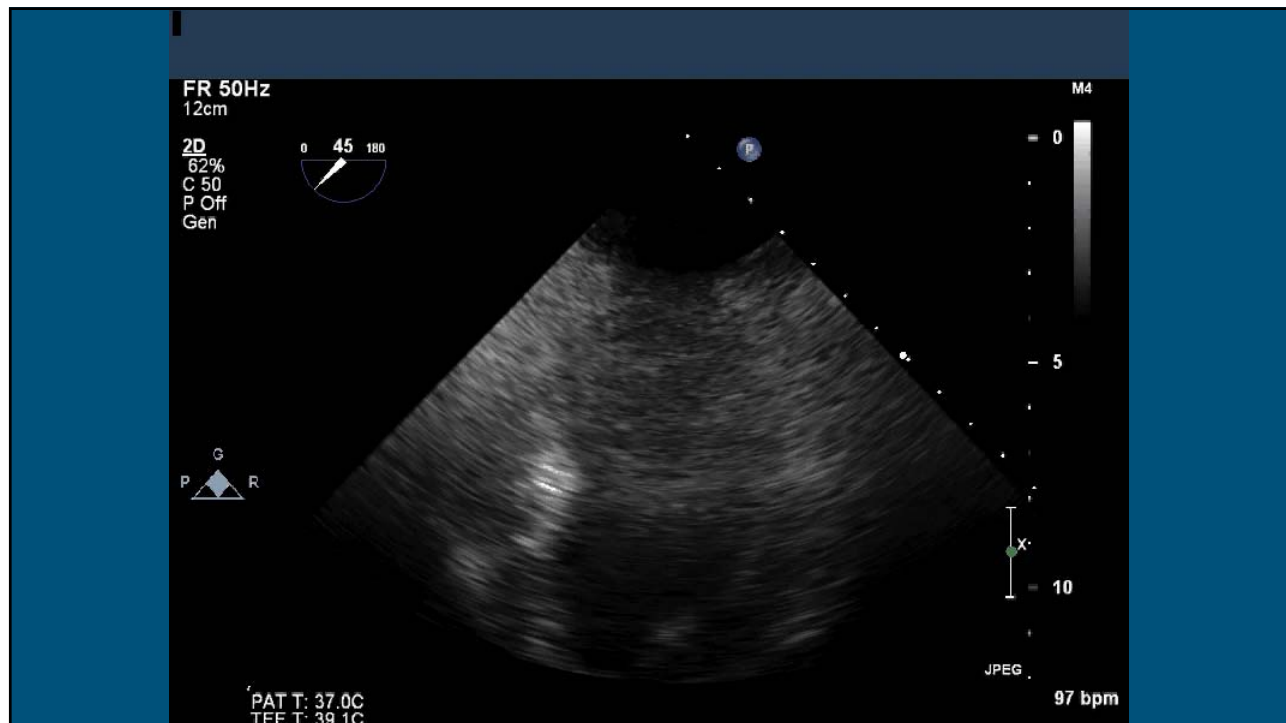


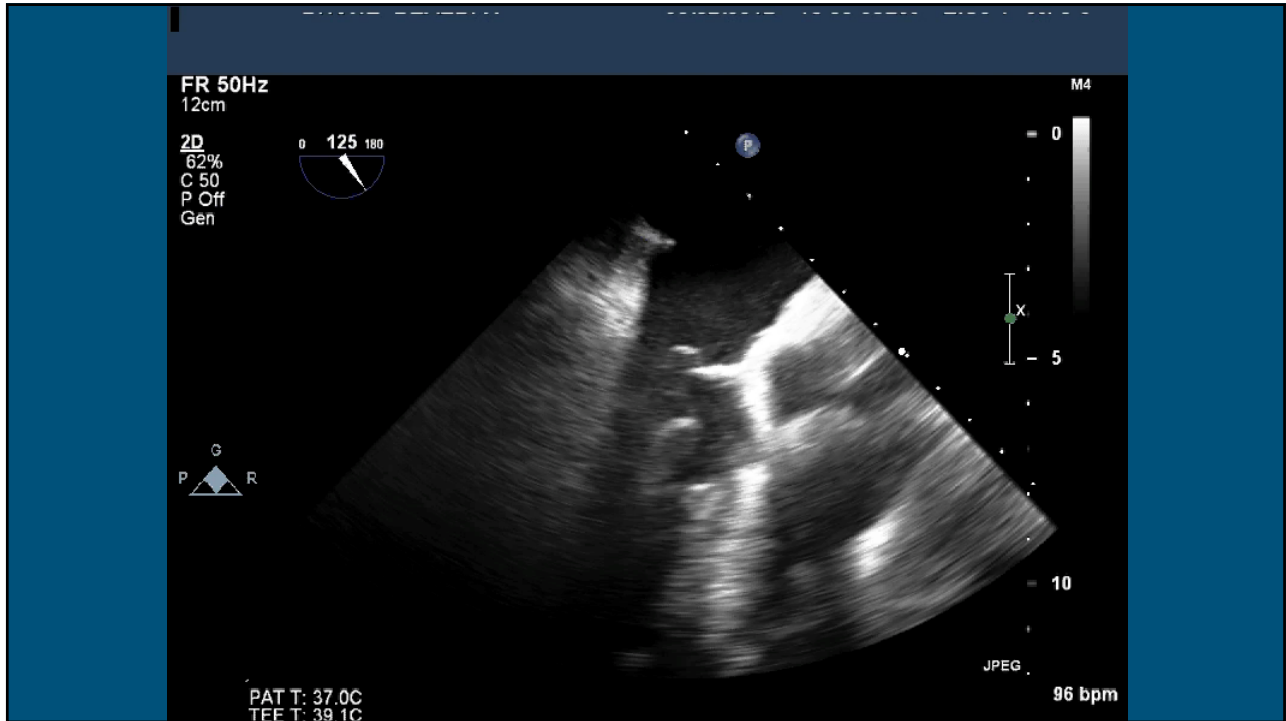
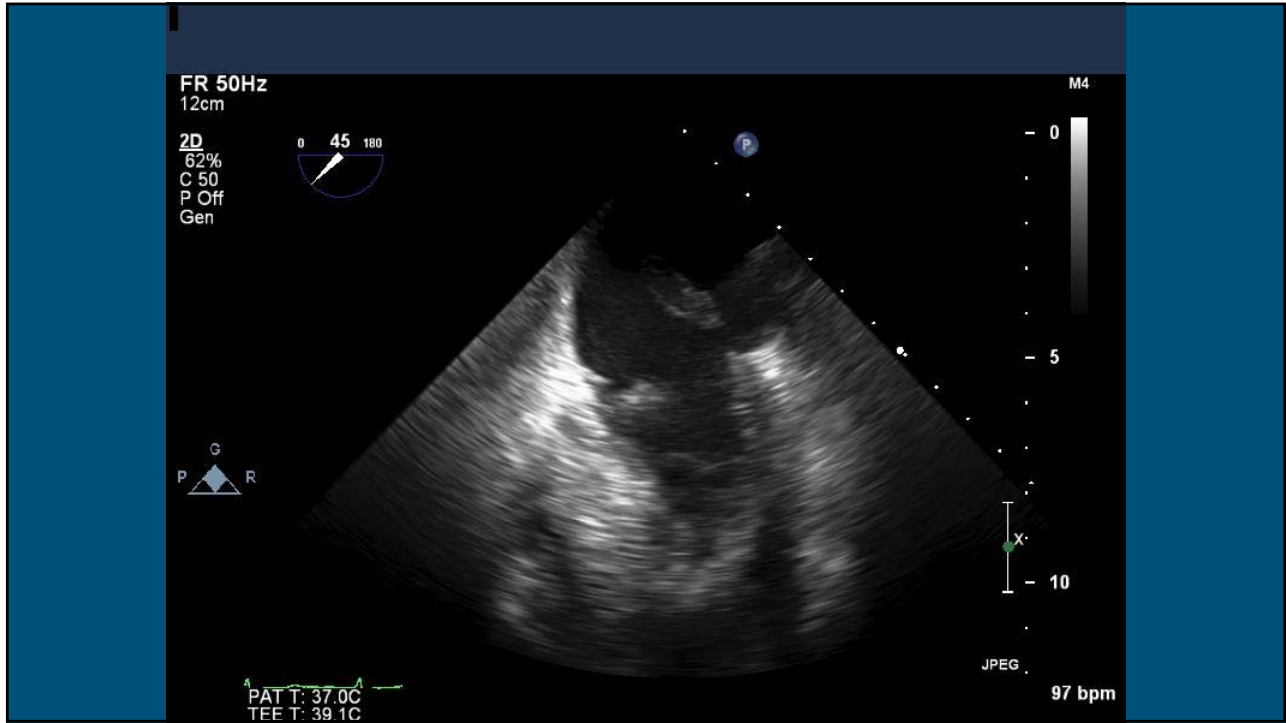


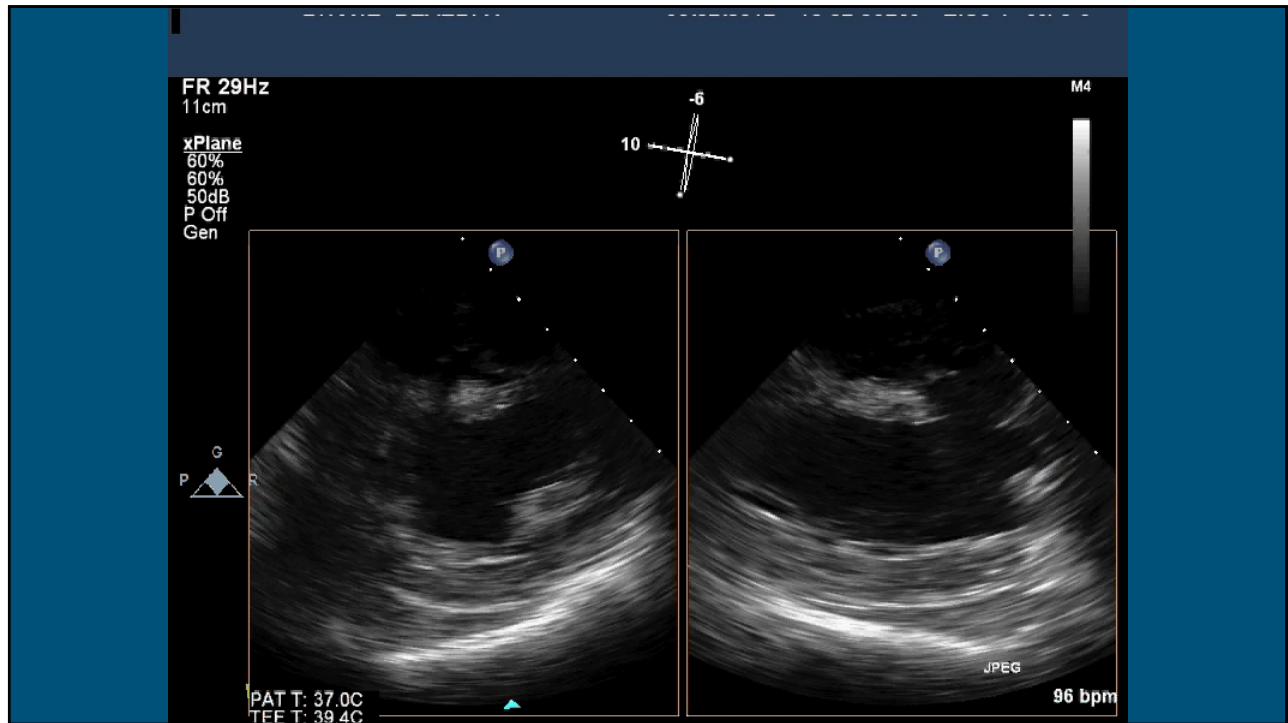
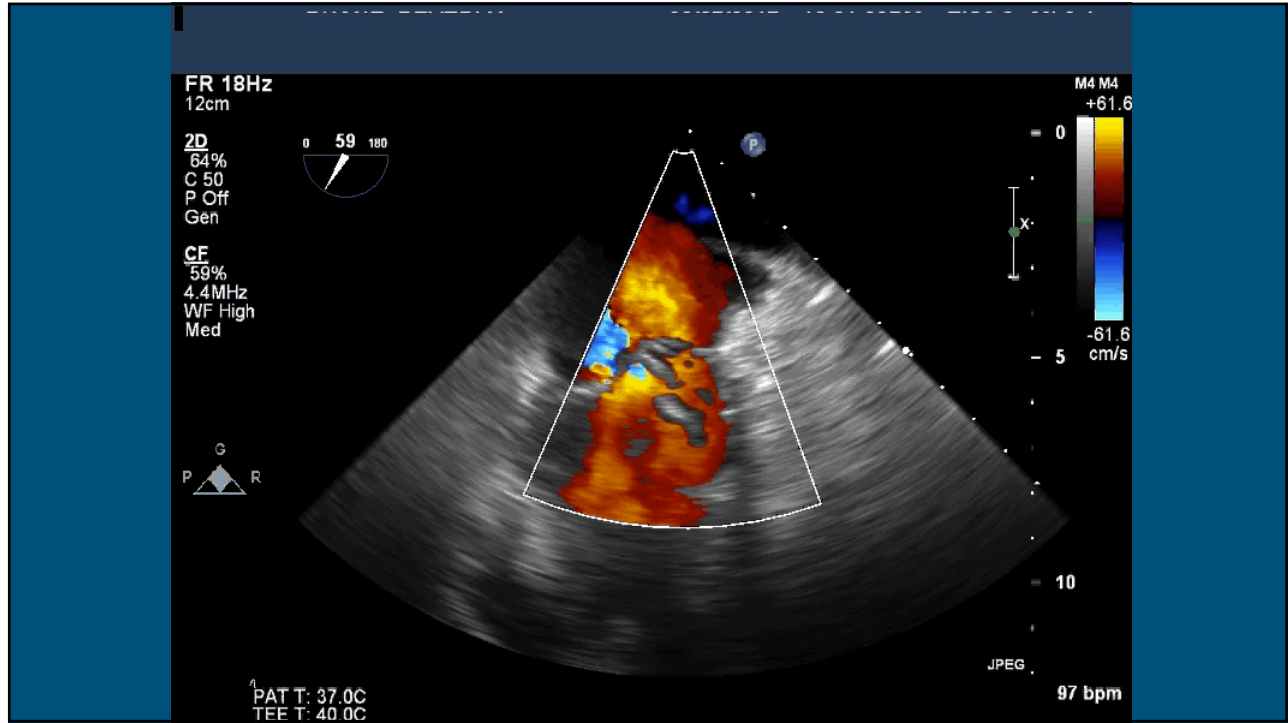


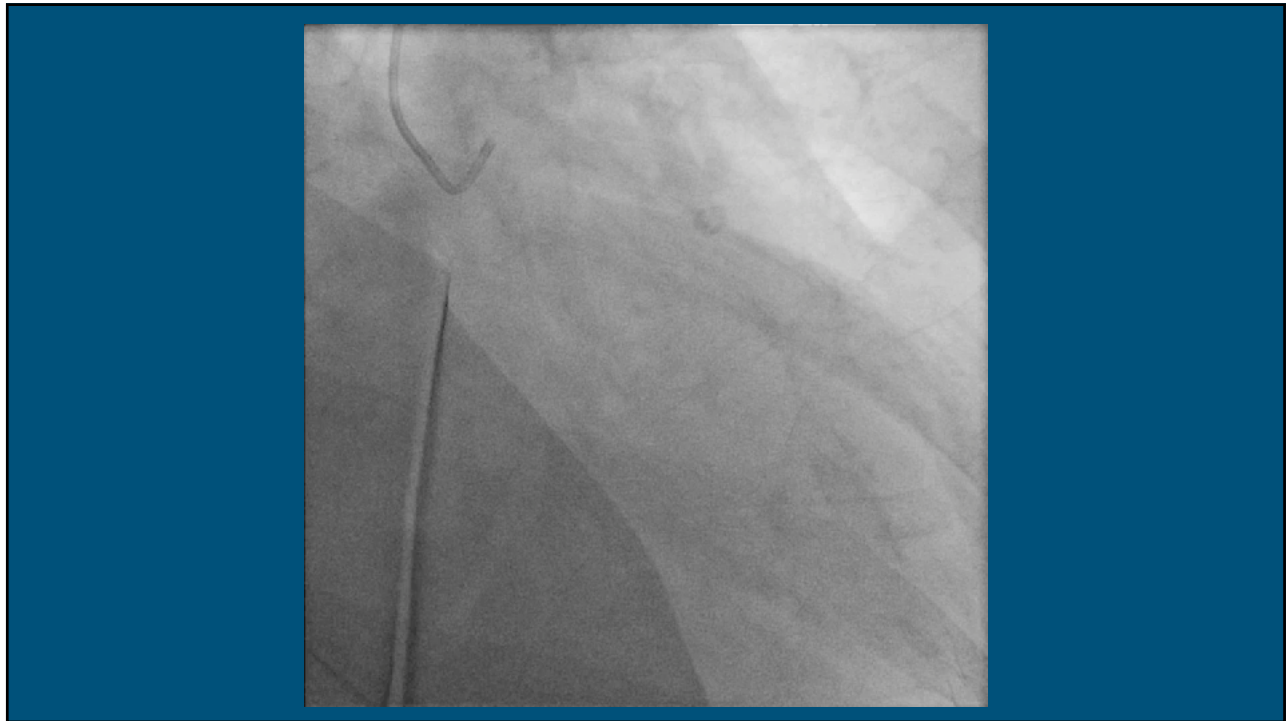
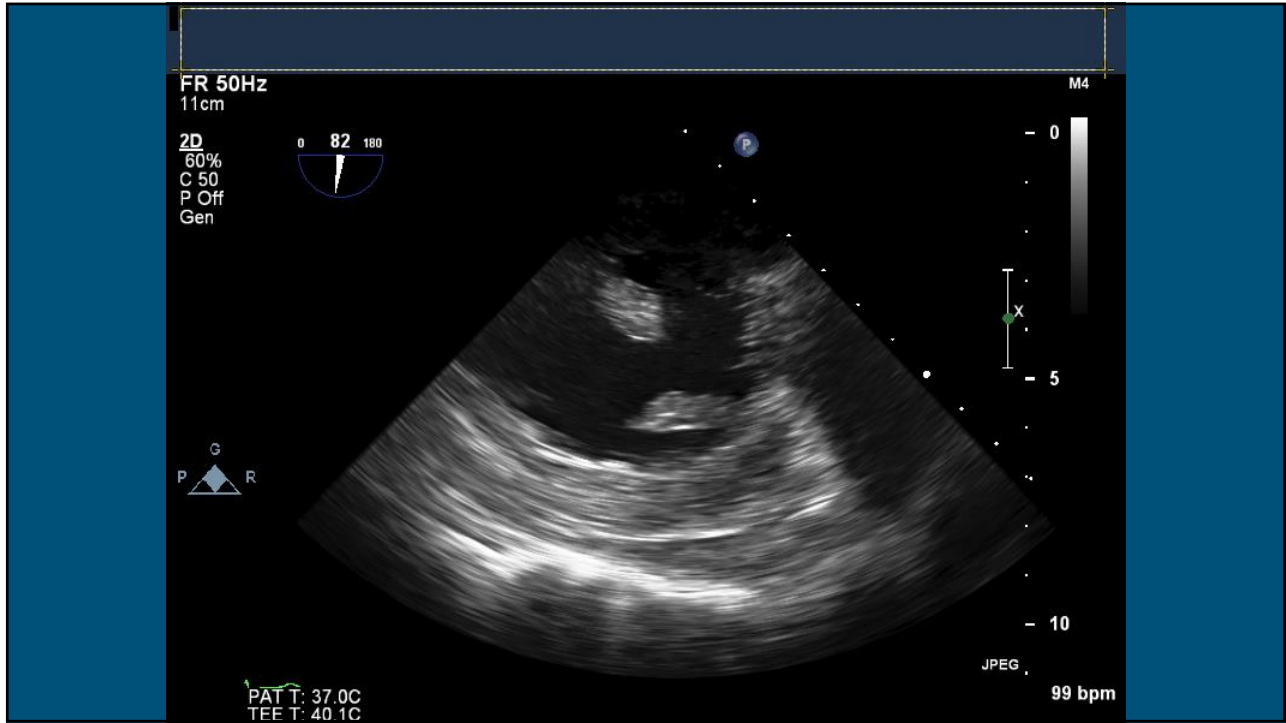


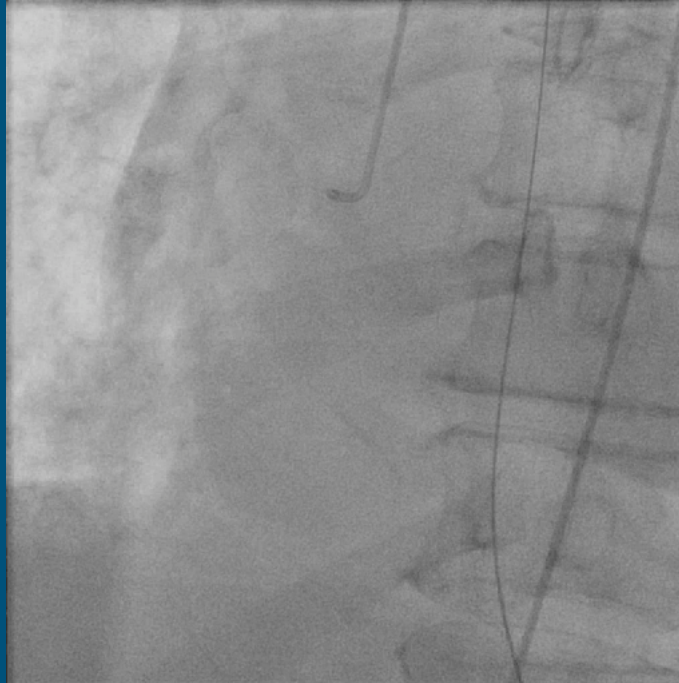WHAT WOULD YOU RECOMMEND  
AS THE NEXT STEP IN THE  
MANAGEMENT OF THIS PATIENT?











## PAPILLARY MUSCLE RUPTURE

- Epidemiology and Natural History:
  - Accounts for approximately 5% of all deaths after myocardial infarction
  - Most often occurs 2-7 days after myocardial infarction
  - Posteromedial papillary muscle is affected 6-12x more often than the anterolateral papillary muscle secondary to differences in blood supply (posteromedial papillary muscle is supplied by the PDA, anterolateral papillary muscle is supplied by the LAD/LCx)
  - 50% of patients have single-vessel disease and for most patients it occurs with their first myocardial infarction

## PAPILLARY MUSCLE RUPTURE

- Clinical Manifestations:
  - Chest pain and/or shortness of breath
  - Tachycardia, hypotension and hypoxemic respiratory failure with an inability to lie flat
  - Asymmetric pulmonary edema
  - New, mid/late/holosystolic murmur with widespread radiation
  - End-organ malperfusion (renal failure, shock liver, mottled cold extremities)

## PAPILLARY MUSCLE RUPTURE

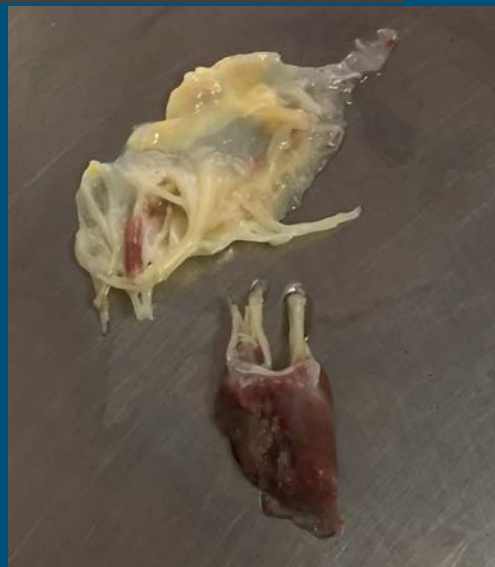- Diagnosis:
  - Suspected on TTE based on the presence of a hyperdynamic left ventricle, flail mitral valve, eccentric severe mitral regurgitation, and freely mobile chordae or papillary muscle in the left ventricle
  - Ruptured papillary muscle can often be best visualized by TEE

## PAPILLARY MUSCLE RUPTURE

- Treatment:
  - Medical: vasodilators, diuretics, IABP (75% mortality at 24 hours, 95% mortality at 2 weeks)
  - Surgical: mitral valve repair/replacement +/- coronary artery bypass grafting (50% mortality)

## CLINICAL COURSE

- Approximately 24 hours after presentation the patient was taken to the operating room for mitral valve replacement and coronary artery bypass grafting (SVG-RCA)





## CLINICAL COURSE

- Despite surgical intervention the patient continued to have multi-organ failure including cardiogenic shock requiring multiple inotropes
- After extensive discussions with the patient's family, the decision was made to withdrawal support and the patient passed away

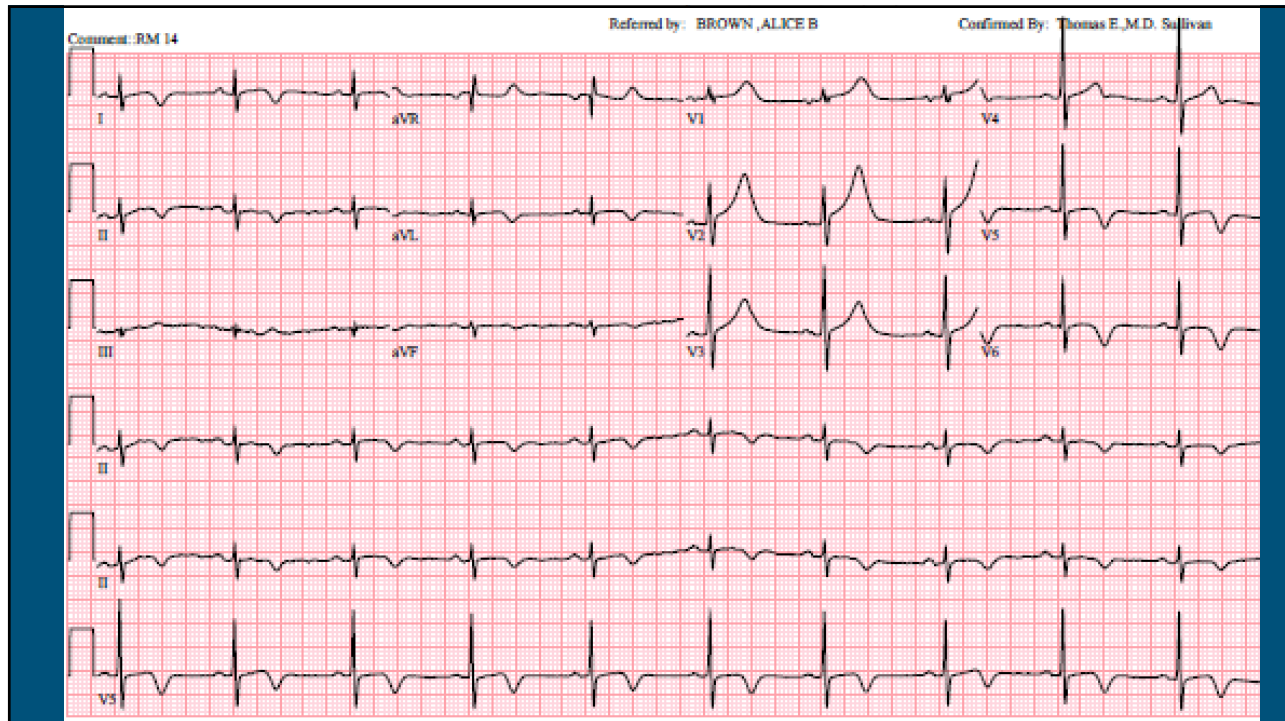
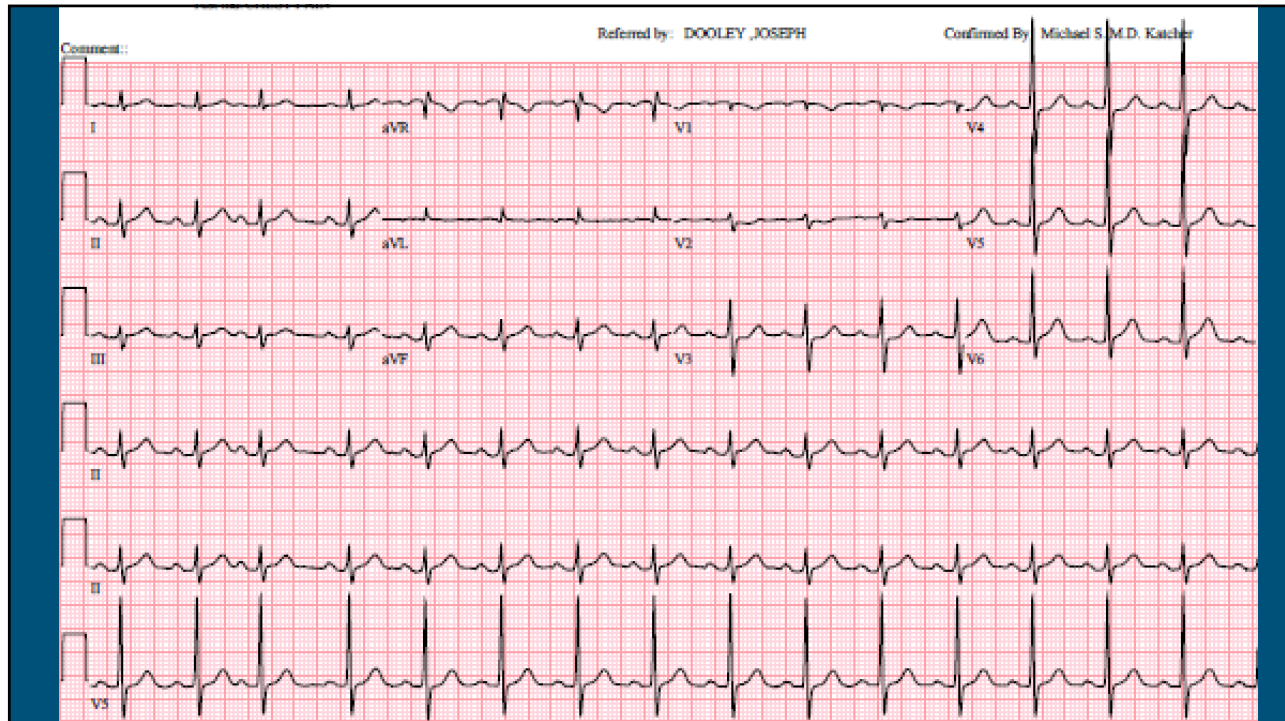
## CASE 3

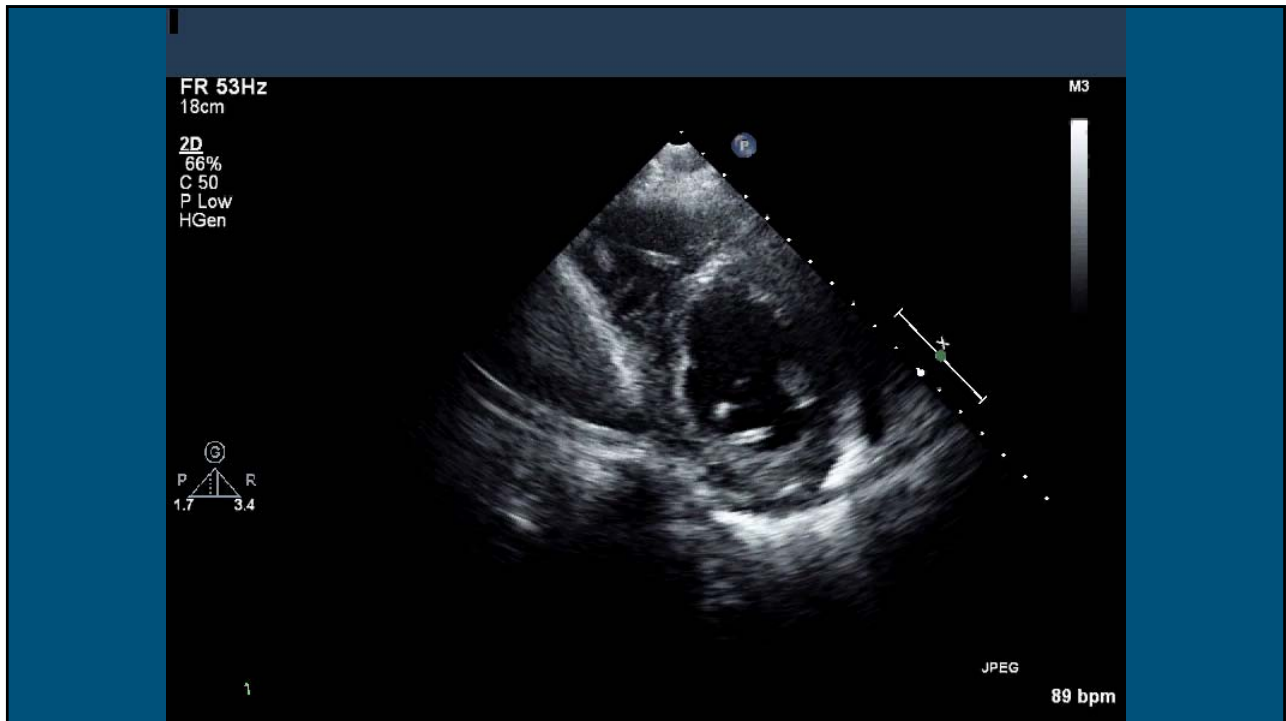
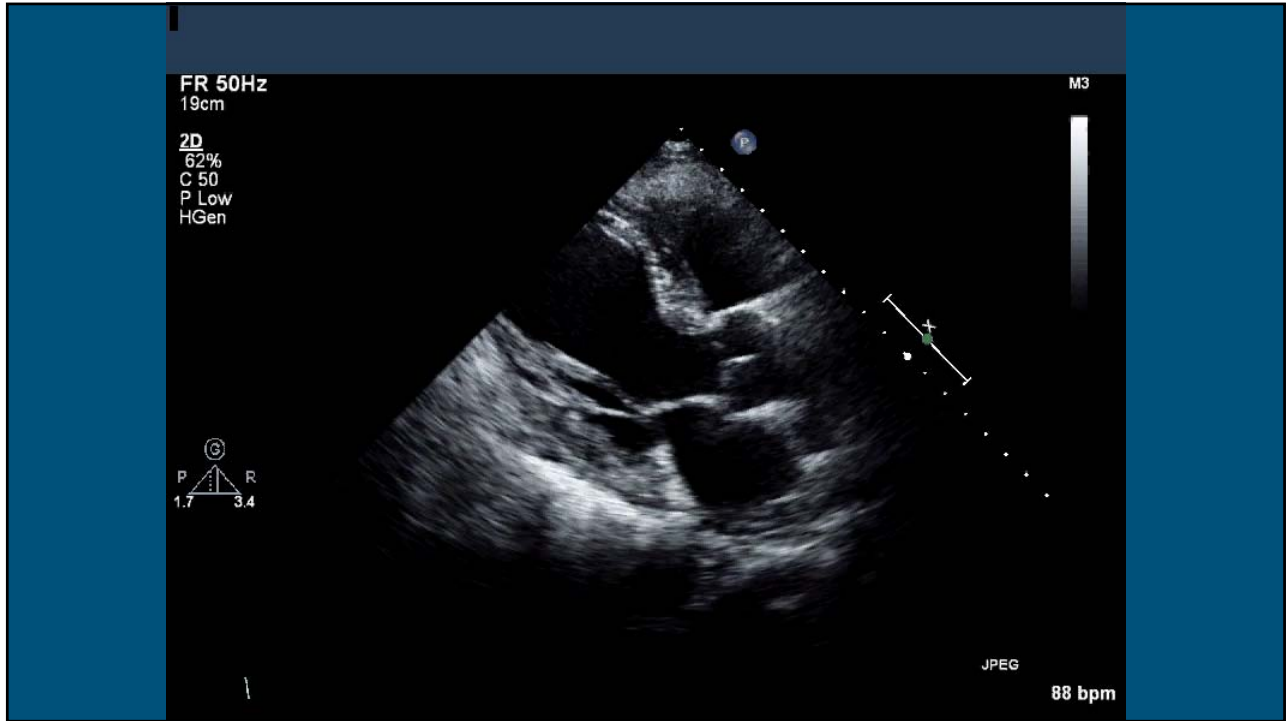
## PRESENTATION

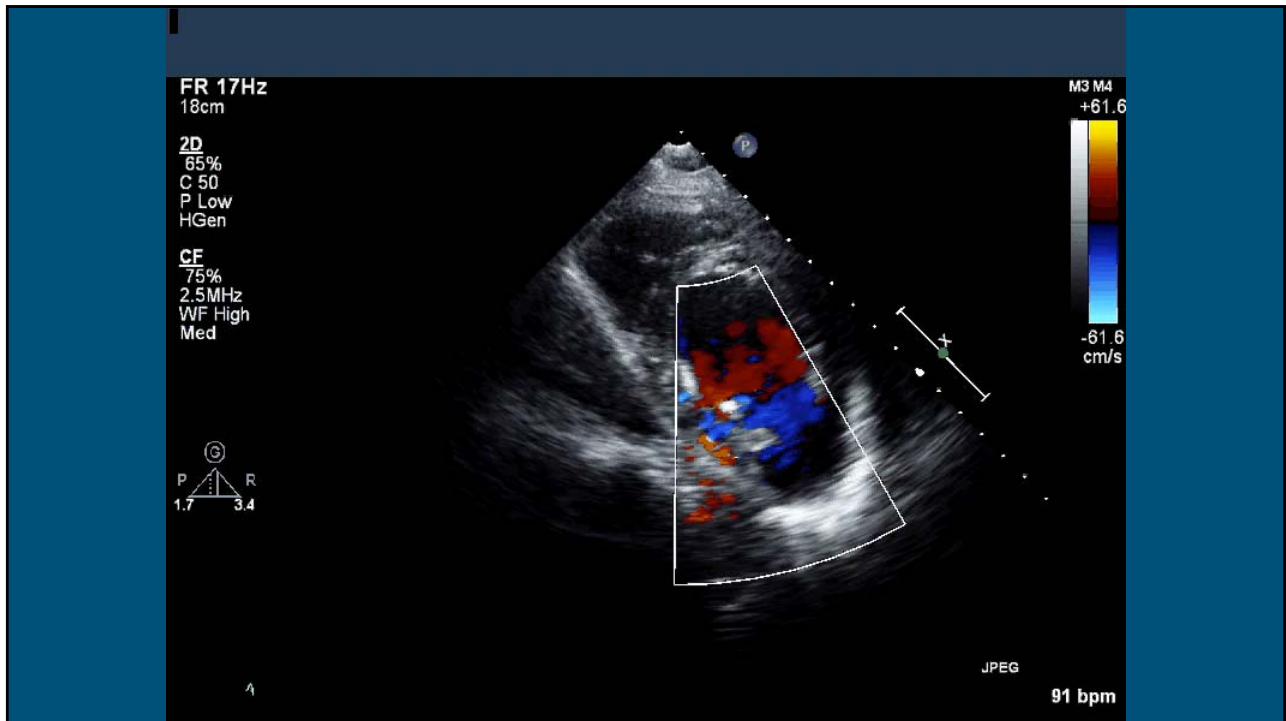
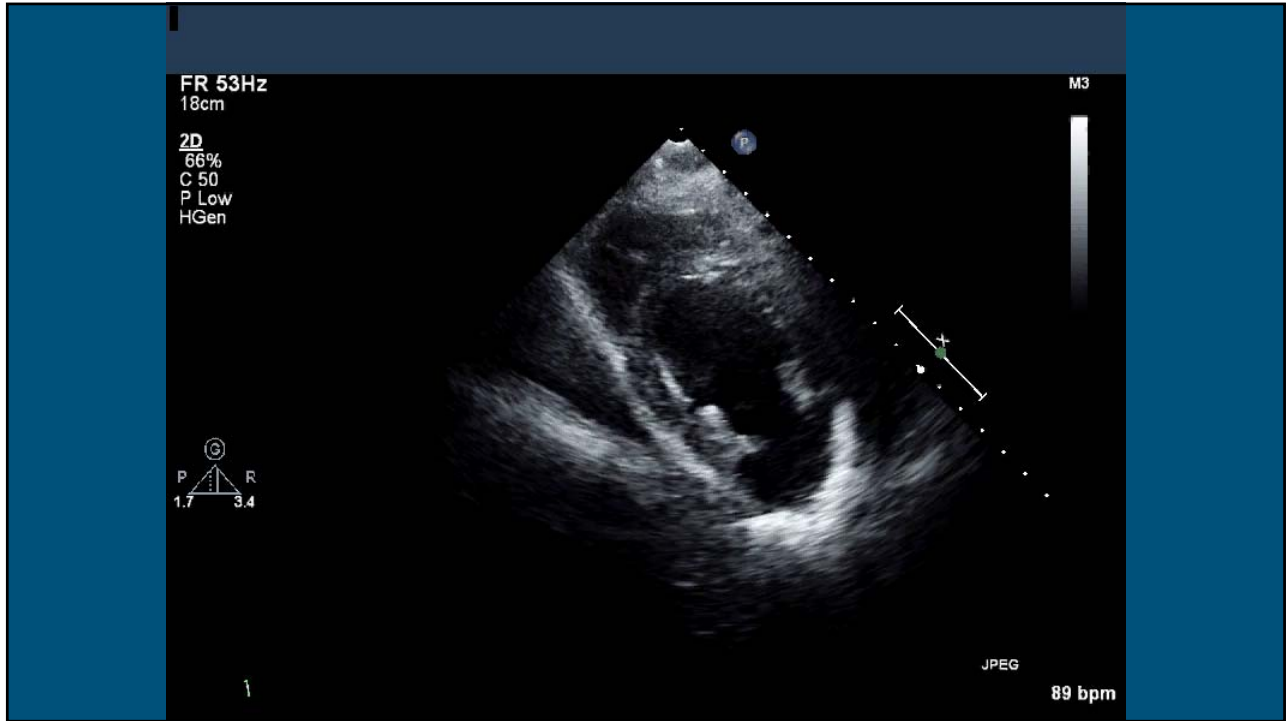
- 71 yo male with a past medical history of hypertension and tobacco use presented with substernal chest pain
- One day prior to presentation the patient developed substernal chest pain that radiated to the back
- After the symptoms had not resolved by the next morning, the patient presented to the emergency room for evaluation

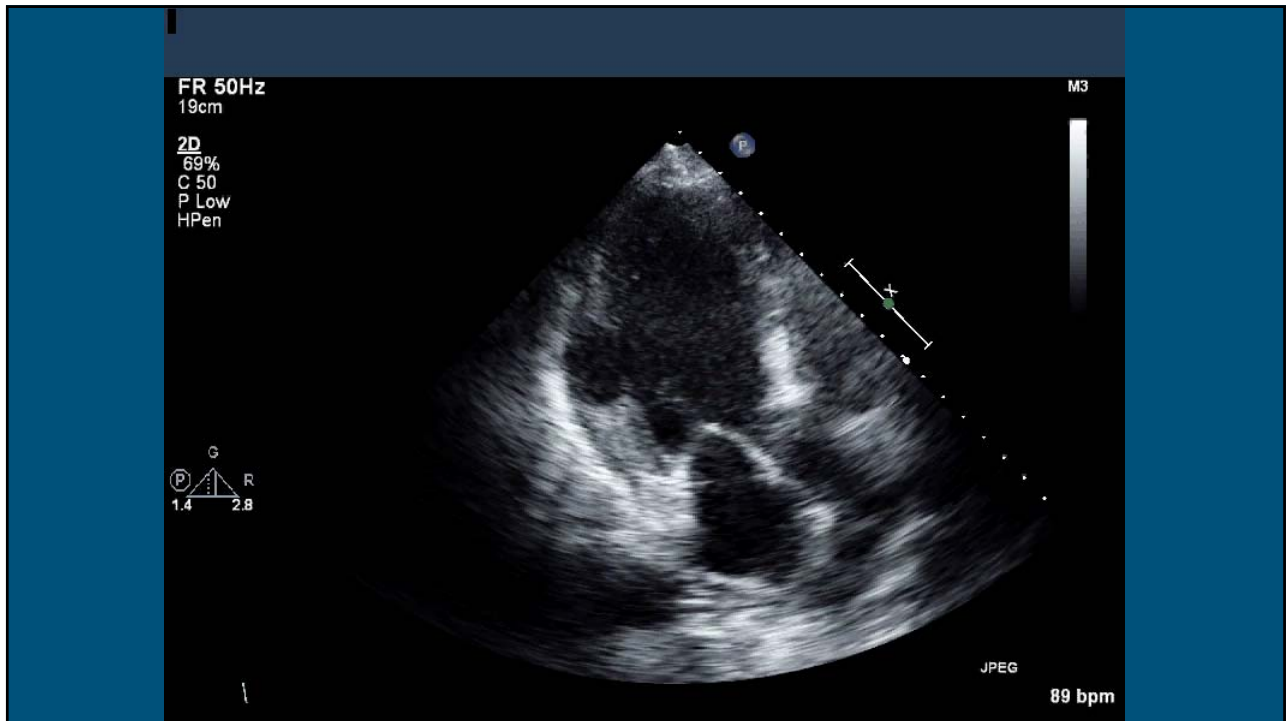
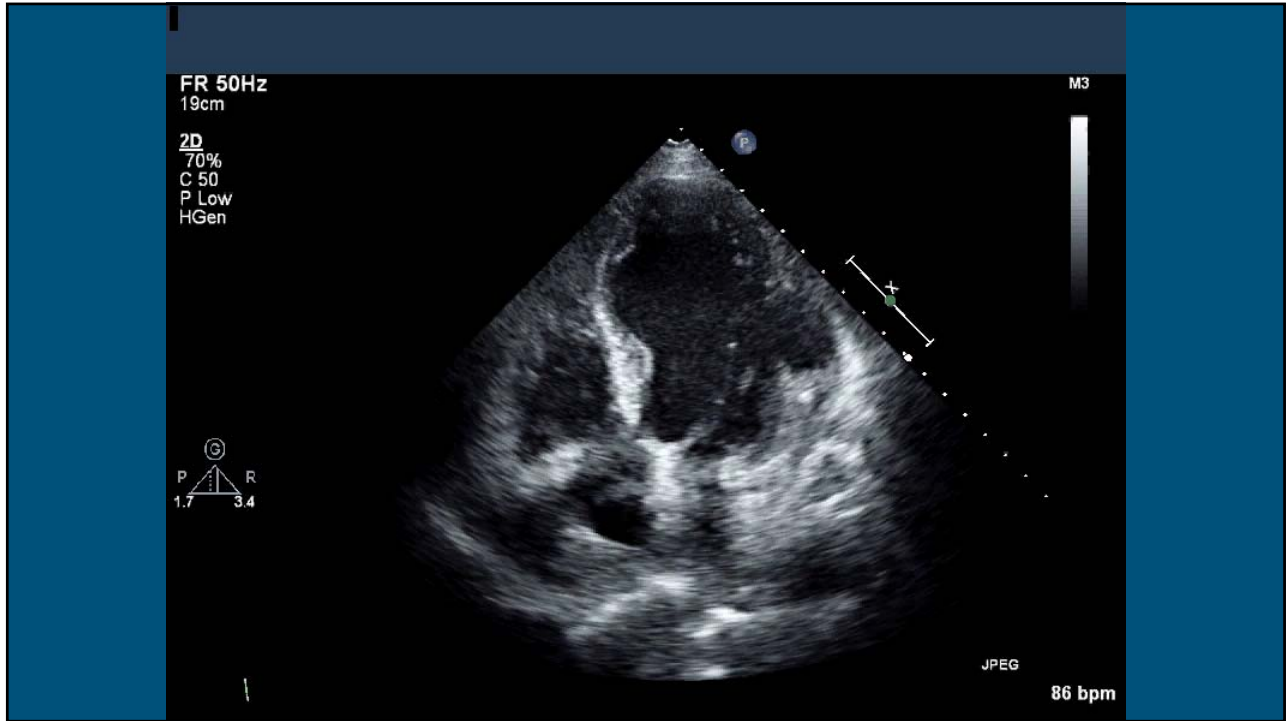
## PRESENTATION

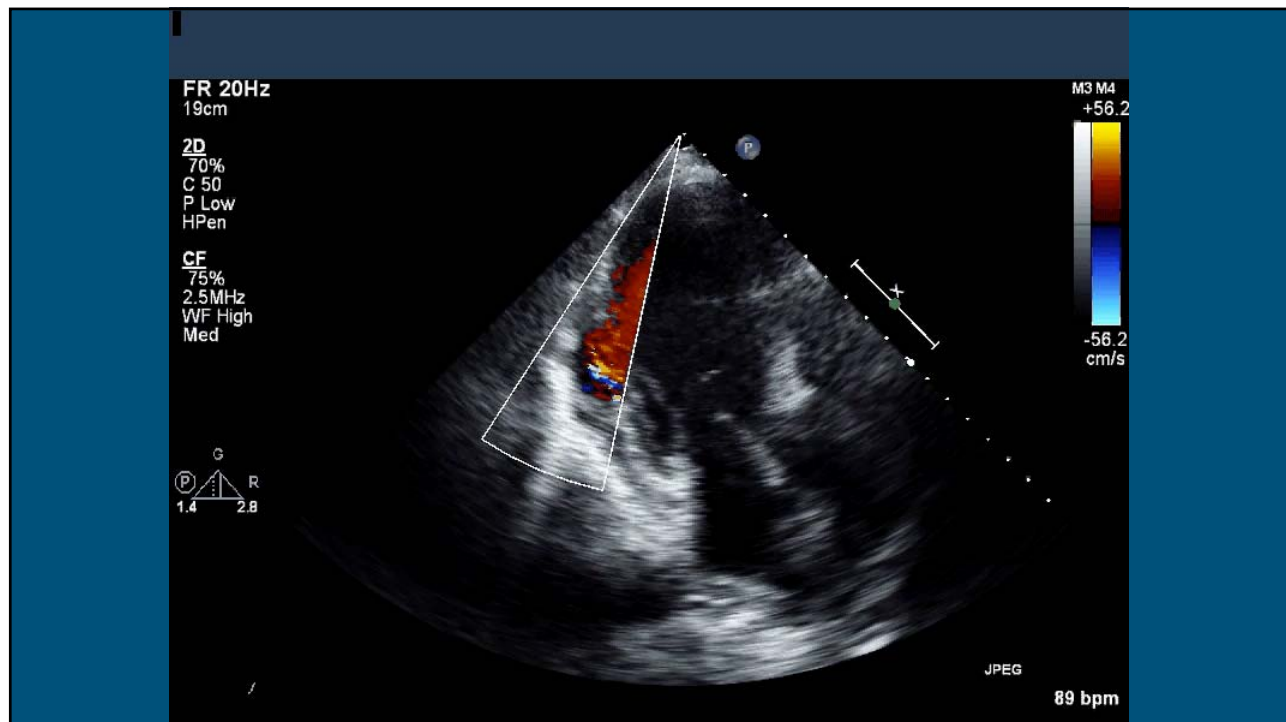
- The patient's vital signs and physical exam on presentation were within normal limits
- The patient's initial troponin T was negative











THIS PATIENT'S  
ECHOCARDIOGRAPHY FINDING IS  
MOST LIKELY TO BE CAUSED BY AN  
OCCLUSION IN WHICH  
CORONARY ARTERY?

## PRESENTATION

- The patient was sent for a cardiac catheterization which showed: diffuse nonobstructive disease in the RCA, 50% proximal and 60% distal LAD stenoses, 100% occlusion of OMI, and patent OM2 and OM3

## PSEUDOANEURYSM

- Epidemiology and Natural History:
  - Ventricular free wall rupture that is contained by localized pericardium, adhesions, and/or thrombus (does not contain endocardium or myocardium)
  - Most commonly seen in the inferior or inferolateral wall after myocardial infarction
  - 30%-45% risk of rupture without surgical repair



## PSEUDOANEURYSM

- Clinical Manifestations:
  - Chest pain and/or shortness of breath
  - Sudden cardiac death (3% of patients)
  - Asymptomatic (12% of patients)
  - New to-and-fro murmur representing flow into and out of the pseudoaneurysm during systole and diastole, respectively
  - Systemic embolization
  - New mass on CXR
  - EKG changes with nonspecific TWI being the most common (95% of patients)

## PSEUDOANEURYSM

- Diagnosis:
  - Transthoracic echocardiography only has a sensitivity of 26%
  - Transesophageal echocardiography has a sensitivity of 75%
  - Cineventriculography, cardiac CT, and cardiac MRI all have a high sensitivity and are the imaging tests of choice to confirm the diagnosis
  - Typically has a narrow neck appearance on cardiac imaging (neck diameter <40% of the maximal aneurysm diameter)

## PSEUDOANEURYSM

- Treatment:
  - Surgical repair or patch closure (<10% perioperative mortality)

## CLINICAL COURSE

- The patient was taken to the operating room where he underwent a pseudoaneurysm patch repair and coronary artery bypass grafting with SVG-LAD
- The patient has done well post-operatively

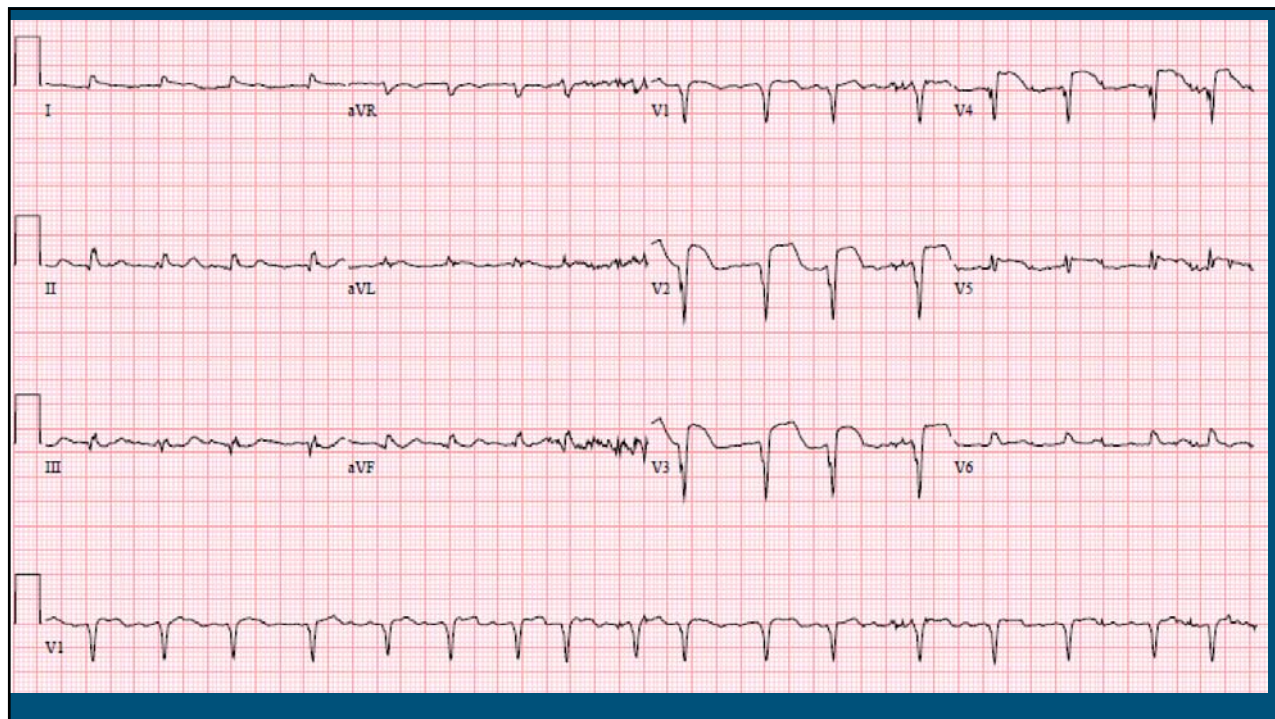
## CASE 4

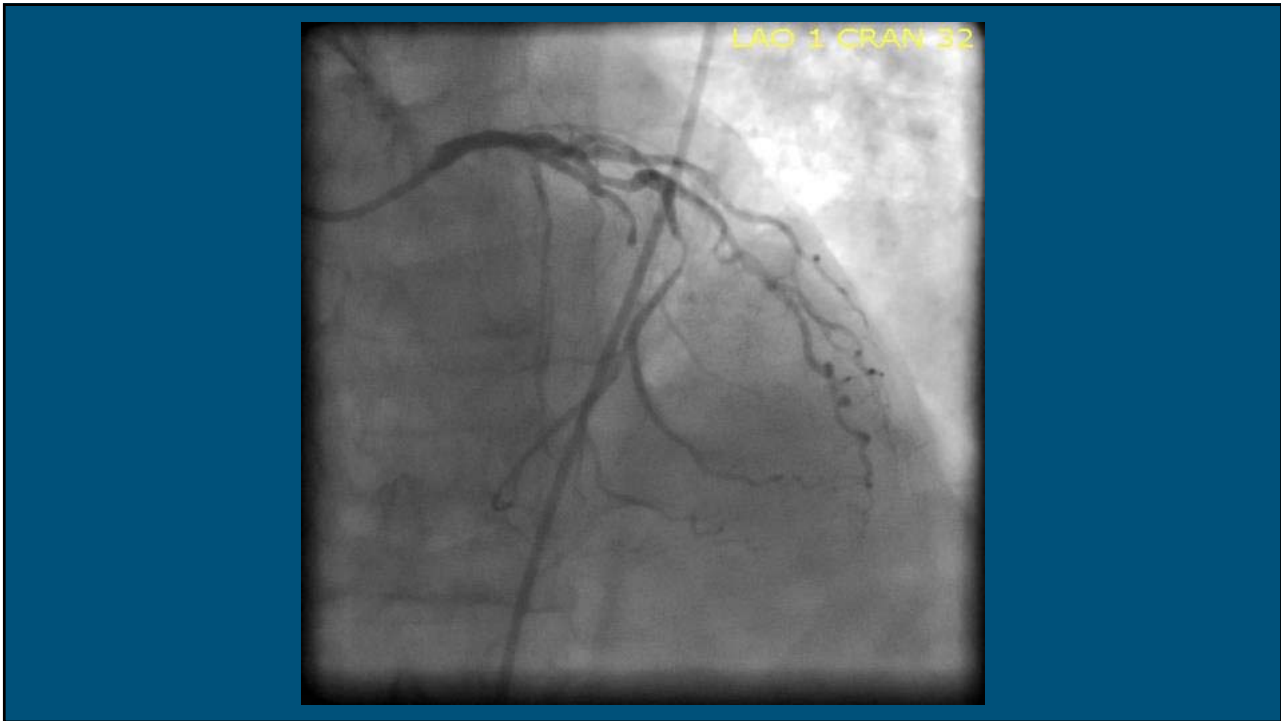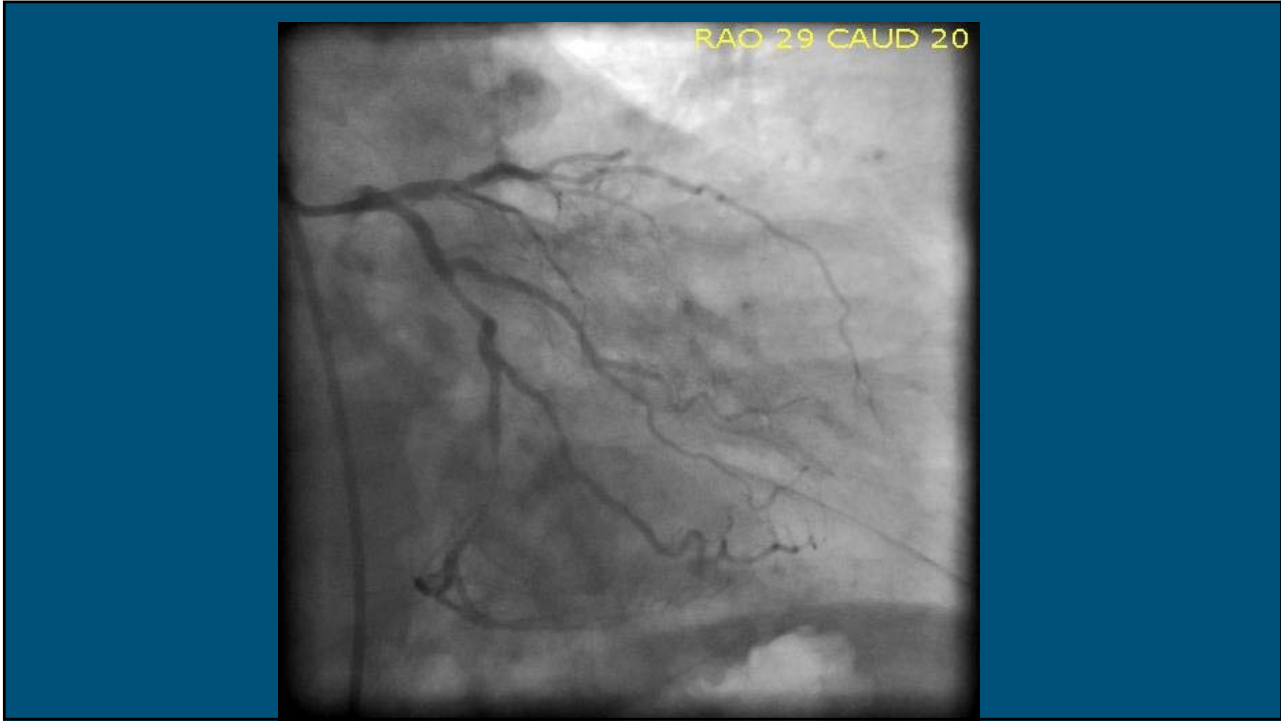
### PRESENTATION

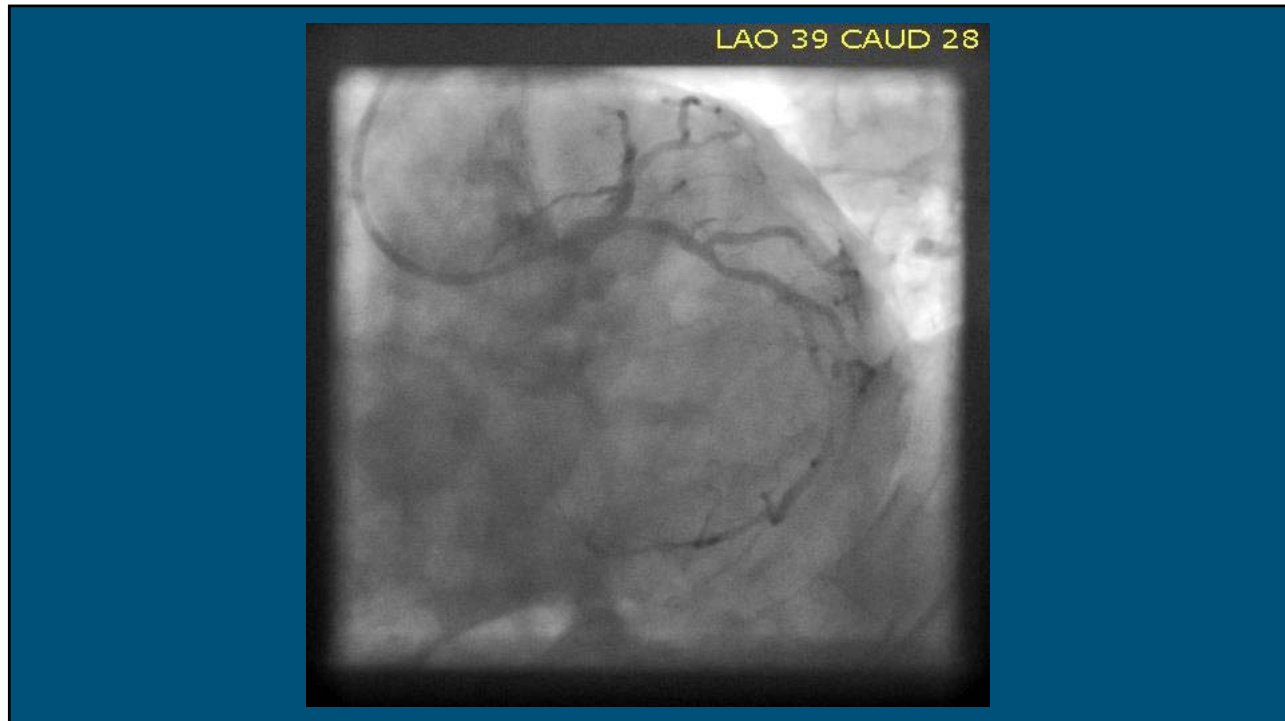- 82 yo male with a past medical history of peripheral arterial disease, hypertension, hyperlipidemia, type II diabetes, tobacco use and atrial fibrillation presented with chest pain
- 1 day prior to presentation the patient developed an achy pain in his chest that radiated down both of his arms
- When the patient's symptoms persisted the next day, he presented to the emergency department for evaluation

## PRESENTATION

- The patient's vital signs upon arrival to the emergency department were: T: 98.8, HR: 134, BP: 145/69, RR: 38, SpO2: 93% on 2L NC
- The patient's physical exam was notable for an irregularly irregular rhythm and diminished lower extremity pulses
- Initial lab work was notable for an elevated troponin T of 2.35 ng/ml

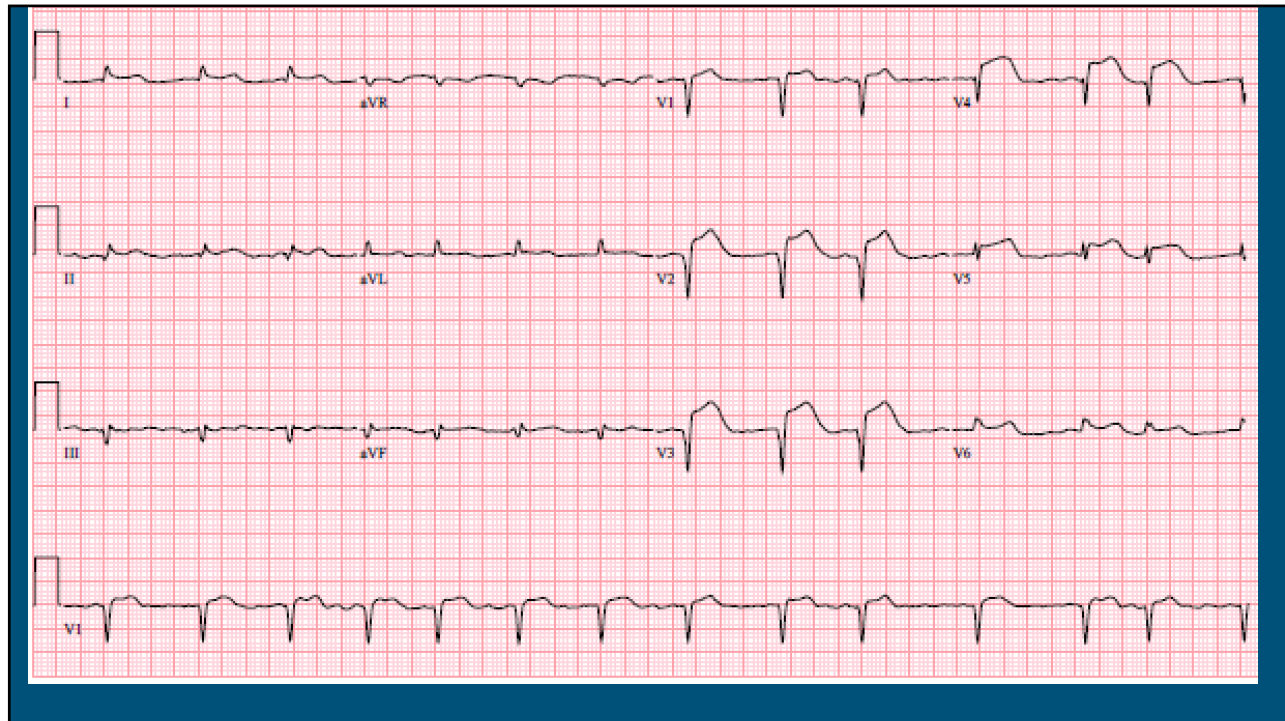




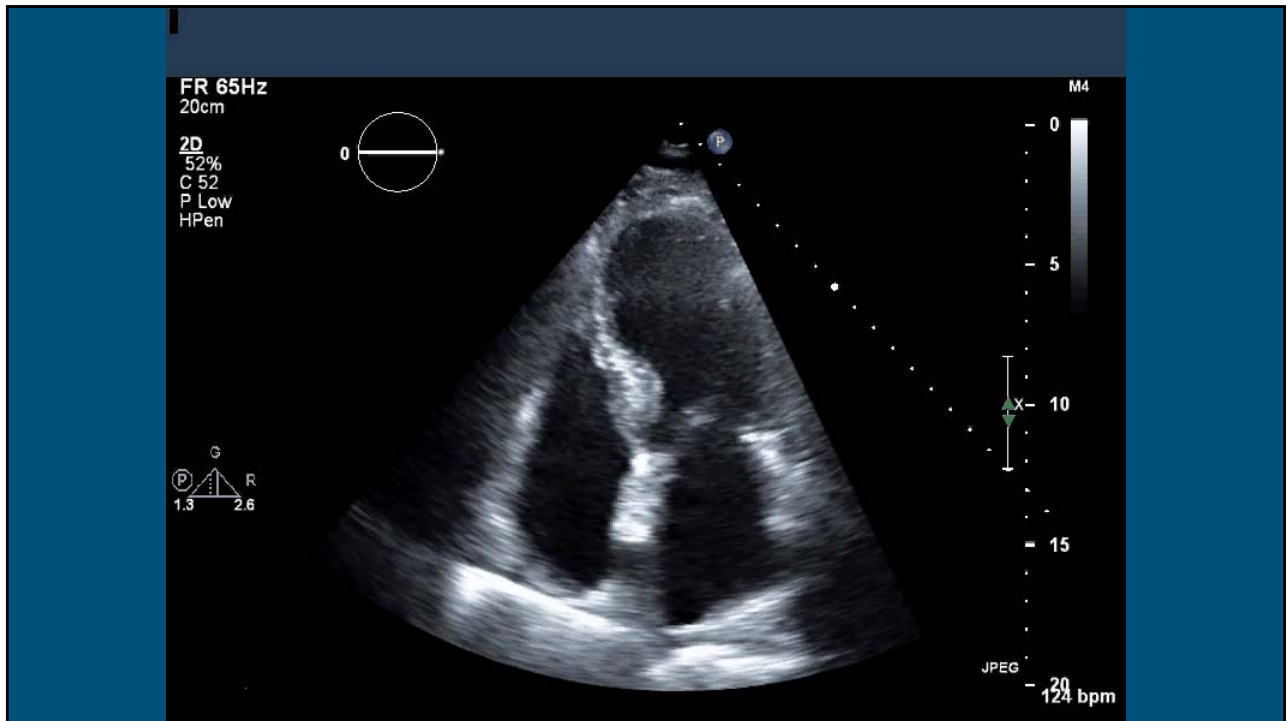
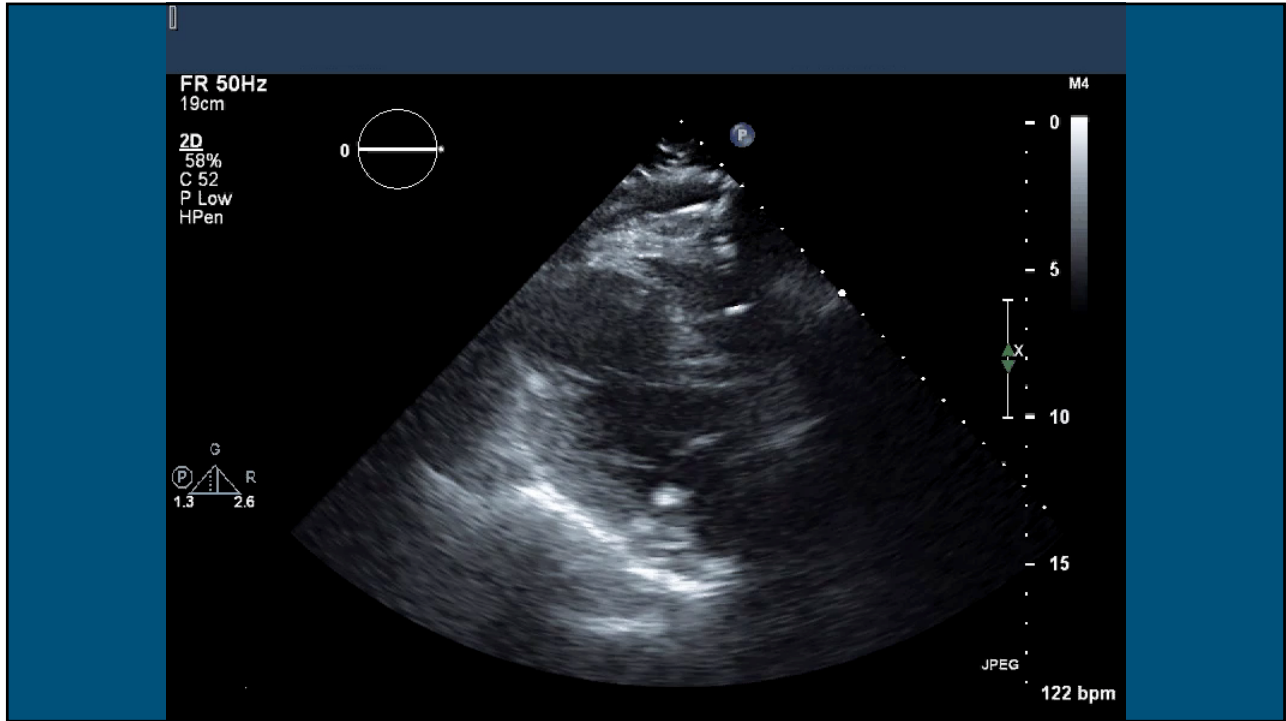


## PRESENTATION

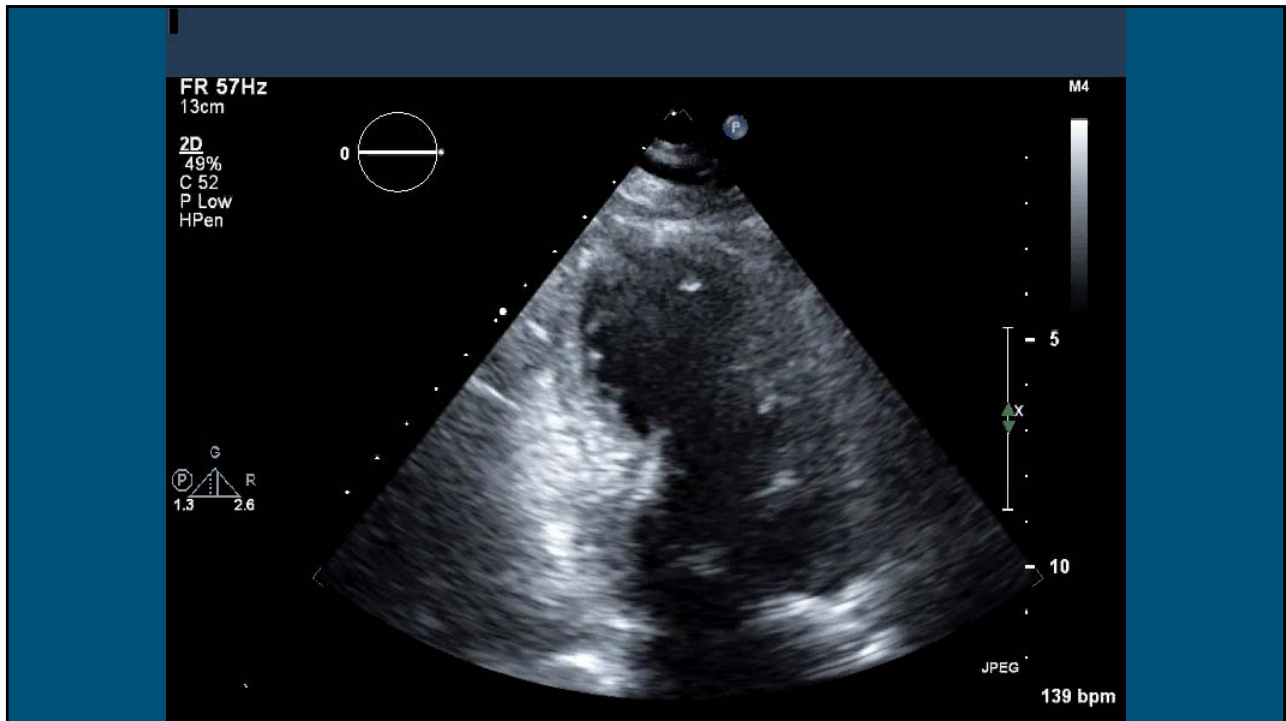
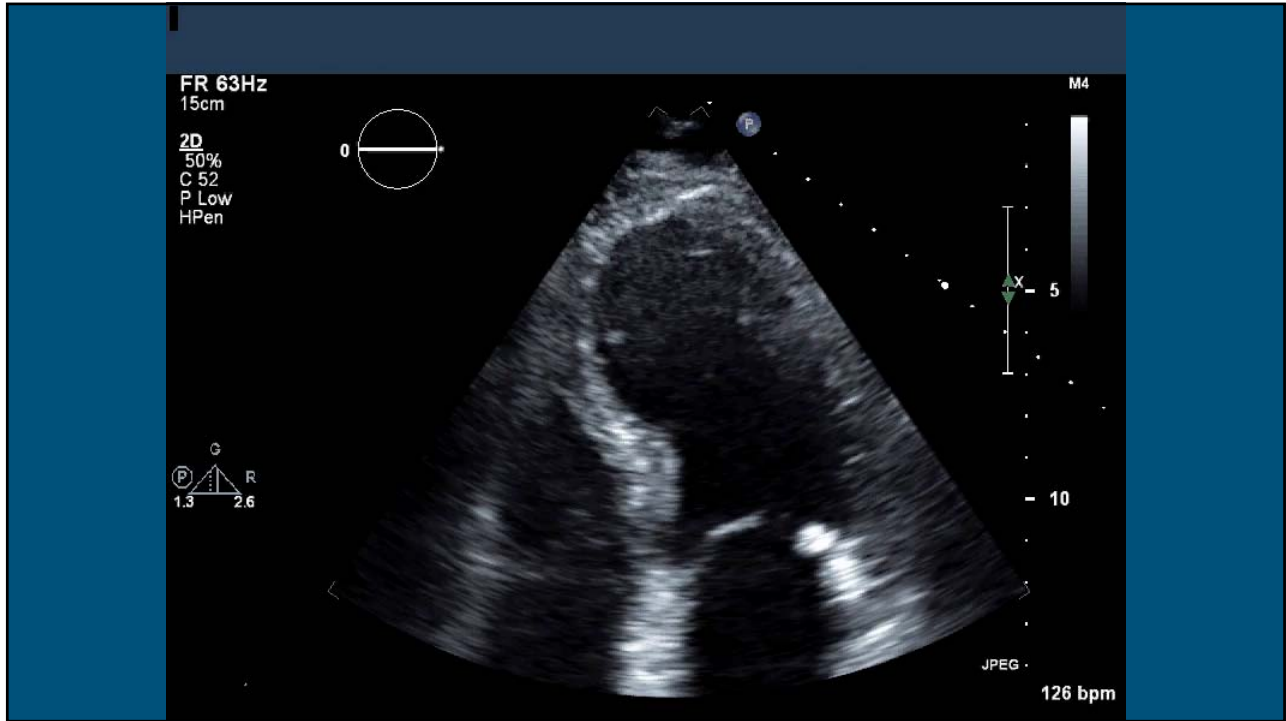
- Attempts at revascularization of the LAD were unsuccessful and the patient was admitted to the cardiac intensive care unit for further monitoring and medical management
- The patient remained asymptomatic and had a repeat EKG on hospital day 3



WHAT ECHOCARDIOGRAPHIC  
ABNORMALITY WOULD YOU  
EXPECT TO FIND BASED ON THE  
PATIENT'S EKG?







## LV THROMBUS

- Epidemiology and Natural History:
  - Occurs in 4%-8% of myocardial infarctions
  - Occurs because of stasis and the procoagulant effects of fibrotic/necrotic myocardium
  - Most thrombi form within the first two weeks following myocardial infarction
  - Highest risk of embolization in the first 3-4 months following myocardial infarction
  - Most common in the anteroapical location following large anterior STEMIs
  - Risk factors: LAD occlusion, EF<30%, long delay between symptom onset and reperfusion

## LV THROMBUS

- Clinical Manifestations:
  - Most are asymptomatic and diagnosed on screening transthoracic echocardiogram following myocardial infarction
  - Systemic embolization

## LV THROMBUS

- **Diagnosis:**
  - Transthoracic echocardiography is the initial test of choice though thrombi can be difficult to visualize because they may have a similar acoustic appearance to normal myocardium and/or the apex may be obscured by near field artifact
  - The sensitivity of transthoracic echocardiography is increased to 64% with the use of contrast
  - Increased mobility and protrusion into the LV cavity on transthoracic echocardiogram have been associated with an increased risk of embolization
  - Gold standard is cardiac MRI

## LV THROMBUS

- **Treatment:**
  - No treatment: 10-15% risk of embolization
  - Medical: anticoagulation with warfarin, usually for 3-4 months following myocardial infarction (86% reduction in the risk of embolization)

## CLINICAL COURSE

- The patient was medically managed with aspirin, ticagrelor, warfarin, atorvastatin, and metoprolol
- On hospital day 4 the patient had an abrupt episode of hypotension with systolic blood pressure in the 70s that resolved with IV fluids
- 6 hours later the patient suffered a PEA arrest. CPR was performed for 35 minutes without return of spontaneous circulation and the patient was pronounced dead

**BASED ON THE PATIENT'S  
PRESENTATION, WHAT IS THE  
MOST LIKELY CAUSE OF DEATH?**

**FINAL PATHOLOGIC DIAGNOSIS**

Massive acute anterolateral myocardial infarction (1-7 days) with left ventricular perforation and early organizing hemopericardium (103 g; approximately 1 week), in the setting of severe coronary artery disease with recent thrombosis of the left anterior descending artery.

The cause of death is judged to be acute myocardial infarction, with left ventricular perforation and hemopericardium.

THANK YOU

Dr. Noreen Kelly  
Dr. Michael Picard  
Dr. Danita Sanborn  
Dr. Rory Weiner  
Dr. David Dudzinski