TEE Essential in Paravalvular Leak Closure and Pseudoaneurysm Repair.

Gerard T Wilkins
Assoc Prof Medicine
Consultant Cardiologist
Dunedin Hospital

Structural Heart Disease: short history

- Rubio-Alvares and Limon 1952.
  - Relief of critical pulmonary stenosis with catheter
- Bill Raskind introduces balloon septostomy 1966
- Peripheral balloon interventions introduced
- Techniques adapted for pulmonary valvuloplasty
- Inoue performs first Mitral valvuloplasty
- Karl Amplatz creates plugs for defect closure
  - Specific devices for ASD,VSD, PDA
  - Devices migrate to other applications
  - Specific PVL devices emerge

- Incidence of PVL immediately after surgical valve replacement (SVR)
  - post AVR ranges 6 to 17.6%
  - post MVR ranges 22.6 to 32%
  - 90% trivial to mild –clinically insignificant
  - 2% moderate – severe
  - Mitral more common than aortic

Davila-Roman et al. J Am Coll Cardiol 2004;44:1467-72
Hammermeister K et al. J Am Coll Cardiol 2000;36:1152-8
Ionescu A et al. Heart 2003;89:1316-21

- Surgical closure vs percutaneous closure

- Surgery has been mainstay for symptomatic leaks
- Mortality high, 10% in recent large series
- Paradoxically redo surgery has higher rate of PVL's
  - First re-do PVL 13%, Second re-do PVL 35%

Akins et al. J Heart Valve Dis 2005 Nov 14:792-799

- Surgical closure vs percutaneous closure

- Percutaneous success rates high in recent large series with low mortality:
  - Two large USA series - success 77% to 86.5%
  - UK & Ireland n=259, device success 91%,
    75% mild-or less residual regurgitation

Sorajja et al. Circ Cardiovasc Intervention 2011;4(4):314-321
Ruiz C et al. J Am Coll Cardiol 2011;58(21):2210-17
Calvert PA et al. Circulation 2016

- Surgical closure vs percutaneous closure

- New consensus guidelines
- Better equipment and experience favours percutaneous approaches

Nishamura, Otto, Bonow et al. 2014 AHA/ACC Guideline for the management of patients with valvular heart disease: J Am Coll Cardiol 2014;63:e57-185

Paravalvular leak

- More common with advancing age
  - Extent of calcification
  - Tissue friability
- More common after surgery for bacterial endocarditis
  - Extensive abscess formation
  - Redo prosthetic valves
  - Emergent surgery for haemodynamic failure

Usual reasons for closure PVL and Pseudoaneurysm

Haemodynamic burden – big holes
- Heart failure
- Progressive chamber enlargement
- Deteriorating EF

Haemolysis – small complex jet lesions
- Need for transfusion
- Persistent low grade anaemia
- Low haptoglobins, high reticulocyte count

Pseudoaneurysm – risk of rupture

Detection

- Clinically suspected
- Transthoracic ECHO
- Transoesophageal ECHO
- Gated contrast CT reconstructions
- Contrast angiography
- MRI

TTE image: best for initial detection,
often imprecise for location and shape

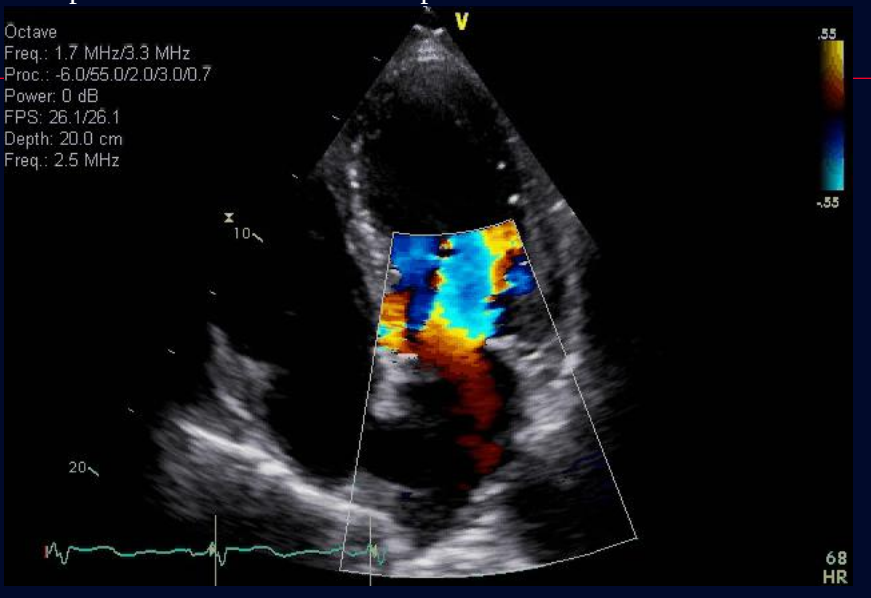

TTE: Jet frequently directed across face of valve
Anatomic size, shape and location obscured

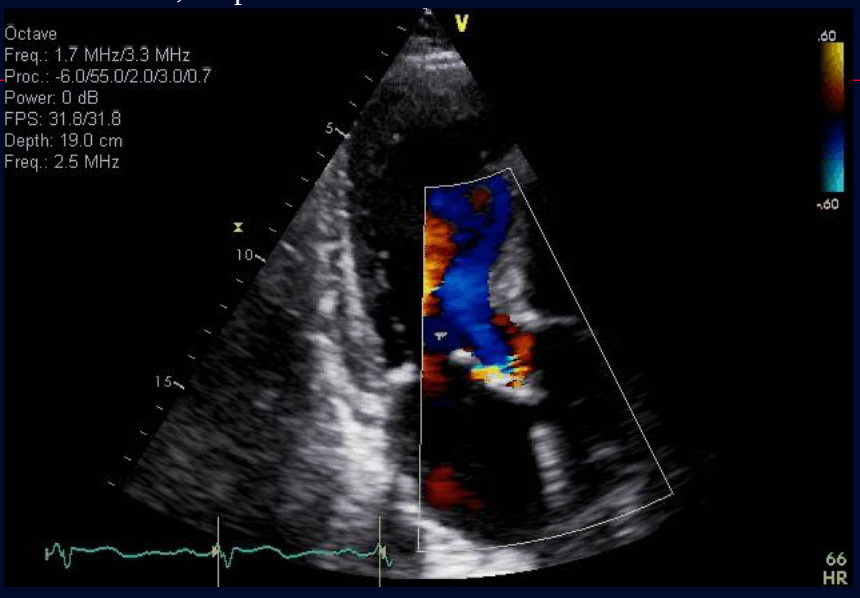

TEE: biplane image, Aortic bioprosthesis
single, large, crescentic paravalvular leak, non-coronary sinus

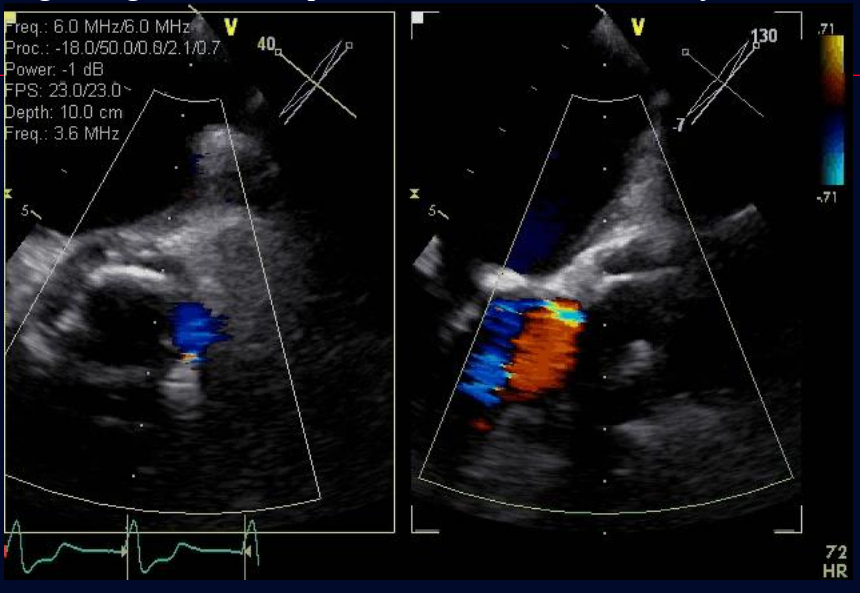

Planning usually multi-modality
CT reconstructions directed by knowledge from TEE

9x4mm
Widest point in inlet as above

Constructed of woven nitinol with or without dacron inserts

Figure 4. Devices used for closure of periprosthetic defects. (A) Amplatzer Septal Occluder; **(B)** Amplatzer Cribriform Occluder; **(C)** Amplatzer Vascular Plug II; **(D)** Muscular VSD Occluder; **(E)** Amplatzer Duct Occluder; **(F)** Amplatzer Vascular Plug III; **(G)** Occlutech Paravalvular Leak Closure Device.

Closing Complex Holes: 1 Process

- Planning images TTE & TEE
  - Identify hole, often several, shape (buttoniere)
  - Position in relation to structures (valve ring)
  - Relationships eg coronary artery
  - Sizing
  - Access
  - Exclude other pathologies (endocarditis)

Device shape

Often buttoniere / linear defects
Complex tunnel shapes from inlet - outlet

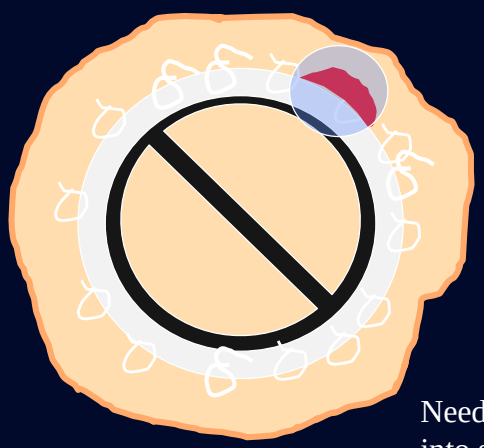

Circular shape needs to be large to cover, Encroaches on valve

Better fit with oval or complex rectangle
New "game changing" devices

Need to crush device into small catheter and regain shape on release

Closing Complex Holes: 2 Review

- Review TEE images with other planning images
  - CT reconstructions
  - Catheter based imaging
  - MRI

Closing Complex Holes: 3 Plan Access

- Route
- Device + sizing
- Deployment position
- Closure of access point
- Bail-out options

Potential approaches



Retro-aortic Transseptal Transapical

Closing Complex Holes: 4 - Heart Team Meeting

- Structural interventionalist, TEE, Anaethesia, CT, Cardiac Surgeon, Clinical
  - Risk assessment
    - Surgical
    - Anaesthetic
    - Mobilization/recovery
  - Alternatives
  - Bailout planning
  - Documentation

Closing Complex Holes: 5 Consent

- Informed consent
  - Patient and family/support
  - Realistic
  - Risk
  - Novel/unique/ uncommon procedures
  - Nothing vs percutaneous vs surgery

Complex case

- 83 year old man
  - Age 55 chronic atrial fibrillation ➔ dilated cardiomyopathy, CHF. Recovered EBMT.
- New symptoms LV normal,
  - (TOE) demonstrated severe mitral regurgitation
  - bileaflet myoxomatous disease with severe posterior leaflet flail involving P2+P3
  - PA 70 systolic.
- Magna Ease 33mm tissue prosthesis
  - initially uncomplicated post–operative course.
- Around day 6 post-operatively developed breathless
  - loud pansystolic murmur was noted at all examinations (not noted up until that time) and large bilateral pleural effusions developed.
- TOE - severe para-prosthetic leak placed inferiorly and medially

- Options
  - Re-operation
  - Medical management
  - Percutaneous closure
    - Difficult place to get to via transseptal
    - Best via transapical approach
      - Thorough planning – access, delivery, closure, exiting LV

Potential approaches



Retro-aortic Transseptal Transapical

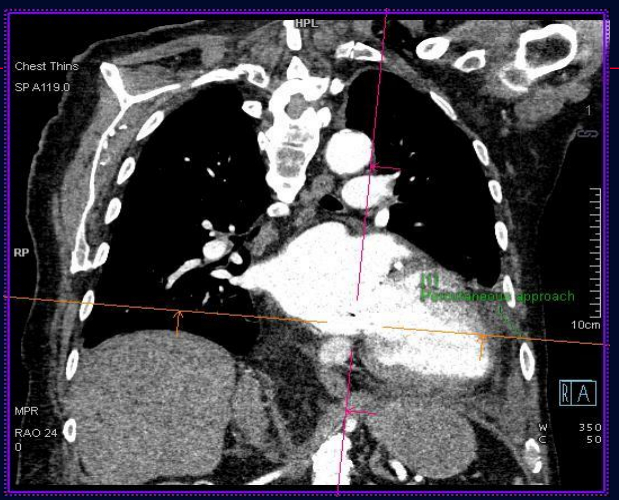

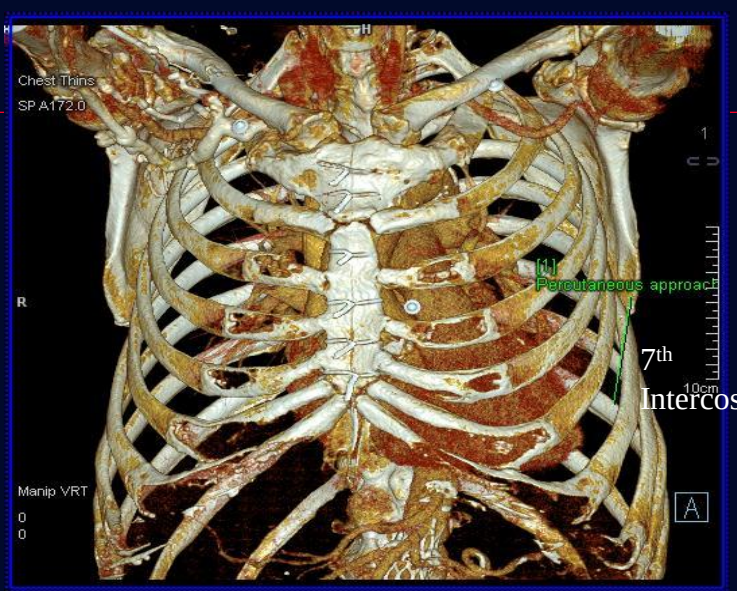

7th
Intercostal space

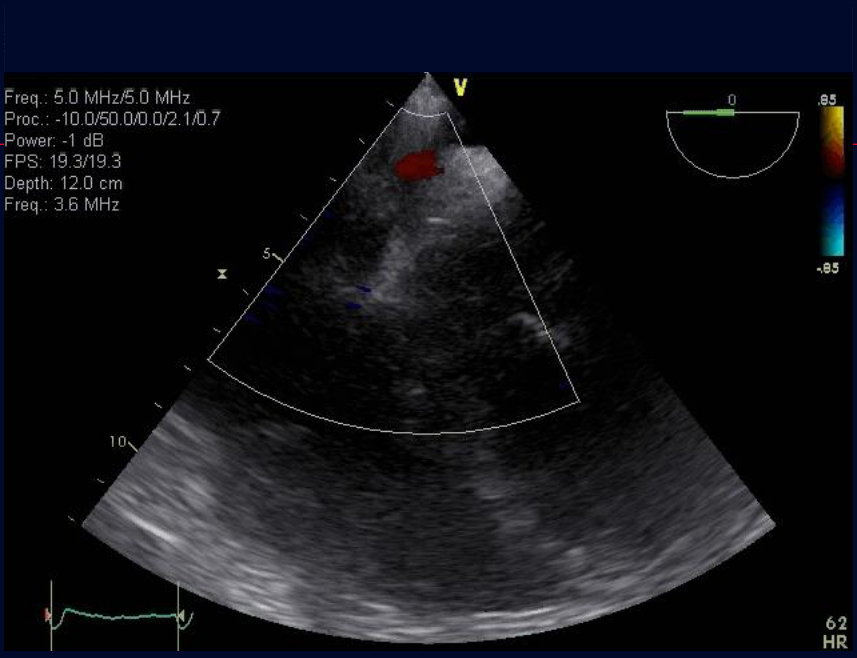
Freq.: 5.0 MHz/5.0 MHz
Proc.: -10.0/50.0/0.0/2.1/0.7
Power: -1 dB
FPS: 19.3/19.3
Depth: 12.0 cm
Freq.: 3.6 MHz
V
0
.85
-.85
5
10
62
HR

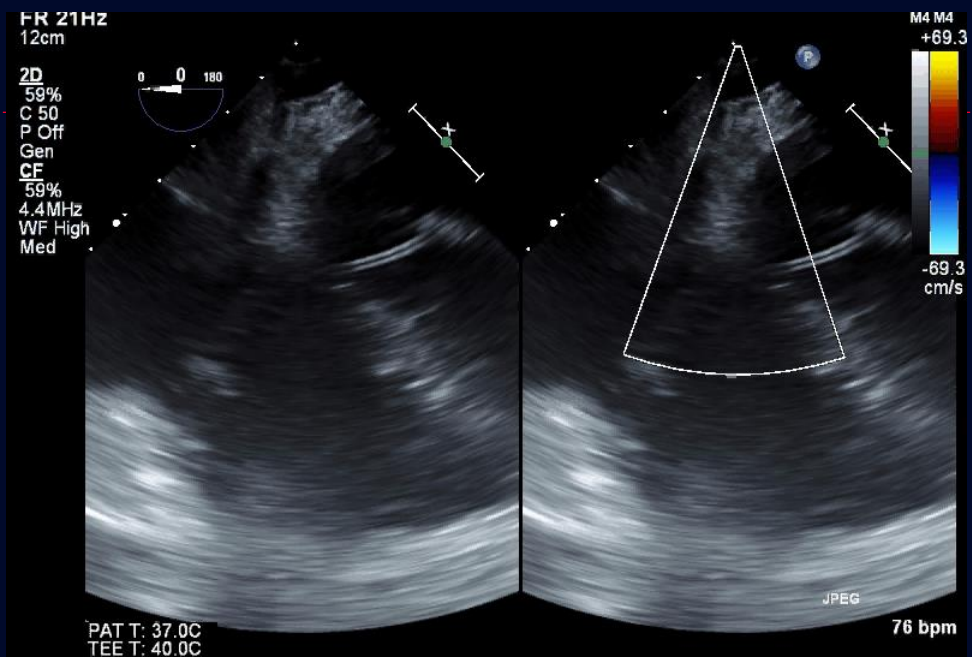
FR 21Hz
12cm
2D
59%
C 50
P Off
Gen
CF
59%
4.4MHz
WF High
Med
0
0
180
M4 M4
+69.3
-69.3
cm/s
P
JPEG
PAT T: 37.0C
TEE T: 40.0C
76 bpm

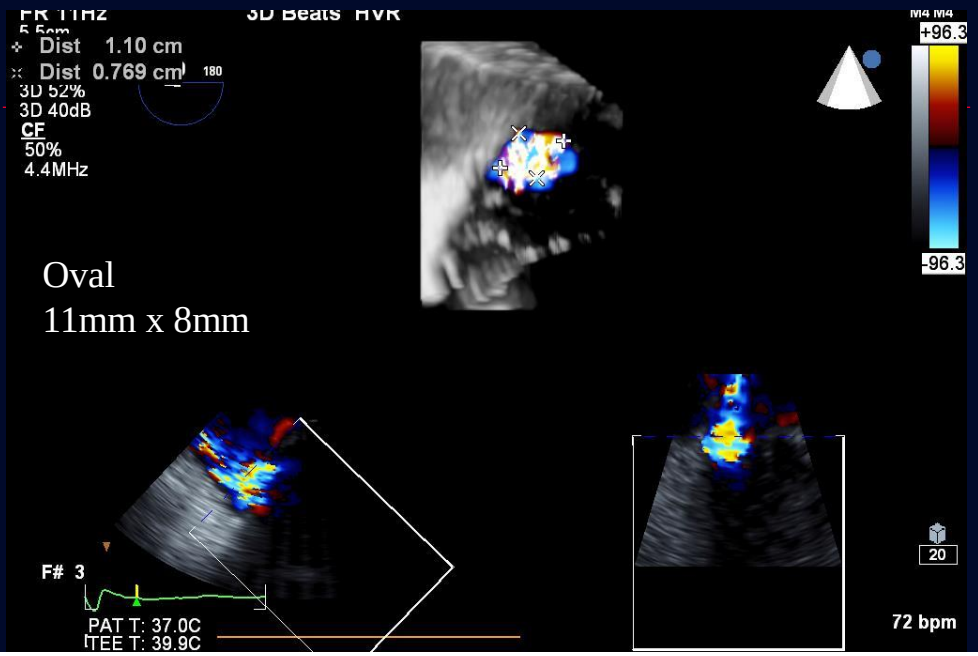

Reorder Number	Long Axis Diameter (mm)	Short Axis Diameter (mm)	Unconstrained Device Length (mm)	Min. Internal Diameter Required (mm [inch])	Min. Sheath Size Required (F)[2]	Min. Guide Catheter Size Required (F)[3]	Max. Delivery System Length (cm)
9-AVP3-042	4	2	6.5	1.65 [0.065]	4	6	120
9-AVP3-063	6	3	6.5	1.65 [0.065]	4	6	120
9-AVP3-084	8	4	6.5	1.83 [0.072]	5	7	120
9-AVP3-103	10	3	6.5	1.83 [0.072]	5	7	120
9-AVP3-105	10	5	6.5	1.83 [0.072]	5	7	120
9-AVP3-123	12	3	6.5	2.49 [0.098]	7	9	120
9-AVP3-125	12	5	6.5	2.49 [0.098]	7	9	120
9-AVP3-143	14	3	6.5	2.49 [0.098]	7	9	120
9-AVP3-145	14	5	6.5	2.49 [0.098]	7	9	120



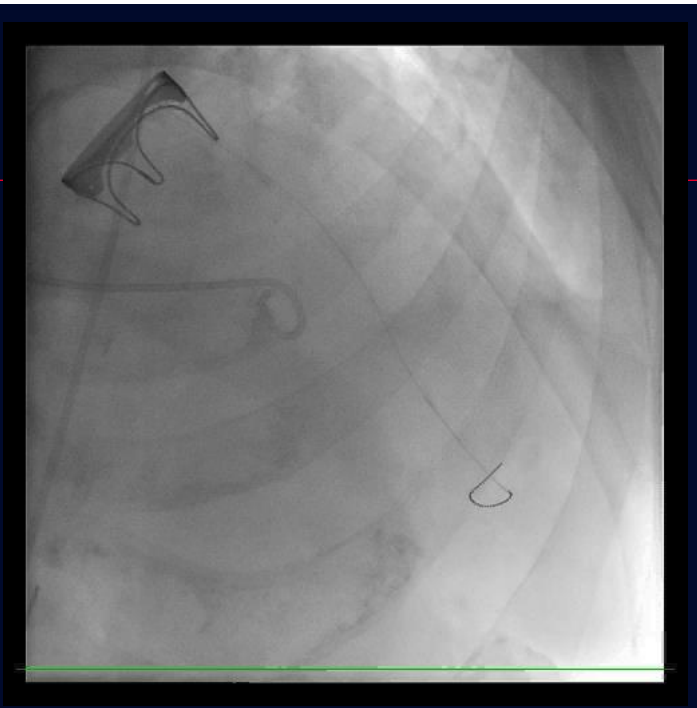

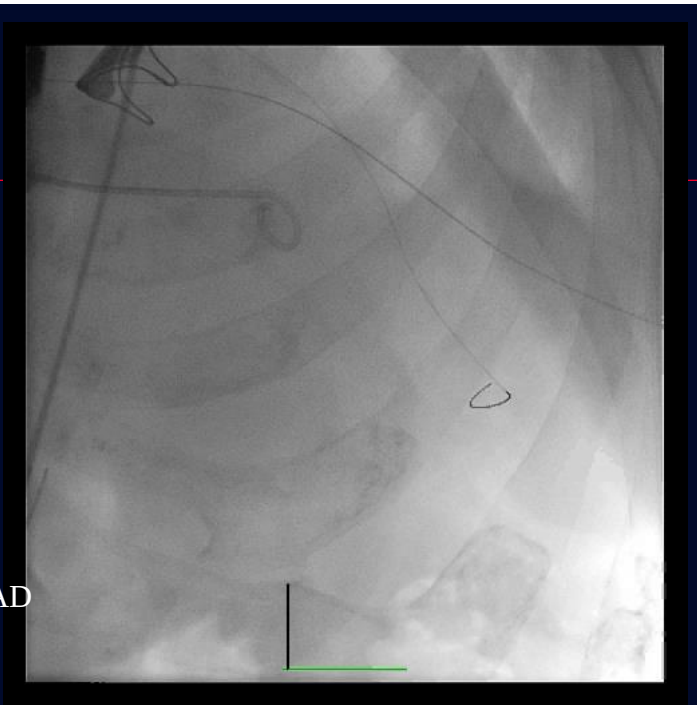

21G
Direct
LV puncture
LV free wall
Avoiding LAD
7F sheath

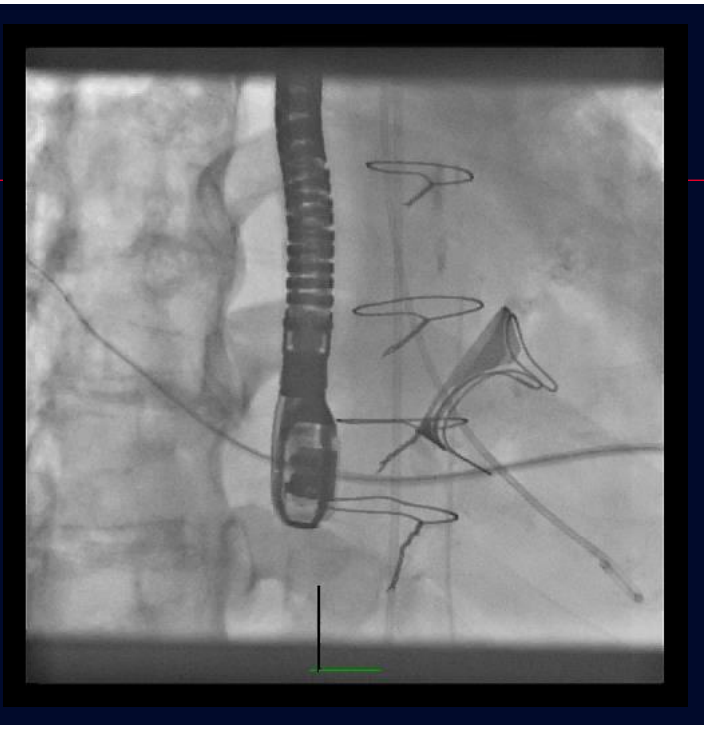


FR 8Hz
5.8cm
3D Beats 1
M4
3D
3D 52%
3D 40dB
0
0
180
JPEG
PAT T: 37.0C
TEE T: 39.4C
61 bpm

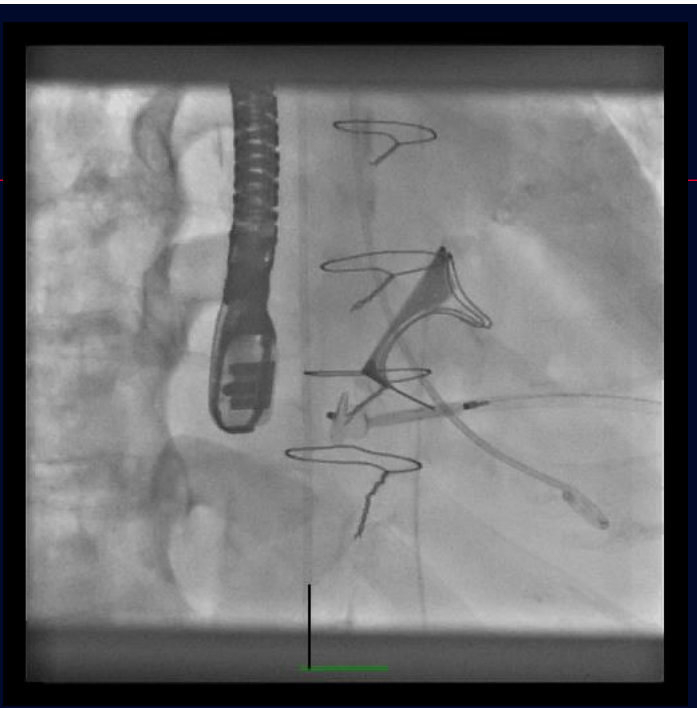

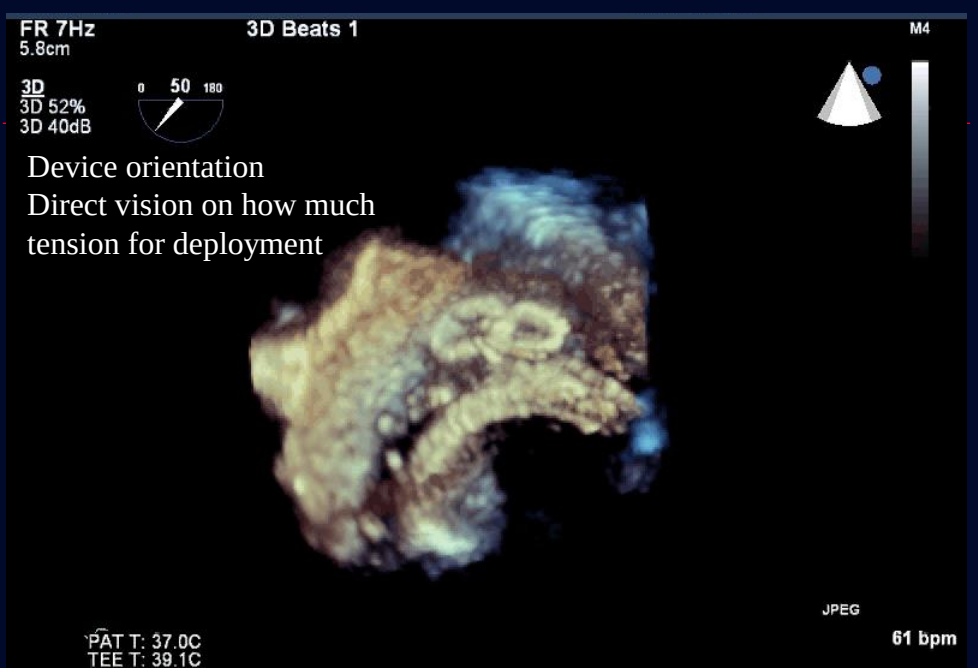

Device orientation
Direct vision on how much tension for deployment

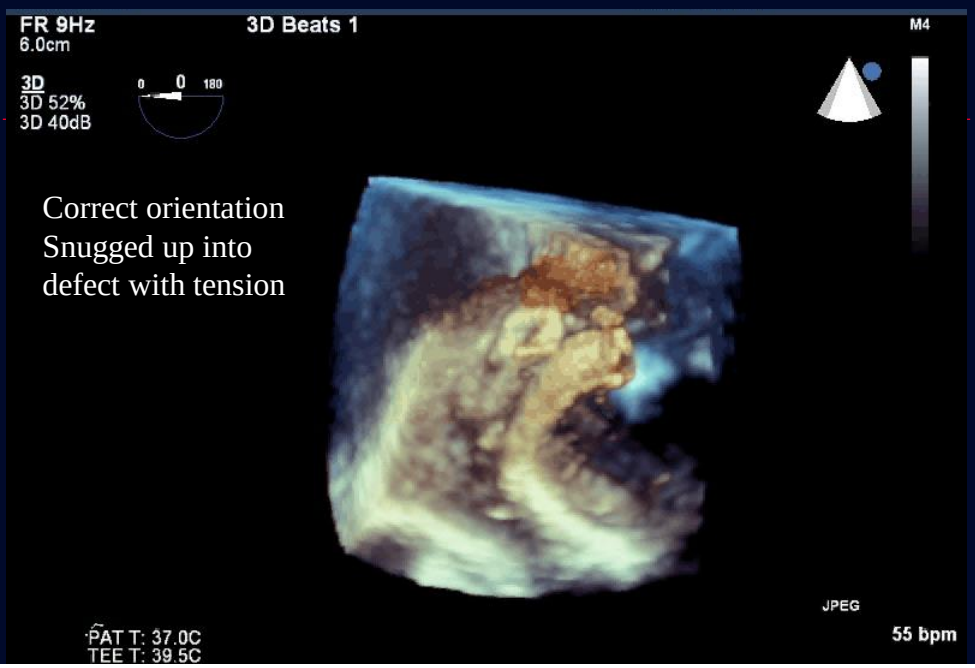

Correct orientation
Snugged up into
defect with tension

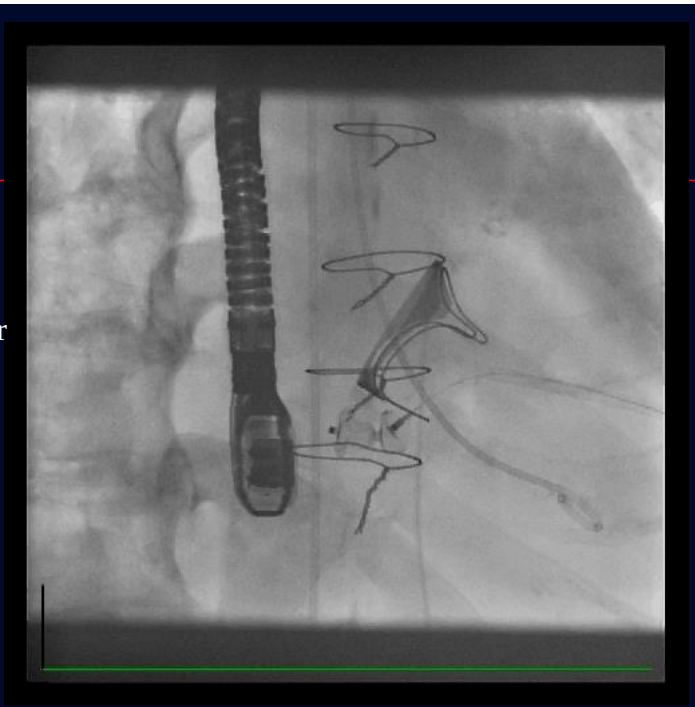

Amplatzer
VP3

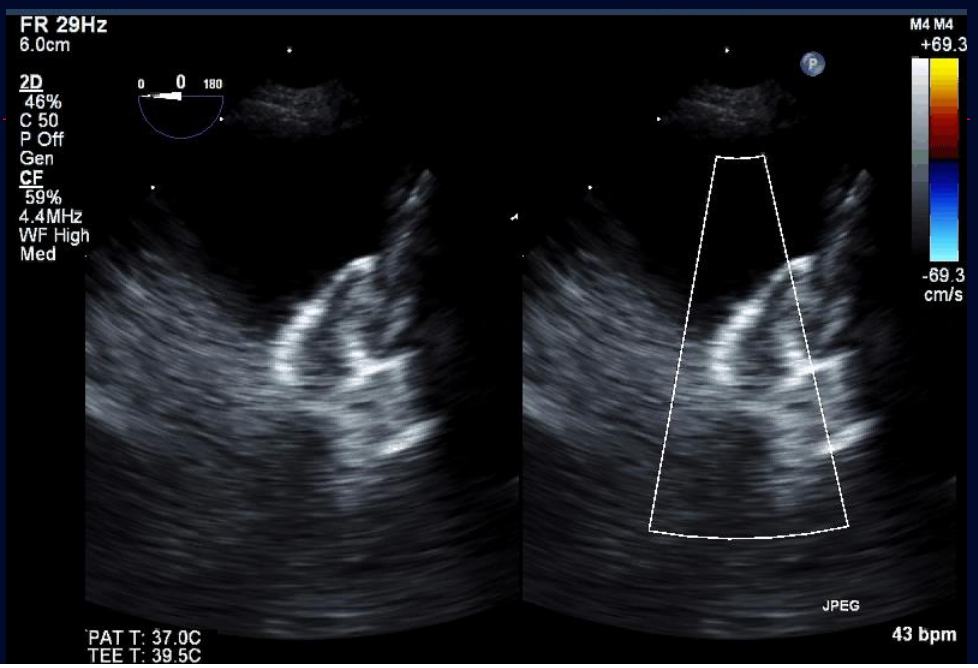
FR 29Hz
6.0cm
2D
46%
C 50
P Off
Gen
CF
59%
4.4MHz
WF High
Med
0
0
180
M4 M4
+69.3
-69.3
cm/s
JPEG
43 bpm
PAT T: 37.0C
TEE T: 39.5C

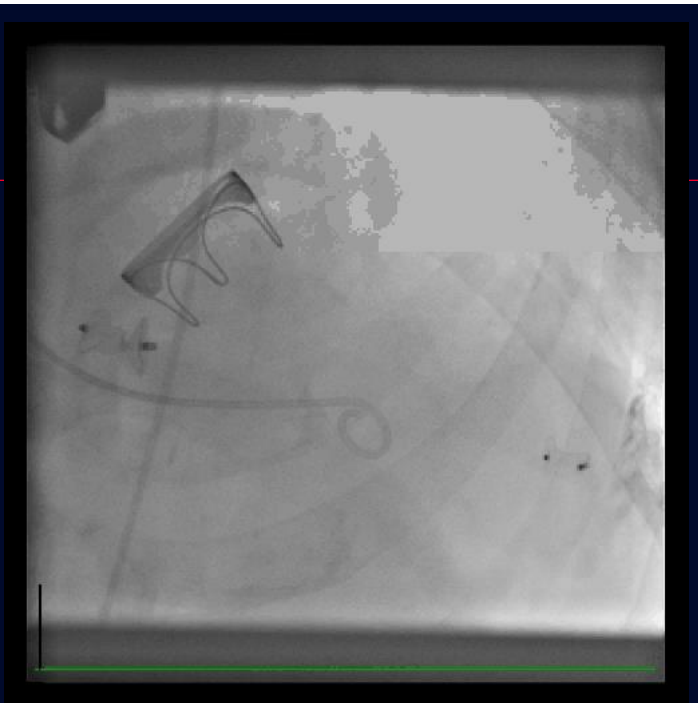

Closing Complex Holes: TEE Operator Run Sheet

a. During set up
   a. Organize key views,
   b. Repeat sizing
b. Assist with access
   a. Eg transseptal, transapical
c. Finding hole & confirming passage
d. Assist in device deployment
   a. Distal deployment (tension – flow-size)
   b. Proximal, orientation
   c. Adjacent valve function or structures
   d. stability
e. Guide device release - stability
f. Close access – transseptal/transapical/pericardium

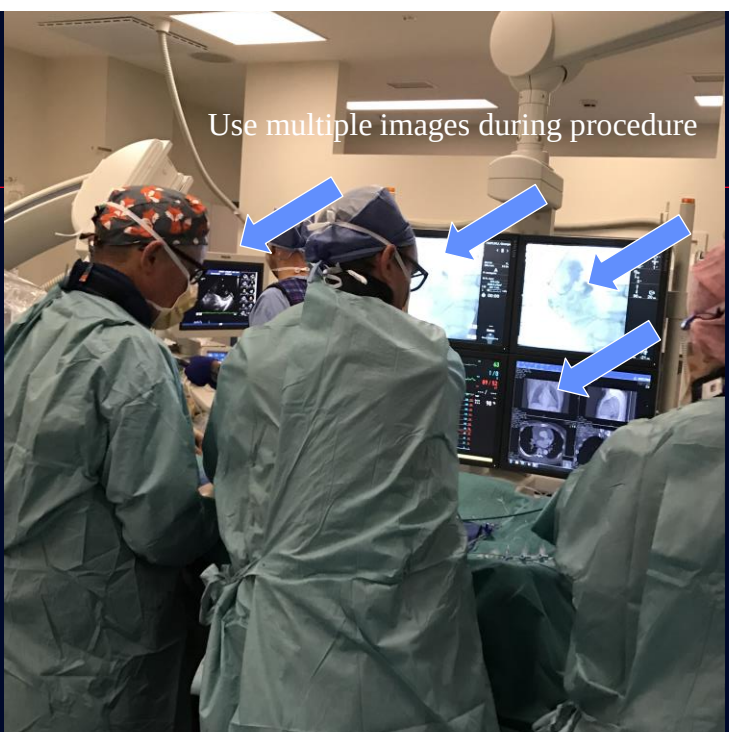

- Encroachment on valve mechanism
  - Mechanical
    - more likely affected
  - Bioprosthesis

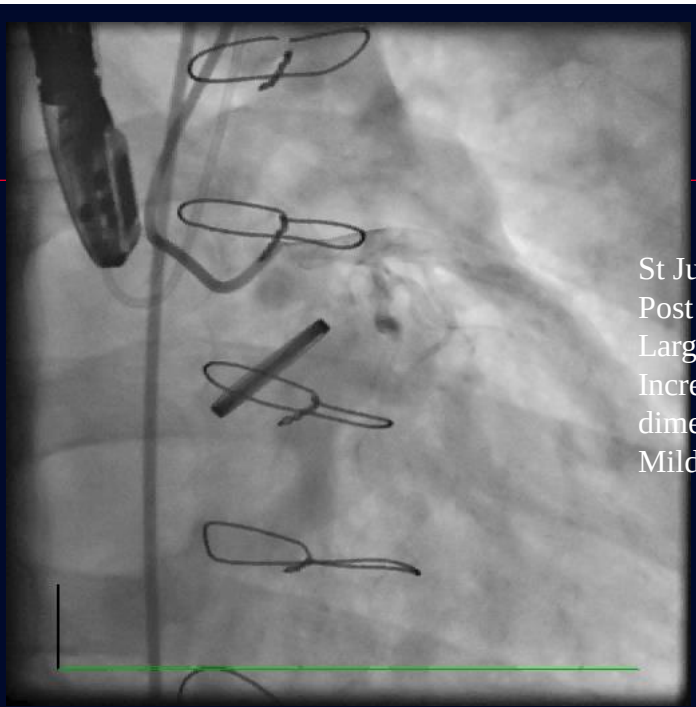

St Jude AVR
Post endocarditis
Large leak
Increasing LV dimensions with
Mild SOBOE

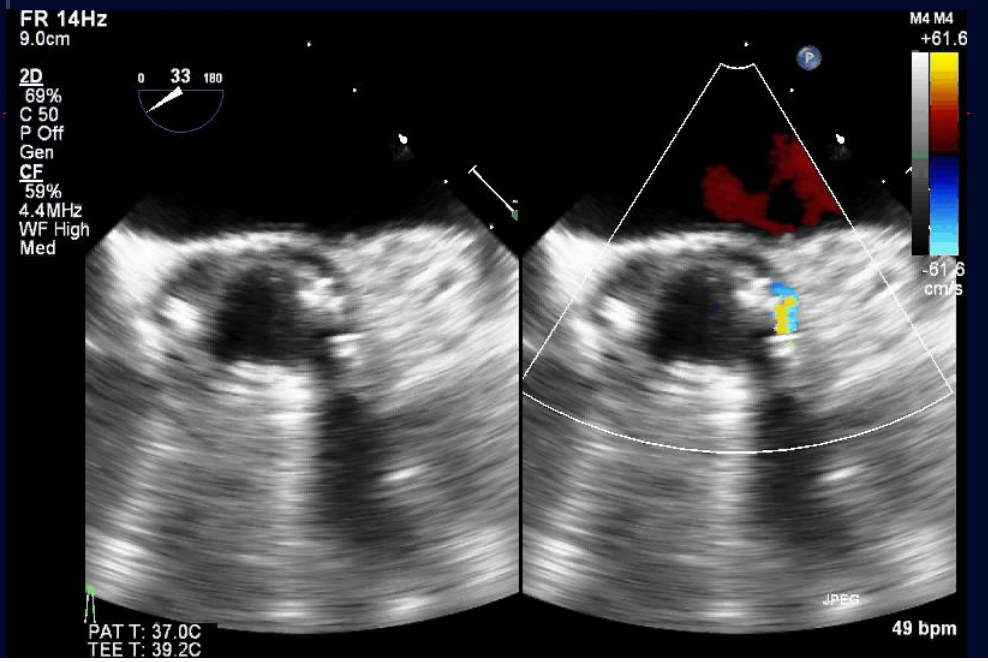
FR 14Hz
9.0cm
2D
69%
C 50
P Off
Gen
CF
59%
4.4MHz
WF High
Med
0
33
180
M4 M4
+61.6
-61.6
cm/s
JPEG
PAT T: 37.0C
TEE T: 39.2C
49 bpm

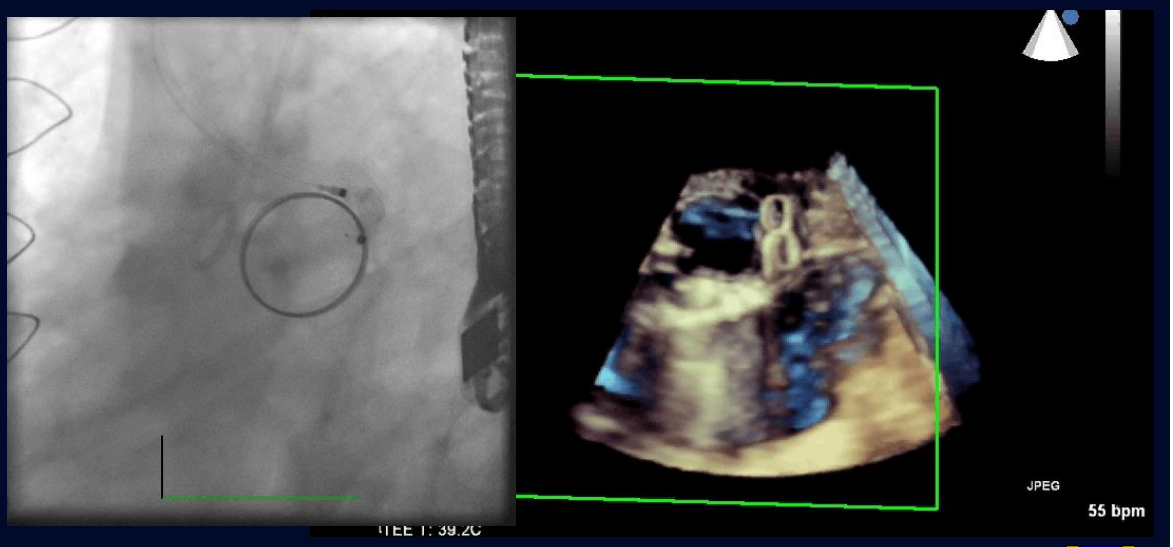

Fluoro vs 3D reconstruction for device around St Jude AVR

Multiple defects

- Checking closure
  - Device porous
  - Closure imperfect
  - Other undiagnosed defects
  - Constantly checking for further PVL's

Post redo for Endocarditis. Severe LV impairment Inoperable

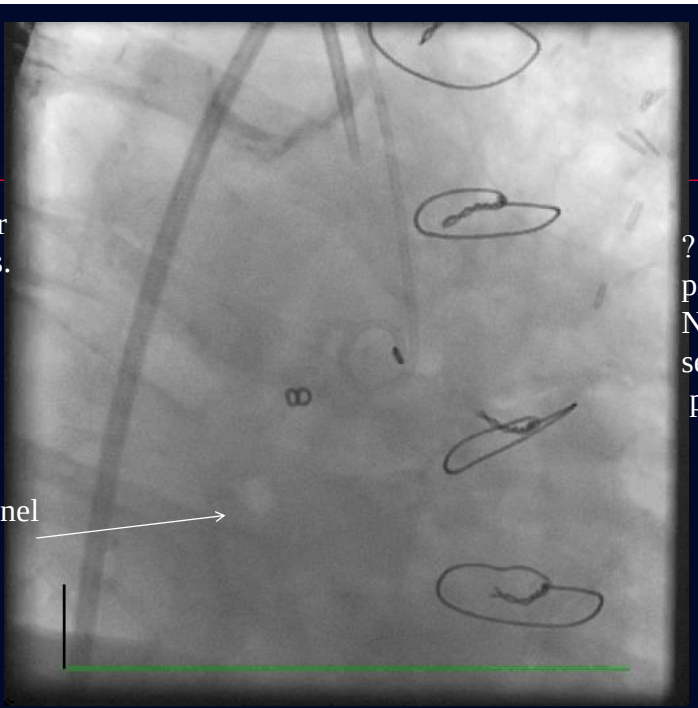

? Other PVL's present. Not initially seen on planning TEE

Complex tunnel

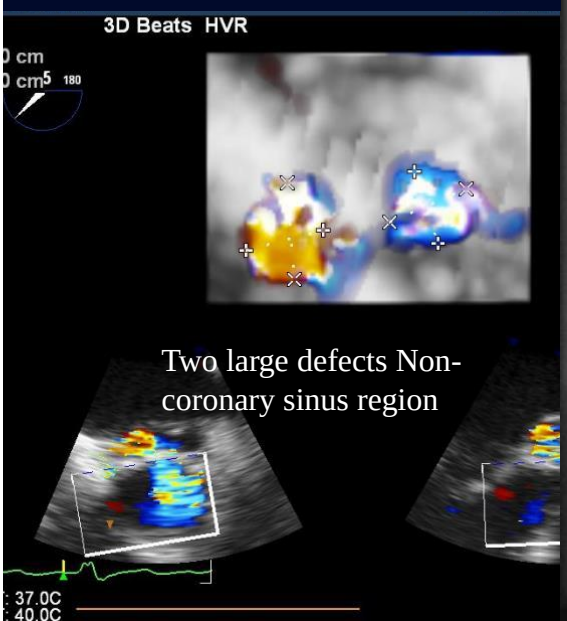

Two large defects Non-coronary sinus region

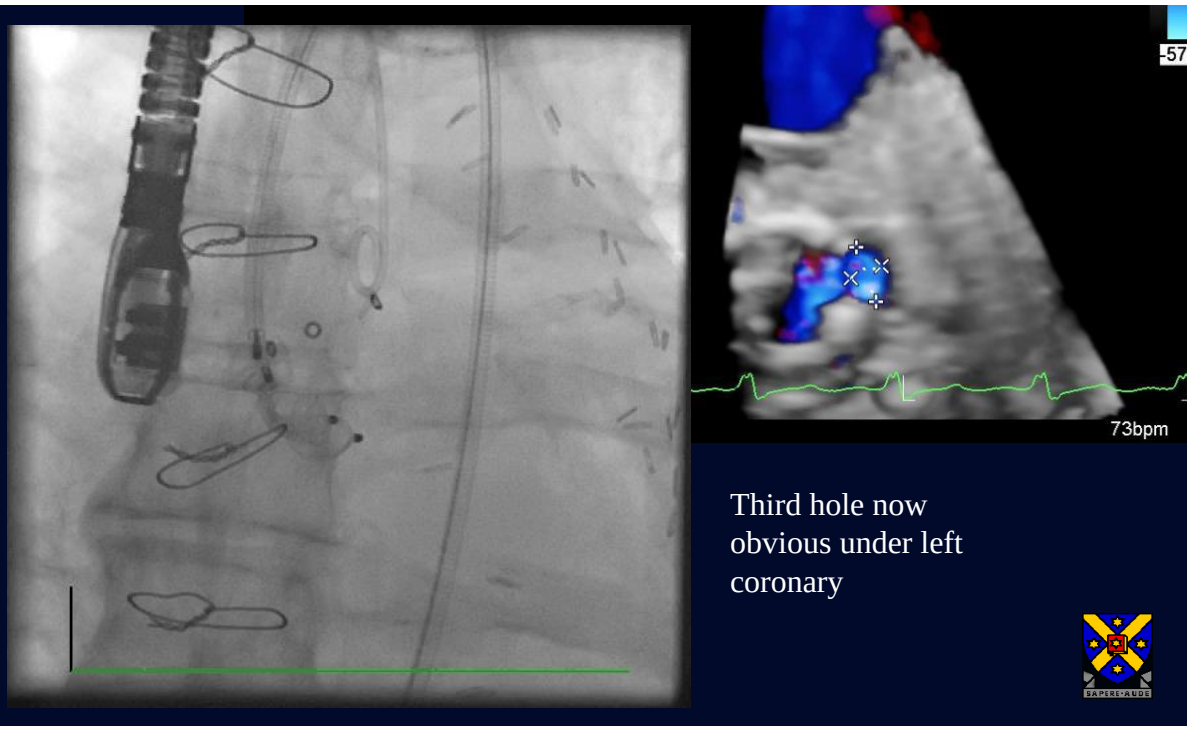

Third hole now obvious under left coronary

- Closing the entry point
  - Transapical PDA plug and Floseal glue

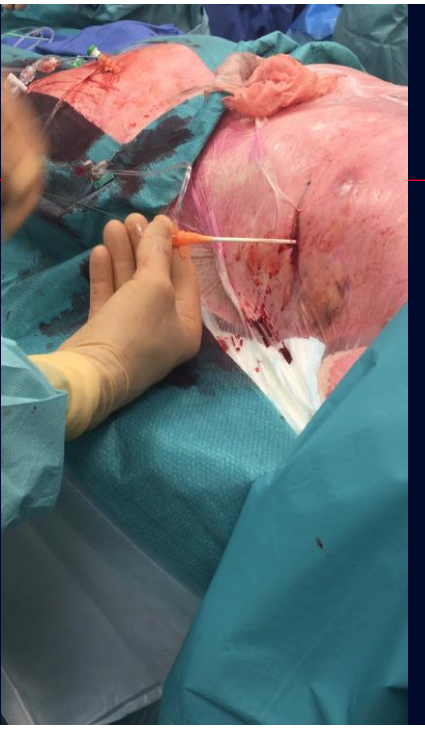

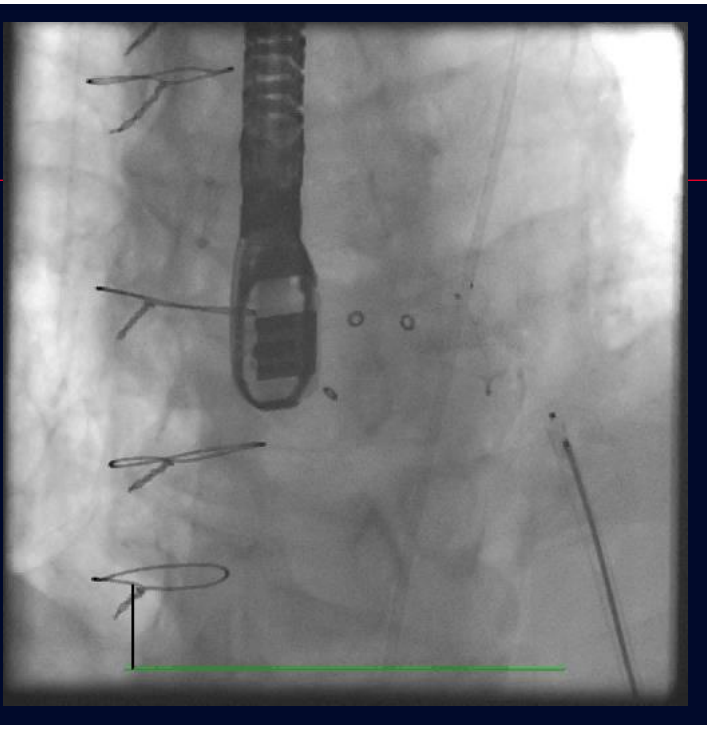

Closing apical entry point

Partial exposure of PDA device – confirming mid ventricle

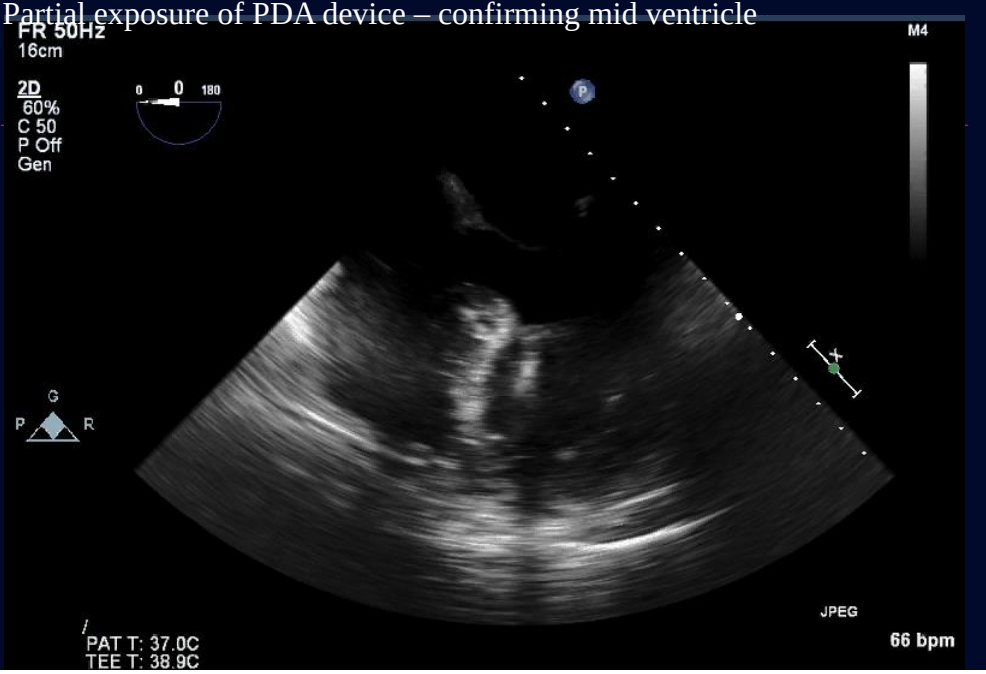

PDA pulled down into apical endocardium

Not possible to visualize this relationship with fluroscopey

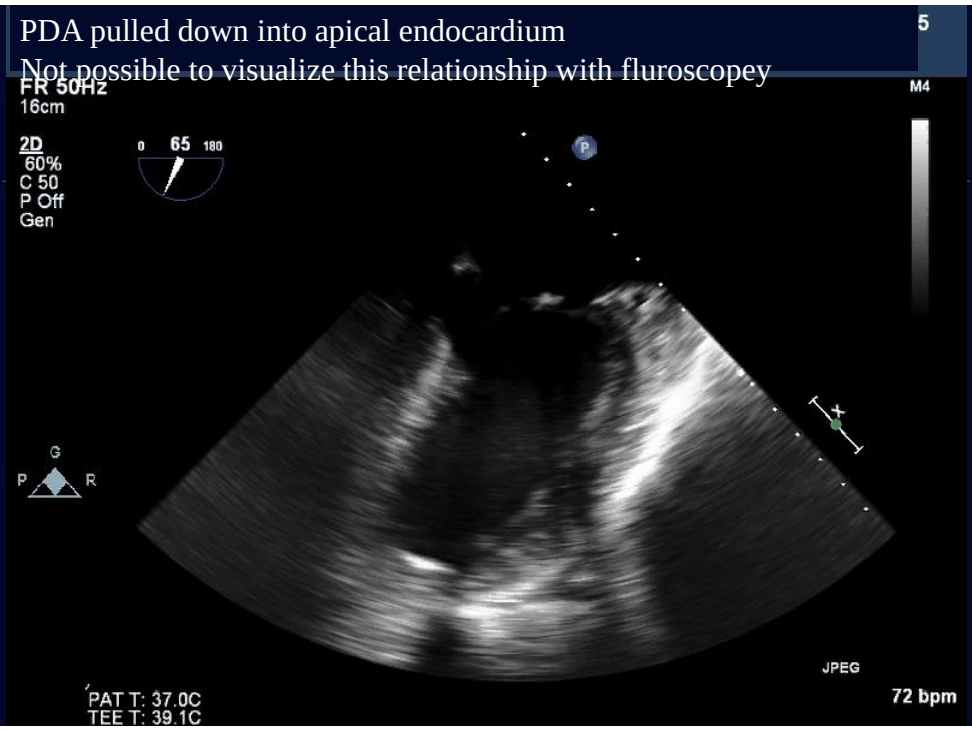

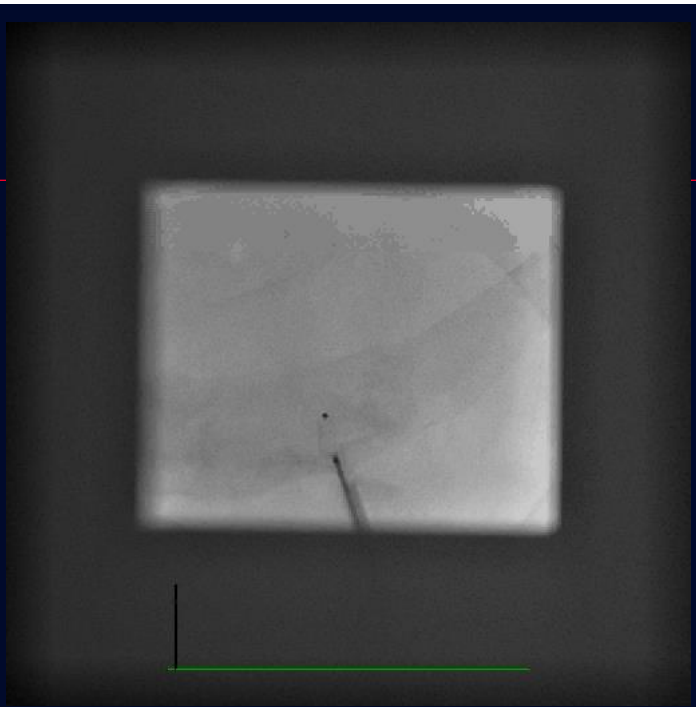

TEE Operator Key Messages

- Mindset change
  - Not creating diagnostic images, participating in an intervention
- Time out – Theatre Universal Protocol
- Think ahead of what is needed
- Communication + Participation
- Think like a structural interventionalist
  - Find
  - Cross
  - Deploy
  - Avoid
  - Stable
- Understand other imaging modalities and devices