Pregnancy, Heart Disease and Imaging

Sangeeta Shah, MD, FASE, FACC
Associate Professor, Ochsner Clinical School of Medicine
Advanced CV Imaging and Adult Congenital Heart Disease
New Orleans, LA

Hemodynamics

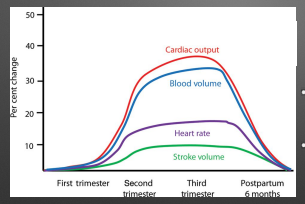

- Decreased systemic vascular resistance
- Physiology anemia

Liu. Cardiovascular Research (2014) 101, 545-53

ARS Question Chamber changes?

Echocardiography Changes

INCREASED
Ventricular Dimensions
LV wall thickness and mass
Myocardial strain
LA volume
Stroke volume (VTI)
Mitral inflow
Aortic root diameter

UNCHANGED
Ventricular EF
Pulmonary artery pressure

Liu. Curr Cardiol Rep (2016) 18:92

Heart Disease

Major cause of maternal death during pregnancy

Why?

- Increasing age of first pregnancy
- Increasing prevalence of CV risk factors
- Increase in adult congenital population

European Heart Journal (2011) 32, 3147–3197
doi:10.1093/eurheartj/ehr218

ESC GUIDELINES

ESC Guidelines on the management of cardiovascular diseases during pregnancy

WHO RISK CLASS	RISK OF PREGNANCY
I	No maternal **mortality** and no/mild increase **morbidity**
II	Small increase maternal **mortality** and moderate increase in **morbidity**
III	Significant increase in material **mortality** or severe **morbidity**
IV	Extremely high risk of maternal **mortality** or severe **morbidity**

Maternal Risk: no mortality and minimal morbidity

WHO I
Uncomplicated, small or mild PS, PDA or MVP
Repaired ASD, VSD, anomalous pulmonary venous drainage
Atrial or ventricular ectopy

Maternal Risk:
small mortality and significant morbidity

WHO II
unoperated ASD or VSD
Repaired Tetralogy of Fallot
Most arrhythmia

WHO II-III
Mild LV dysfunction >45%
Hypertrophic CM
Valvular disease
Marfan with aorta <40mm
Bicuspid AV with aorta <45mm
Repaired coarctation

Maternal Risk:
significant mortality and severe mortality

WHO III
Mechanical valve
Marfan with Aorta 40-45mm
Bicuspid with Aorta 45-50mm
Systemic right ventricle
Fontan Circulation
Cyanotic Heart Disease (unrepaired)
Other Complex Congenital heart disease

Maternal Risk:
extremely high mortality and severe morbidity

WHO IV
Pulmonary hypertension
Severe systemic ventricular dysfunction (LVEF <30%, NYHA III-IV)
Previous PPCM with any residual LV dysfunction
Severe MS or severe symptomatic AS
Native severe coarctation
Marfan with aorta >45mm
Bicuspid with Aorta of >50

Balance

Maternal predictors of Neonatal Events

MORTALITY 1-4%; MORBIDITY 20-28%
Baseline NYHA Class >II or cyanosis
Maternal left heart obstruction
Smoking during pregnancy
Multiple gestation
Use of oral anticoagulation during pregnancy
Mechanical valve prosthesis

THE MARFAN FOUNDATION

Case

- 35 y.o. female with history of Marfan's syndrome presents for her annual physical exam and discussion for pregnancy
- Physical Exam
  - BP 130/80 HR of 80 bpm; height 66 in; weight 105lbs; BSA 1.56 m2
  - HEENT: arched palate
  - Chest: Mild pectus excavatum with normal BS
  - CV: normal S1 S2 RRR

Guidelines and Standards

Multimodality Imaging of Diseases of the Thoracic Aorta in Adults: From the American Society of Echocardiography and the European Association of Cardiovascular Imaging

Endorsed by the Society of Cardiovascular Computed Tomography and Society for Cardiovascular Magnetic Resonance

Steven A. Goldstein, MD, Co-Chair, Arturo Evangelista, MD, FESC, Co-Chair, Sahrey Abbara, MD, Andrew Arai, MD, Federico M. Asch, MD, FASE, Luigi P. Badano, MD, PhD, FESC, Michael A. Bolen, MD, Heidi M. Connolly, MD, Hug Cuéllar-Calabria, MD, Martin Czerny, MD, Richard B. Devereux, MD, Raimund A. Erbel, MD, FASE, FESC, Rossella Fattori, MD, Eric M. Isselbacher, MD, Joseph M. Lindsay, MD, Mani McCulloch, MBA, BDCS, FASE, Hector I. Michelena, MD, FASE, Christoph A. Nienaber, MD, FESC, Jae K. Oh, MD, FASE, Mauro Pepi, MD, FESC, Alan J. Taylor, MD, Jonathan W. Weinsaft, MD, Jose Luis Zamorano, MD, FESC, FASE, Contributing Editors: Harry Dietz, MD, Ken Eagle, MD, John Eichinger, MD, Guillaume Jondeau, MD, PhD, FESC, Hervé Rousseau, MD, PhD, and Marc Schepens, MD, *Washington, District of Columbia; Barcelona and Madrid, Spain; Dallas and Houston, Texas; Bethesda and Baltimore, Maryland; Padua, Pesaro, and Milan, Italy; Cleveland, Ohio; Rochester, Minnesota; Zurich, Switzerland; New York, New York; Essen and Rostock, Germany; Boston, Massachusetts; Ann Arbor, Michigan; New Haven, Connecticut; Paris and Toulouse, France; and Bruges, Belgium*

(J Am Soc Echocardiogr 2015;28:119–82.)

Diagnostic Testing

- Echocardiography
- Cardiac MRI
- Cardiac CT

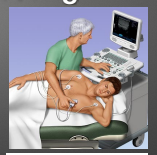

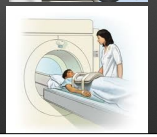

Normal Aortic Root

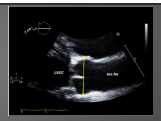

Man BSA of 2.0

Women BSA of 1.7

Table 1 Normal aortic root diameter by age for men with BSA of 2.0 m^2

	Age (y)					
	15–29	30–39	40–49	50–59	60–69	≥70
Mean normal (cm)	3.3	3.4	3.5	3.6	3.7	3.8
Upper limit of normal (cm) (95% CI)	3.7	3.8	3.9	4.0	4.1	4.2

Add 0.5 mm per 0.1 m^2 BSA above 2.0 m^2 or subtract 0.5 mm per 0.1 m^2 BSA below 2.0 m^2.[7,8]
CI, Confidence interval.

Table 2 Normal aortic root diameter by age for women with BSA of 1.7 m^2

	Age (y)					
	15–29	30–39	40–49	50–59	60–69	≥70
Mean normal (cm)	2.9	3.0	3.2	3.2	3.3	3.4
Upper limit of normal (cm)	3.3	3.4	3.6	3.6	3.7	3.9

Add 0.5 mm per 0.1 m^2 BSA above 1.7 m^2 or subtract 0.5 mm per 0.1 m^2 BSA below 1.7 m^2.[8]

± 0.05cm for every change of 0.1m^2 BSA

Devereux RB. Am J Cardiol 2012; 110:1189-94

Normal Dimensions

	GATED CT	GATED CT	MRI
AORTIC ROOT	3.6 cm		
ASCENDING	3.6 cm	2.1 cm/m^2	
DESCENDING	2.5 cm	1.8 cm/m^2	2.5 cm

How to Measure Aorta

Each modality is different

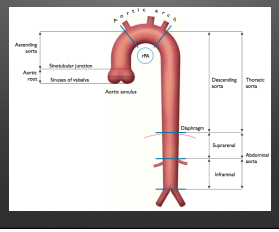

Echocardiography

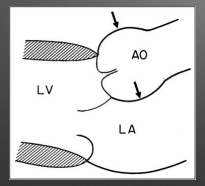

- Leading edge to leading edge
- End-diastole

CT and MRI

- Inner to Inner
- Must use multi-plane reconstruction (MPR)
- Sinus to Sinus x 3 average

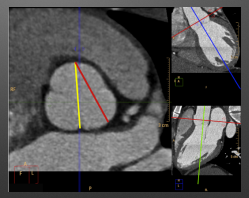

Multiplanar Evaluation- CT and MRI

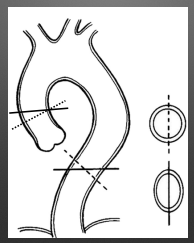

THE MARFAN FOUNDATION

Case

- 35 y.o. female with history of Marfan's syndrome presents for her annual physical exam and discussion for pregnancy
- Physical Exam
  - BP 130/80 HR of 80 bpm; height 66 in; weight 105lbs; BSA 1.56 m2
  - HEENT: arched palate
  - Chest: Mild pectus excavatum with normal BS
  - CV: normal S1 S2 RRR

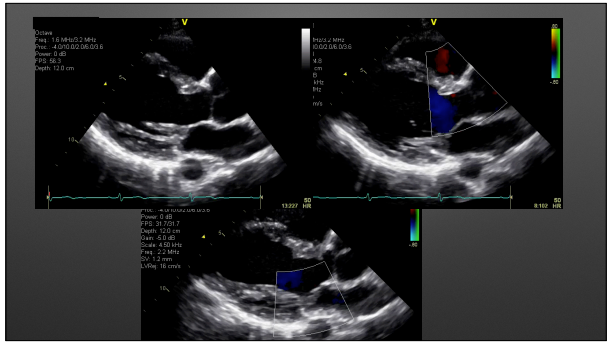

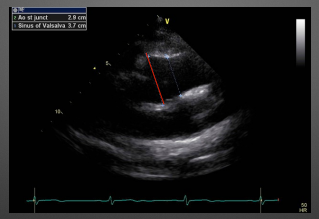

Sinus of Vasalva: 3.7cm

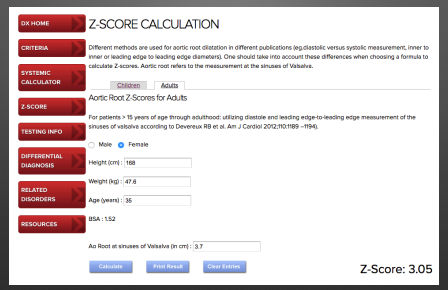

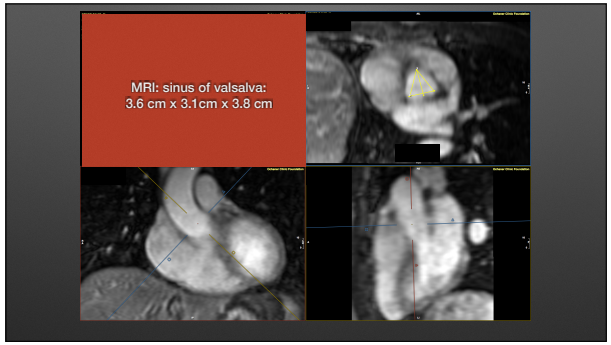
MRI: sinus of valsalva:
3.6 cm x 3.1cm x 3.8 cm

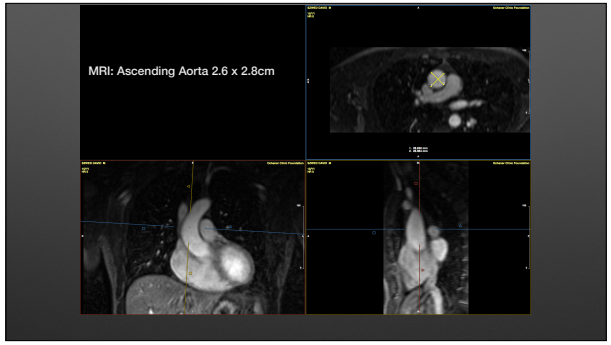
MRI: Ascending Aorta 2.6 x 2.8cm

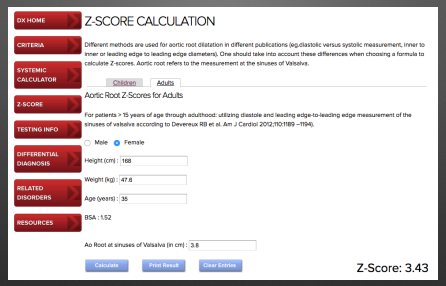

Identification of Risk in Marfan's

- Aorti
- con ent for age
- 18-

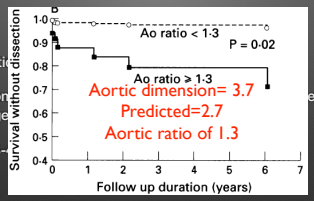

Legget. Heart 1996;75:389-395

CV Imaging Results

- Echo: Sinus of Valsalva by 3.7 cm (Z score of 3.05)
- Echo: Aortic Ratio of 1.3 (20% risk of dissection - 2 years)
- Cardiac MRI: Sinus of Valsalva 3.8cm (Z score of 3.43)
- Cardiac MRI: Ascending Aorta: 2.6 x 2.8cm

Maternal RISK for Pregnancy?

Maternal RISK

WHO II-III
Mild LV dysfunction >45%
Hypertrophic CM
Valvular disease
Marfan with aorta <40mm
Bicuspid AV with aorta <45mm
Repaired coarctation

- <40mm Dissection is rare
- BUT, need to consider BSA
  - >27mm/m^2 (24mm/m^2)
- Additional Risk of dissection
  - Family history
  - Previous dissection
  - Growth > 0.5mm/year

Maternal predictors of Neonatal Events Marfan Syndrome

RISK	OUR PATIENT
Baseline NYHA Class >II or cyanosis	Treadmill - 14 METs (>80%THR)
Maternal left heart obstruction	None
Smoking during pregnancy	None
Multiple gestation	Not planning
Use of oral anticoagulation during pregnancy	None
Mechanical valve prosthesis	None

Additional Neonatal Risk Marfan syndrome

- Risk of transmission is 50% - autosomal dominant
- Premature delivery

Proceed with Pregnancy

- Follow up Imaging
- Medications
- Lifestyle
- Delivery
- Long-term risk

Echocardiogram

- every 4-12 weeks up to 6 months postpartum

Medical therapy

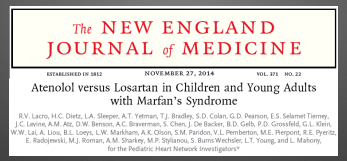
The NEW ENGLAND JOURNAL of MEDICINE

ESTABLISHED IN 1812 NOVEMBER 27, 2014 VOL. 371 NO. 22

Atenolol versus Losartan in Children and Young Adults with Marfan's Syndrome

R.V. Lacro, H.C. Dietz, L.A. Sleeper, A.T. Yetman, T.J. Bradley, S.D. Colan, G.D. Pearson, E.S. Selamet Tierney, J.C. Levine, A.M. Atz, D.W. Benson, A.C. Braverman, S. Chen, J. De Backer, B.D. Gelb, P.D. Grossfeld, G.L. Klein, W.W. Lai, A. Liou, B.L. Loeys, L.W. Markham, A.K. Olson, S.M. Paridon, V.L. Pemberton, M.E. Pierpont, R.E. Pyeritz, E. Radojewski, M.J. Roman, A.M. Sharkey, M.P. Stylianou, S. Burns Wechsler, L.T. Young, and L. Mahony, for the Pediatric Heart Network Investigators*

- Z-score > 3.0
- 608 participates 6 months to 25 yo
- Atenolol- 151 +75mg a day
- Losartan 85 +14mg a day
- No difference in change of Aortic size

Metoprolol Succinate

Lifestyles

- Smoking cessation including 2nd hand
- Blood pressures control
- Exercise: Aerobic preferred

Delivery

- Control blood pressure
- High risk OB
  - Vaginal Delivery if 40-45 mm WHO III
  - C-Section > 45 mm WHO IV
- Anesthesiologist
  - Scoliosis; Rods
  - Dural Ectasia

Maternal Risk- immediate and prolonged

- Risk of Dissection highest in 3rd trimester (50%) and postpartum up to 6 months (33%)
- Aortic root dilates during pregnancy and does not return to baseline

Disease of the Aorta

The Immediate and Long-Term Impact of Pregnancy on Aortic Growth Rate and Mortality in Women With Marfan Syndrome

Ryan T. Donnelly, MD, Nelangi M. Pinto, MD, Irene Kocolas, MD, Anji T. Yetman, MD
Salt Lake City, Utah

- 199 pregnancies
- baseline aorta 28-51mm with Z score 0.7-4.5
  - (27% of pregnancies ≥40mm)
- Clinical outcomes
  - Composite of death, aortic dissection, severe symptomatic AI or urgent surgery
  - Elective surgery

Immediate Outcomes

- Maternal Risk: No dissections
  - Progressive aortic dilation >5mm (2 patients)
  - Average increase of aorta of 3mm
- Neonatal Risk: Premature delivery (8 patients)

Hormonal changes of pregnancy dilate the aorta

Long-Term Adverse Cardiovascular Outcome

VARIABLE	ODDS RATIO	95% CONFIDENCE INTERVAL
AORTIC SIZE CHANGE	1.3	1.11-1.61
NUMBER OF PREGNANCY	1.5	1.15-1.97
PROSPECTIVE CARE	0.1	0.05-0.39
MEDICATIONS	0.3	0.14-0.92
AORTA > 4.0	3.8	1.11-13.3

2 patients had carotid artery dissection postpartum

Delivery and Follow up



- C-Section at 35 weeks due to concerns for baby
- Baby did not have Marfan syndrome
- No complications noted
- Aortic root size 8 weeks after delivery 37mm to 39 mm

Case

- 29 y.o. woman with repaired Tetralogy of Fallot (no palliative surgeries) presents to discuss her risk for pregnancy
- Physical exam: BP 108/60; HR 62 bpm; Height 64 inches; weight 117lbs
  - RRR with 3/6 early diastolic murmur at the left upper sternal boarder

Anatomy

- Large VSD
- Over-riding aorta
- RVOT obstruction- RVH
- Associated abnormalities
  - Hypoplastic pulmonary arteries
  - Right sided aortic arch
  - Anomalous coronary arteries

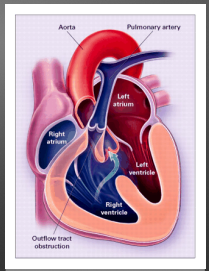

Primary Repair

- Closure of VSD
- Transannular RVOT patch work with relief of RVOT/PV obstruction
- Possible reconstruction of pulmonary arteries

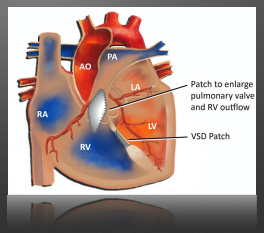

Right Heart Complications

- Pulmonary regurgitation
- RV enlargement and dysfunction
- Tricuspid regurgitation
- Pulmonary artery stenosis

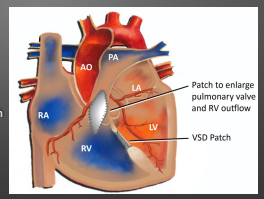

Left heart complications

- Dilation of aorta
- LV dysfunction

Ghai. JACC 2002;40:1675-1680

Guidelines and Standards

Multimodality Imaging Guidelines for Patients with Repaired Tetralogy of Fallot: A Report from the American Society of Echocardiography
Developed in Collaboration with the Society for Cardiovascular Magnetic Resonance and the Society for Pediatric Radiology

Anne Marie Valente, MD, FASE, Co-Chair, Stephen Cook, MD, Pierluigi Festa, MD, H. Helen Ko, BS, RDMS, RDCS, FASE, Rajesh Krishnamurthy, MD, Andrew M. Taylor, MD, Carole A. Warnes, MD, Jacqueline Kreutzer, MD, and Tal Geva, MD, FASE, Co-Chair, *Boston, Massachusetts; Pittsburgh, Pennsylvania; Massa, Italy; New York, New York; Houston, Texas; London, United Kingdom; Rochester, Minnesota*

(J Am Soc Echocardiogr 2014;27:111-41.)

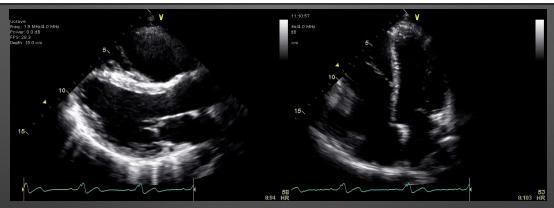

- PLAX
  - Normal size and mild reduced systolic LV function
  - Normal LA size
  - Sinus of valsalva 2.7cm
- 4 chamber
  - RV FAC 42%
  - RVED basal diameter 4.6cm
  - Septum moves toward the LV during diastole
  - LVEF by Simpson's 53%

- Unrestricted, severe PI

Maternal Risk: Small mortality and significant morbidity

WHO II	WHO II-III
unoperated ASD or VSD	Mild LV dysfunction >45%
Repaired Tetralogy of Fallot	Hypertrophic CM
Most arrhythmia	Valvular disease
	Marfan with aorta <40mm
	Bicuspid AV with aorta <45mm
	Repaired coarctation

MRI allow quantification of Complications

- Pulmonary regurgitation
- RVOT obstruction/aneurysm
- RV enlargement and dysfunction
- Tricuspid regurgitation
- Pulmonary artery stenosis
- Dilation of Aorta
- LV dysfunction

RV dilation & dysfunction

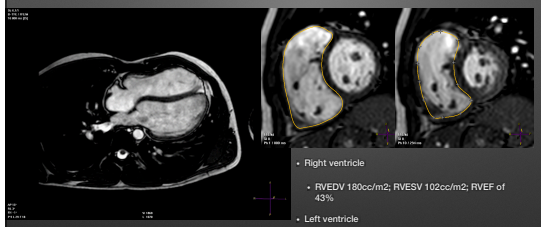

- Right ventricle
  - RVEDV 180cc/m2; RVESV 102cc/m2; RVEF of 43%
- Left ventricle
  - LVEDV of 85cc/m2; LVESV 38cc/m2; LVEF of 55%

Oosterhof T. Circulation 2007;116:545-551

Unrestricted Pulmonary regurgitation

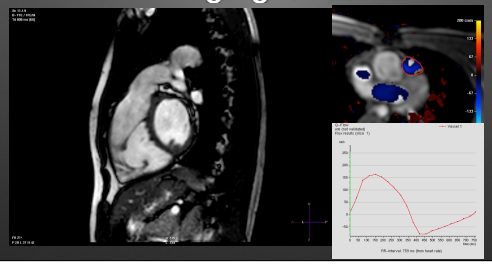

MR Angiogram

- No pulmonary artery stenosis
- No aortic dilation

Tan. Circulation
2005;112:961-68

Exercise Capacity

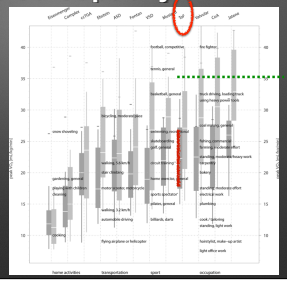

- Peak VO2 of 36 ml/kg/min

Kemeny. European Heart
Journal 2012; 33:1386-96

Maternal predictors of Neonatal Events Marfan Syndrome

RISK	OUR PATIENT
Baseline NYHA Class >II or cyanosis	Peak V O2 > average
Maternal left heart obstruction	None
Smoking during pregnancy	None
Multiple gestation	???
Use of oral anticoagulation during pregnancy	None
Mechanical valve prosthesis	None

Fertility Treatment

- Risk of multiple gestation of 27%
- Initial treatment with OC or GnRH - increase PVR
- Subsequent Estrogen - decrease PVR increase CO
- Prothrombogenic state

Rossberg. European J Preventive Card 2016; 23:1953-61

- Arrhythmia
- Symptomatic Heart Failure
- Progressive RV dilation

- Small for gestation
- Risk of CHD
- Increased mortality - multi gestation

Downing. Cardiology Clinic 2015;33:531-41

Proceed with Pregnancy

- Follow up Imaging
  - If symptoms and then 3rd timester
- Medications
  - No medications
- Lifestyle
  - Healthy
- Delivery
  - No limitations
- Long-term risk
  - progressive RV dilation

Delivery and Follow up: Repaired Tetralogy of Fallot



- Vaginal Delivery of a Term baby Boy
- Lasix for about 2 weeks post delivery
- No significant arrhythmias

Conclusion

- More women with heart disease are undergoing pregnancy
- World Health Organization risk classification
- CV imaging and stress testing
- Heart disease can be progressive during pregnancy