

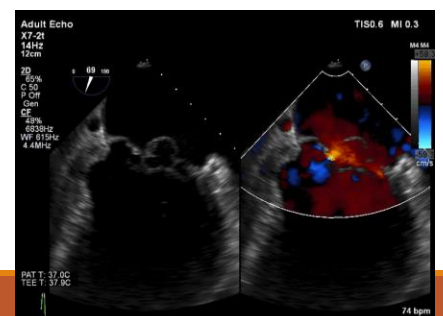
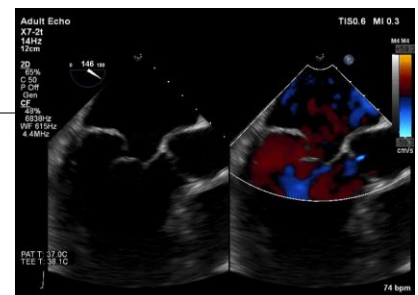
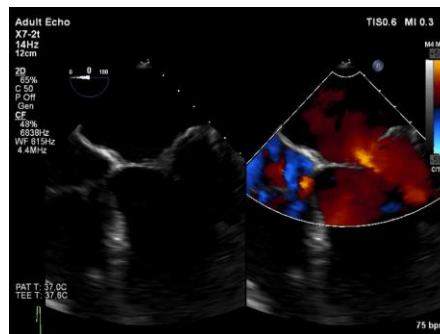
# Coffee and cases

## I use 3D for Valve Cases all the time

MADALINA PETRESCU, MD  
 SWEDISH MEDICAL CENTER  
 JANUARY 2018

Case 1: 50 yo M presenting with  
 increasing dyspnea  
*What is the pathology?*

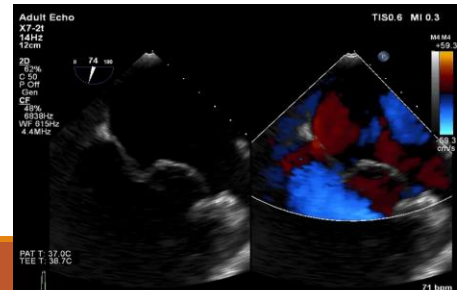
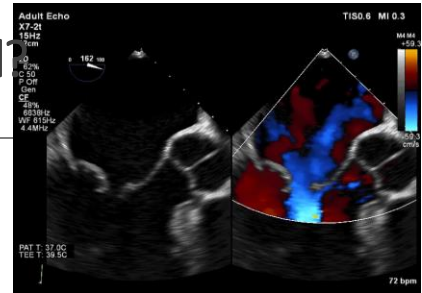
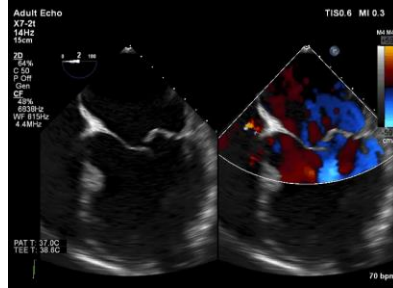
- A. Flail P1
- B. Flail P2
- C. Flail A2
- D. Flail A2



# MVP case #2: Which scallop is involved

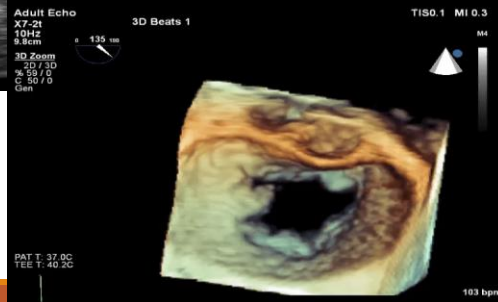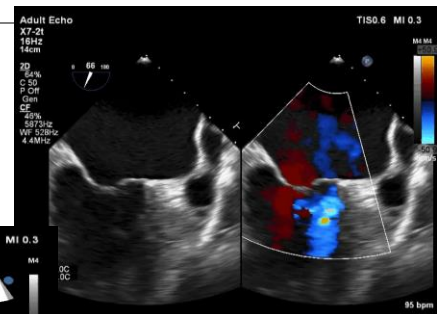
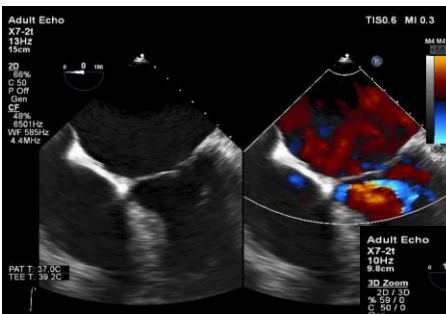
*53 yo M with exercise intolerance & fatigue*

- A. Flail P1
- B. Flail P3
- C. Flail A1
- D. Flail A3



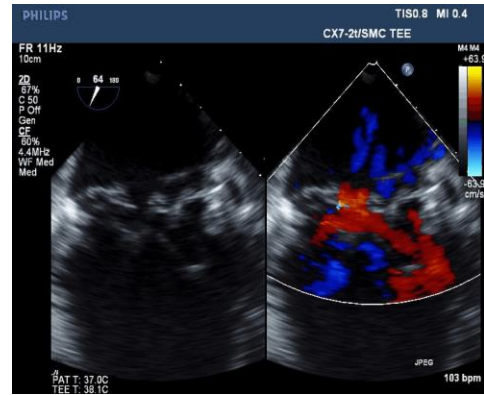
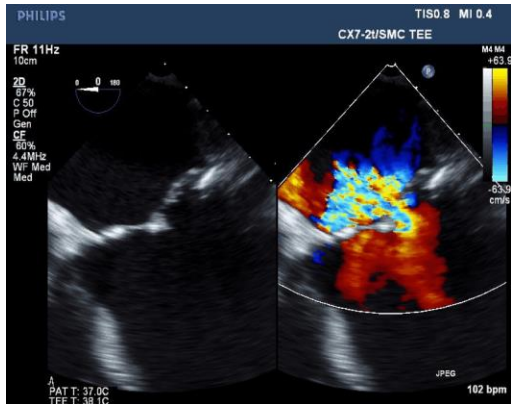
# No 2 flail pathologies are created equal

*80 yo frail female with multiple co-morbidities with increasing dyspnea referred to our structural program for consideration of mitralclip repair*

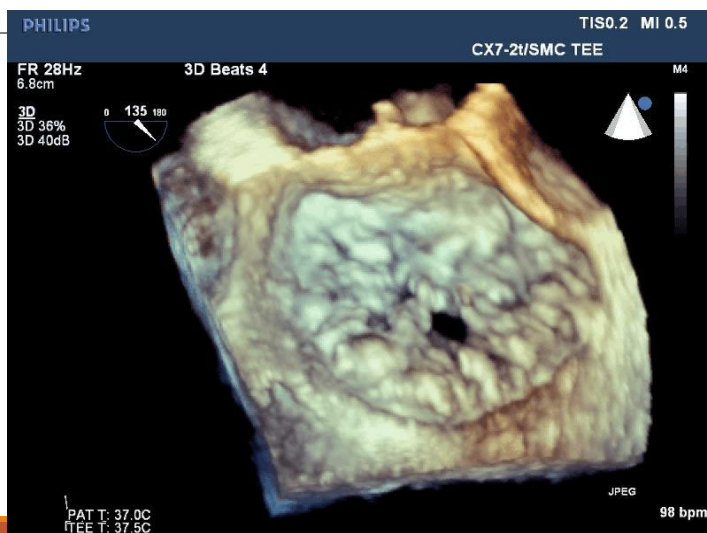

## Case #3: Which scallop is flail?

78 yo F + DOE, referred to heart team for surgery vs mitralclip

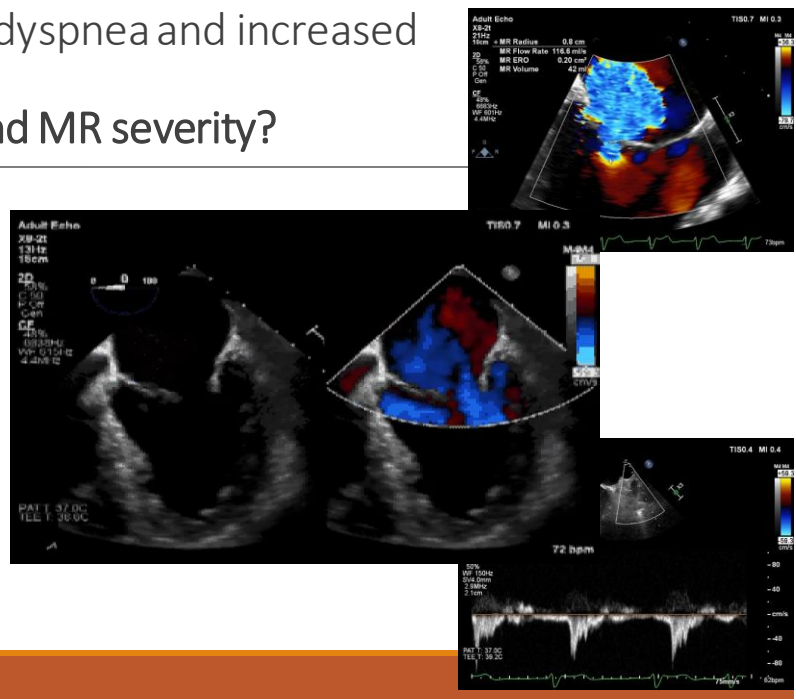


## 3D en face view

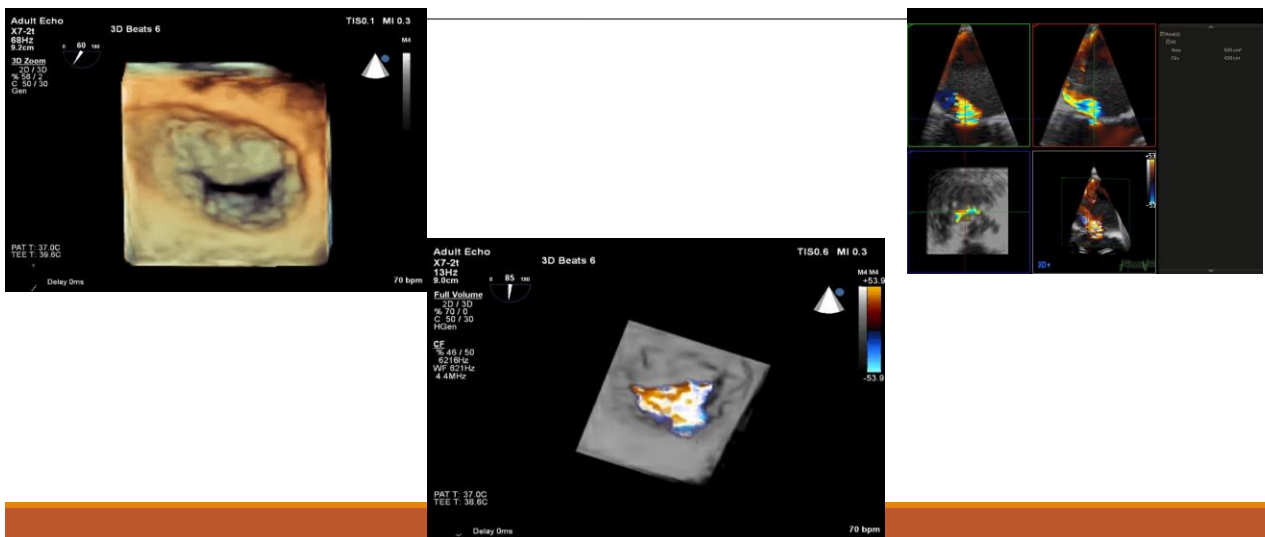


80 Y F with progressive dyspnea and increased hospitalizations for HF  
 What's the pathology and MR severity?

- A. FMR with significant MR
- B. FMR with non-significant (mild) MR
- C. DMR with significant MR
- D. DMR with non-significant (mild) MR

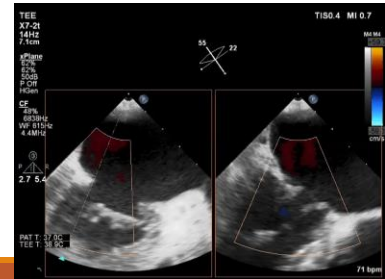
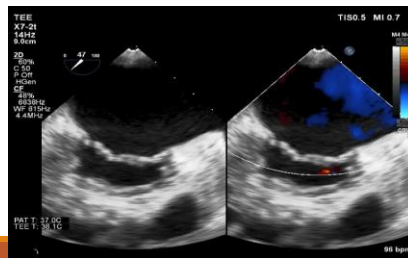
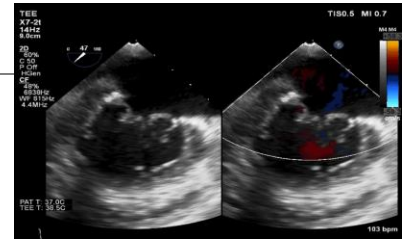
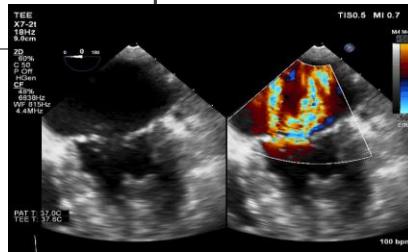


Benefit of 3DE:  
 Insight into mechanism and disease severity

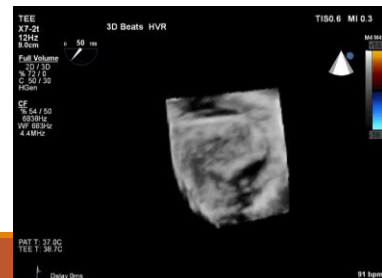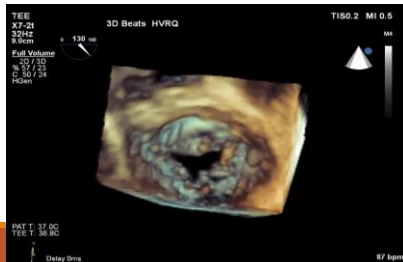
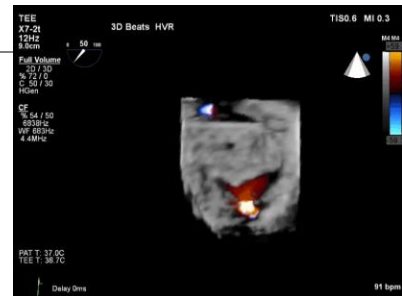
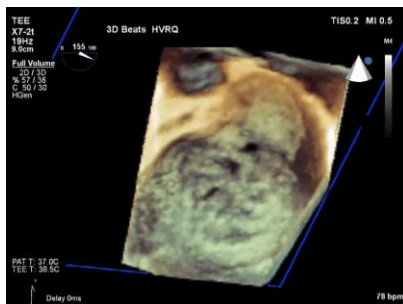


85 yo with SOB referred to the structural clinic for consideration of mitralclip:  
Pathology?

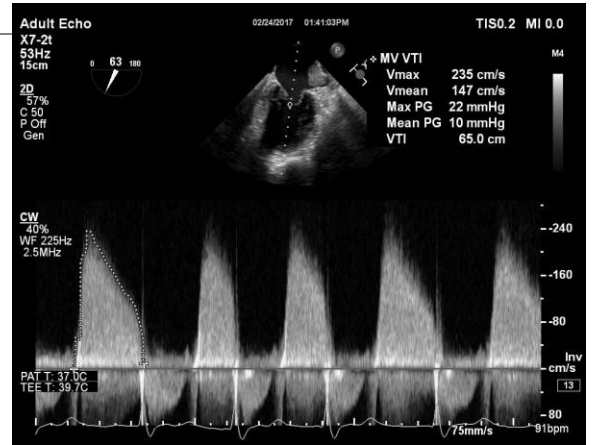
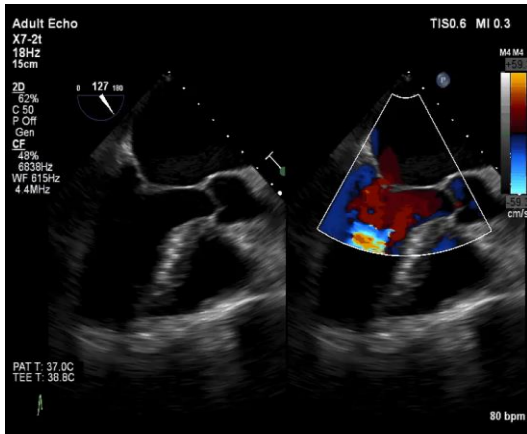
- A. Anterior leaflet cleft
- B. Posterior leaflet cleft
- C. Anterior leaflet perforation
- D. Posterior leaflet perforation



3DE en face view, with color



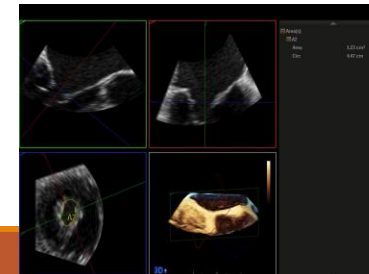
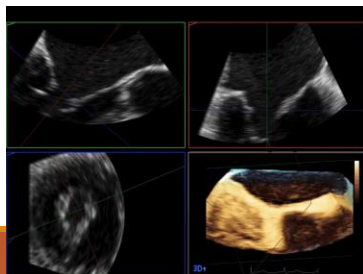
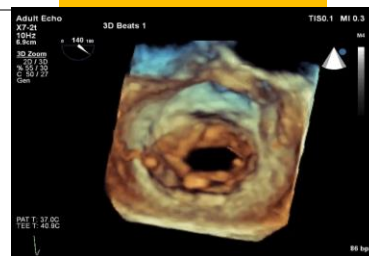
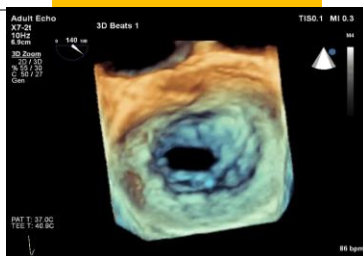
# 73 yo admitted with rapid afib and CHF



## A better understanding using 3DE

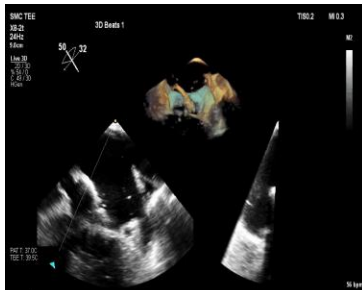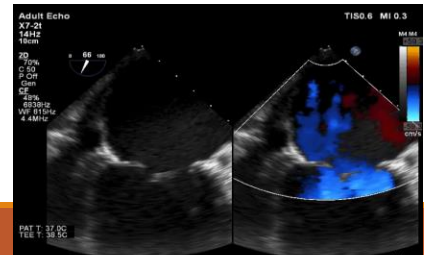
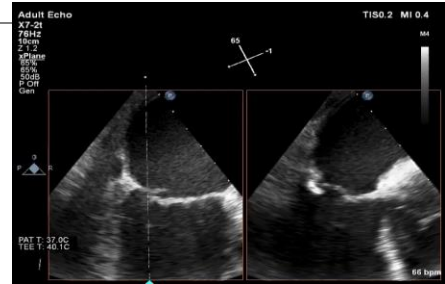
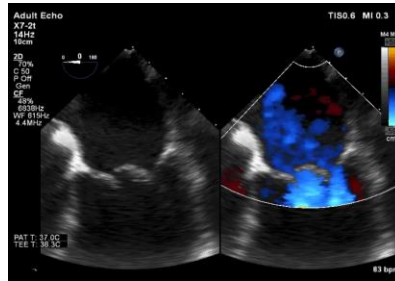
**Above the valve**

**Below the valve**

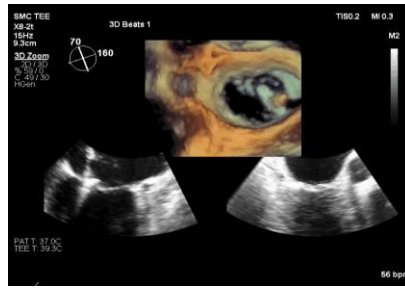


# 80 yo with DOE referred for consideration for mitraclip What's the pathology?

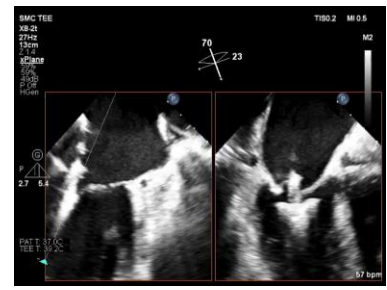
- A. A2 flail
- B. A3 flail
- C. P2 flail
- D. P3 flail



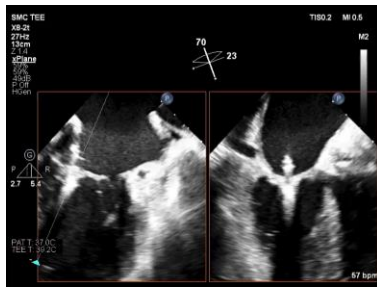#1: Mitraclip brought to level of MV



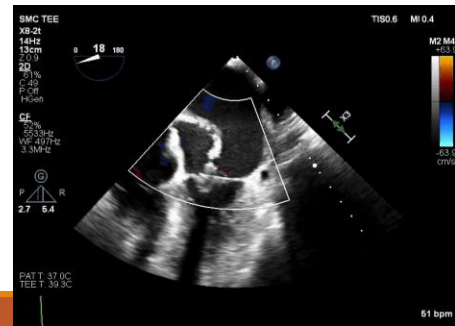
#2: Mitraclip positioning across MV



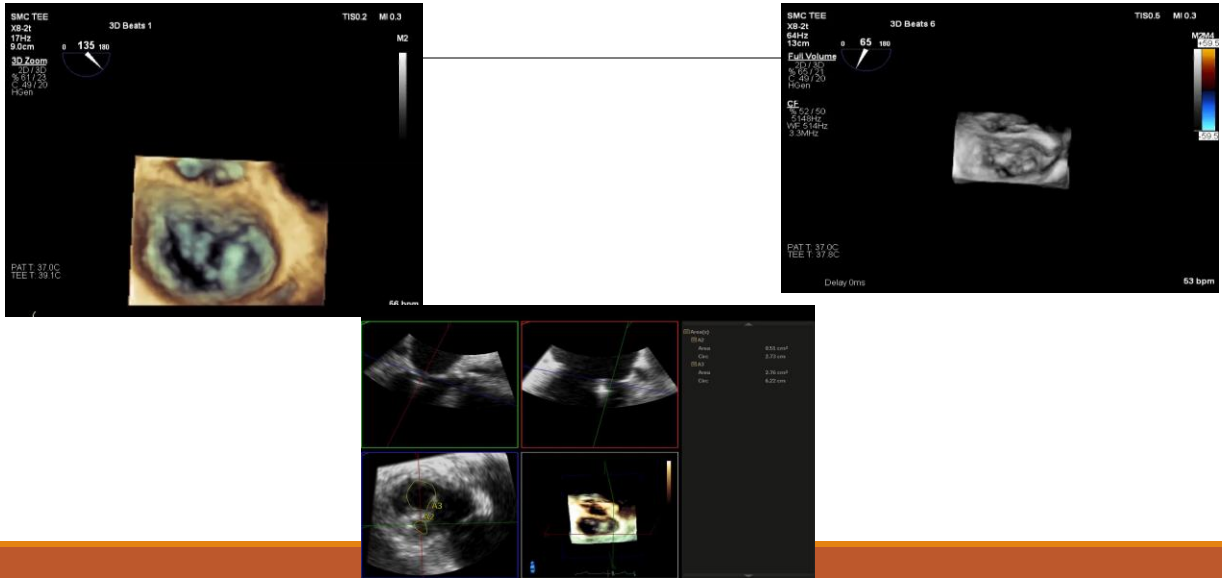
#3: Leaflet grasping



#4: Leaflets grasped



# Final result



Thank you for your attention!