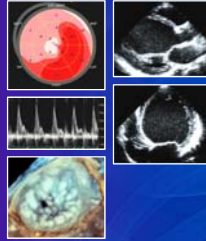




Pericardial Diseases Illustrative Cases



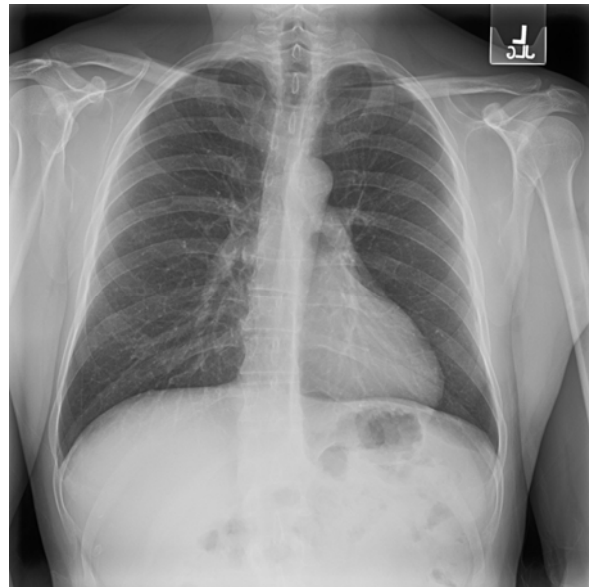
Jae K. Oh, MD

©2018 MFMR | 3712003-1

Case #1

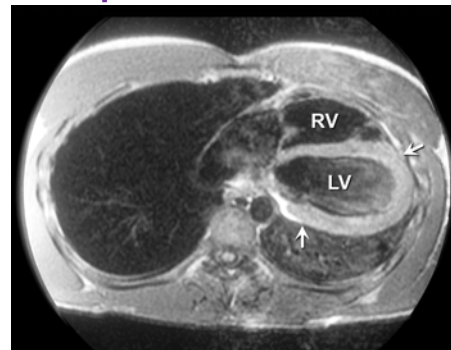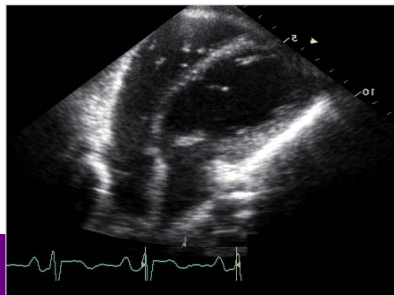
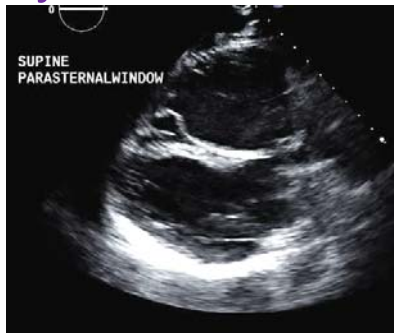47 year old man

- Chest pain
- Not exertional
- Normal Examination



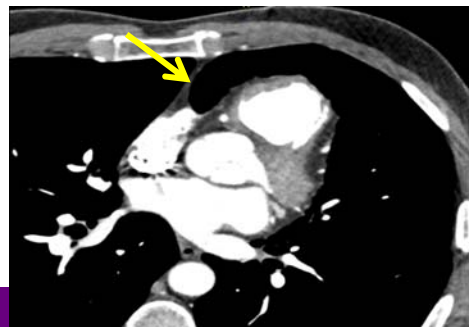
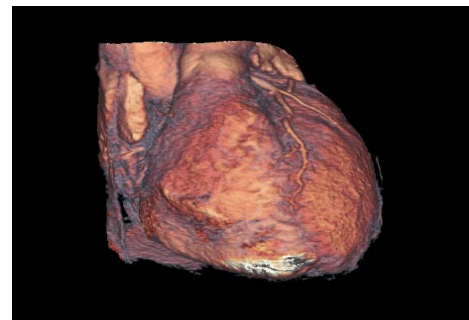
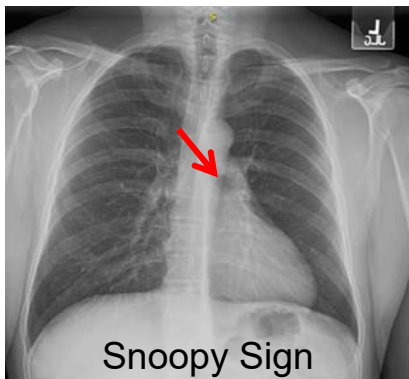©2018 MFMR | 3712003-2

47 year old man with chest pain

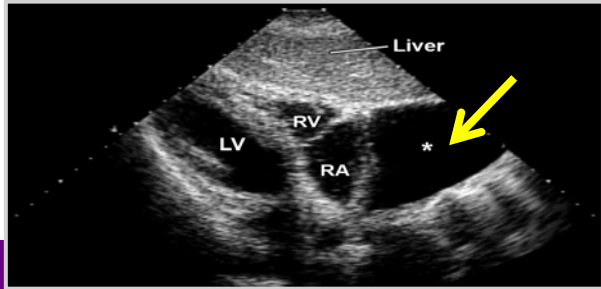
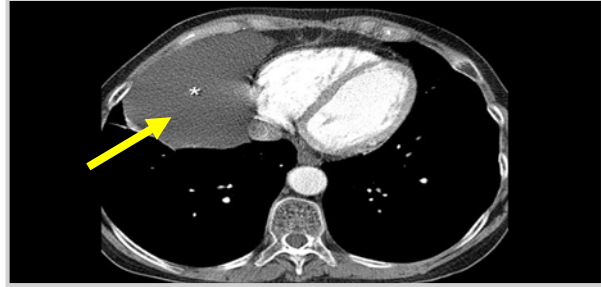
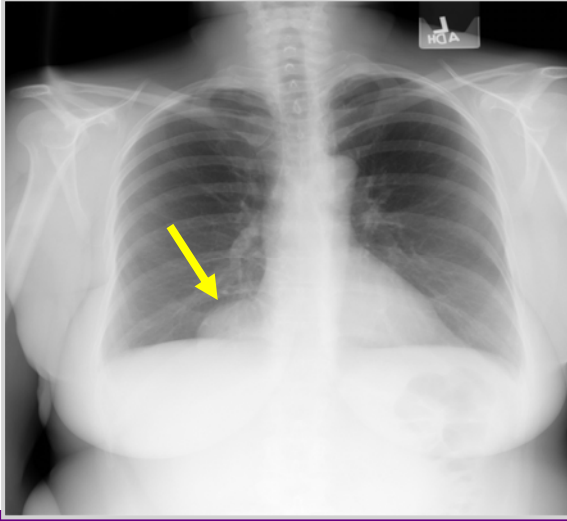


- Usually left side
- Heart shifted to left
- Mostly asymptomatic
- Strangulation can happen

Congenital Absence of the Pericardium

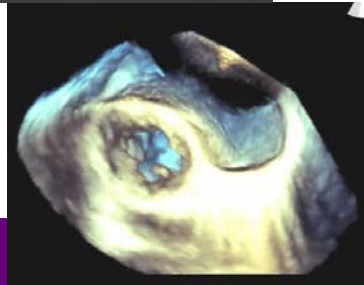
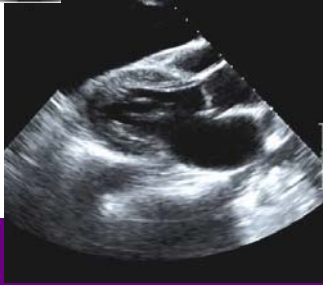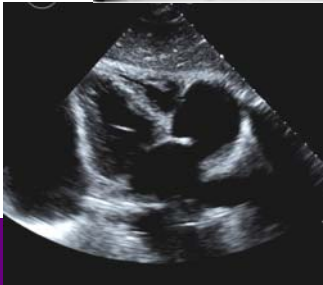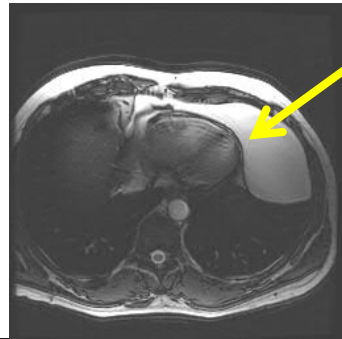


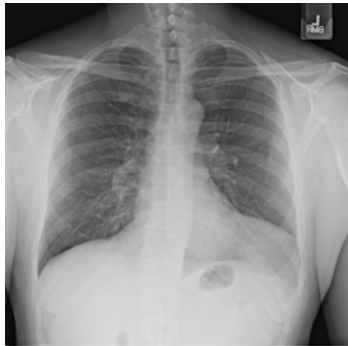Case #2 Pericardial Cyst



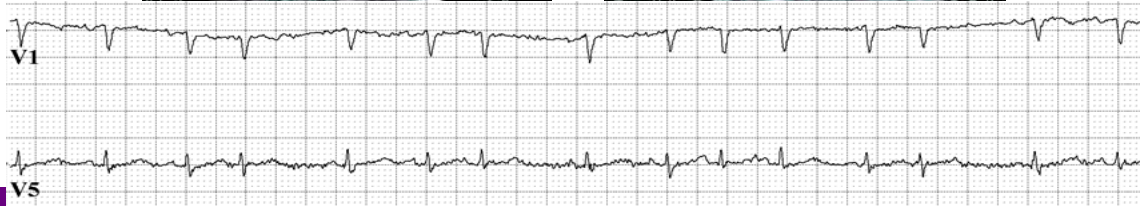
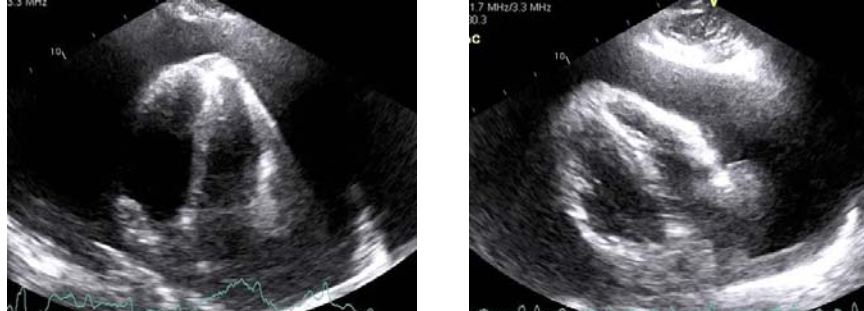©2018 MFMER | 3712003-5

A large pericardial cyst



©2018 MFMER | slide 6 | 3712003-6

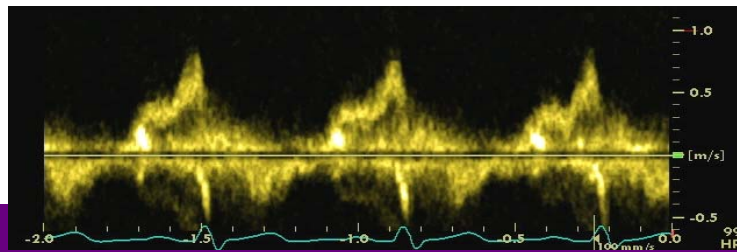
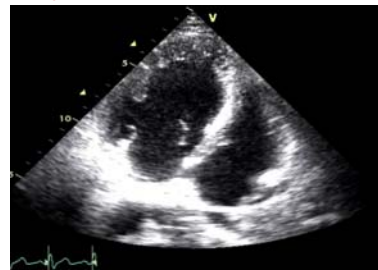
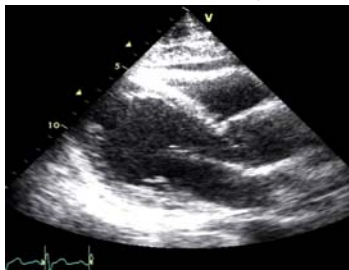Case #3
51 year old with SLE and BP 150/115



©2018 MFMER | 3712003-7

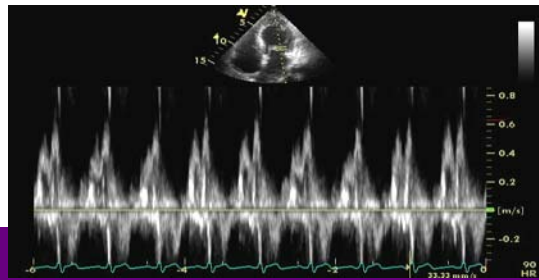
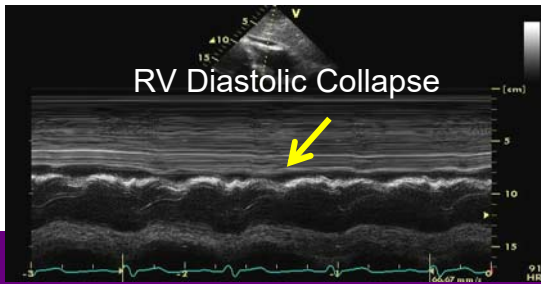
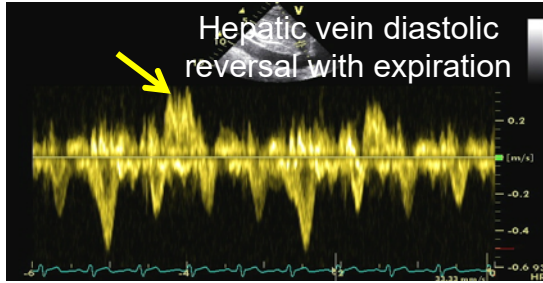
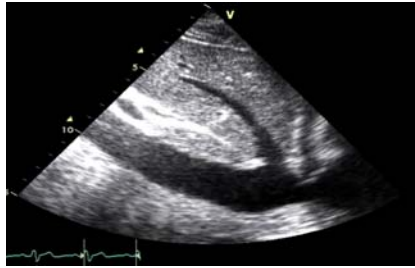
Case #4

57 year old male with STEMI
Thrombolysis and Stent
Hypotensive and tachycardic



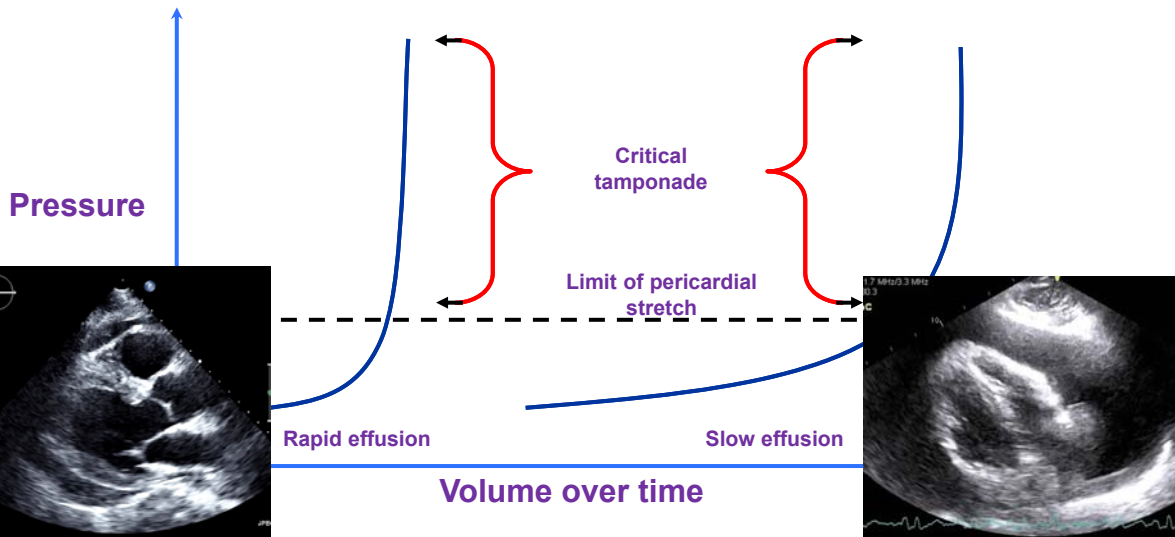
©2018 MFMER | 3712003-8

57 year old man with STEMI



©2018 MFMER | 3712003-9

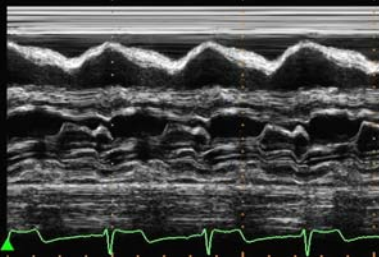
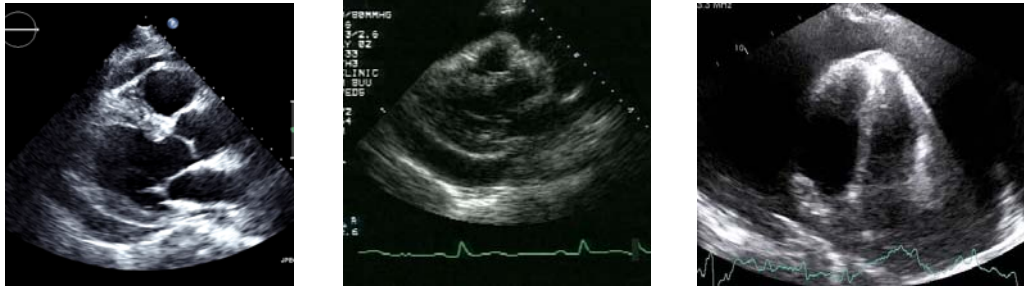
Tamponade Physiology



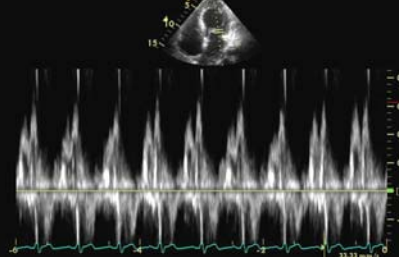
NEJM 349: 684, 2003 CP1299236-6

©2018 MFMER | 3712003-10

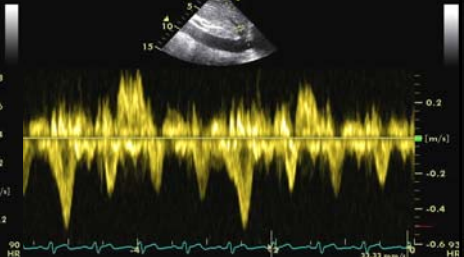
Cardiac Tamponade



RV collapse



Mitral inflow variation



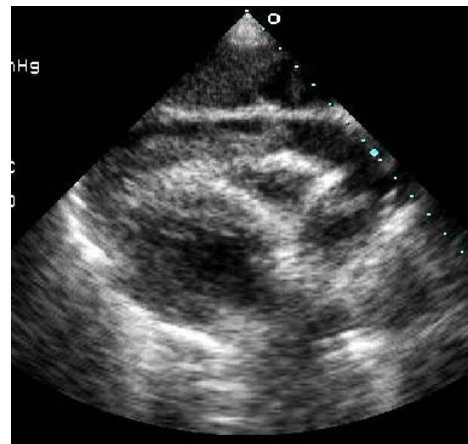
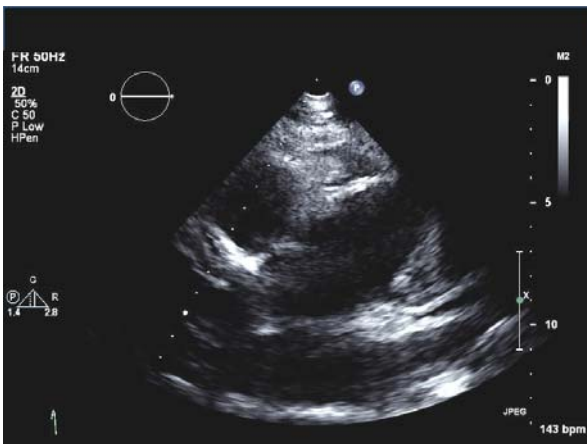
HV expiratory reversal



©2018 MFMER | 3712003-11

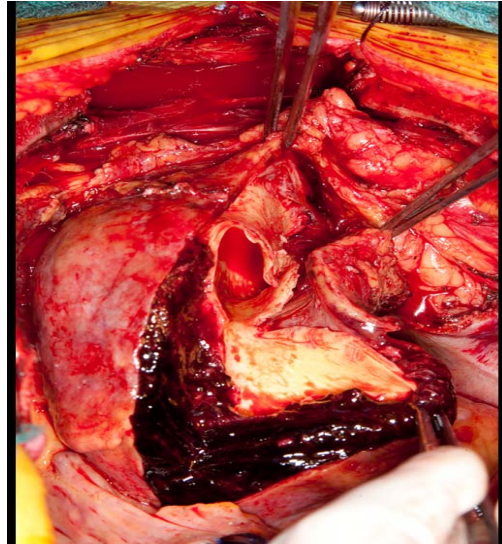
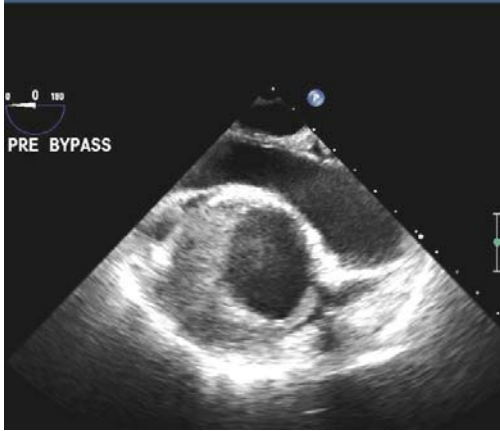
Case #5

Hemo-pericardium



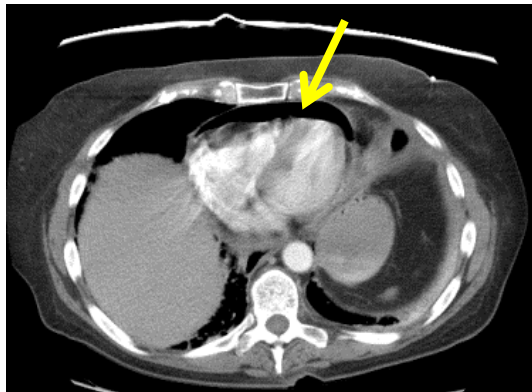
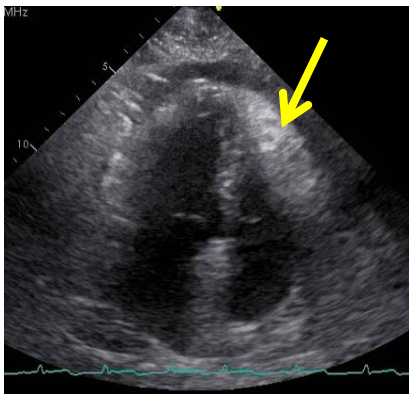
©2018 MFMER | 3712003-12

Intramural Hematoma



Case #6

66 year old woman with dyspnea
Pneumo-pericardium



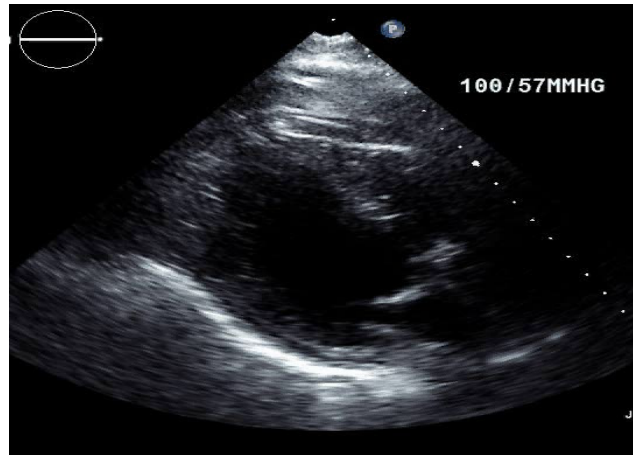
Gastro-pericardial fistula



Case #7

77 yo man with severe aortic stenosis

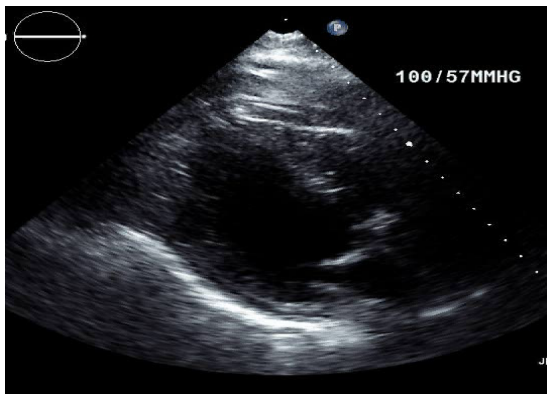
TAVR and PM implantation & RV Perforation



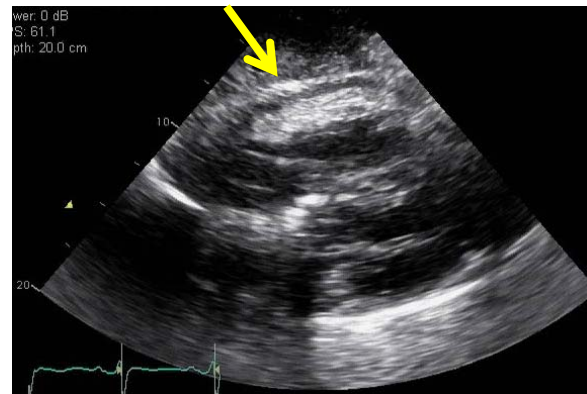
Pericardiocentesis yielded 125 cc of bloody fluid



77 yo man with severe aortic stenosis
Increasing dyspnea 2 months after pericardiocentesis



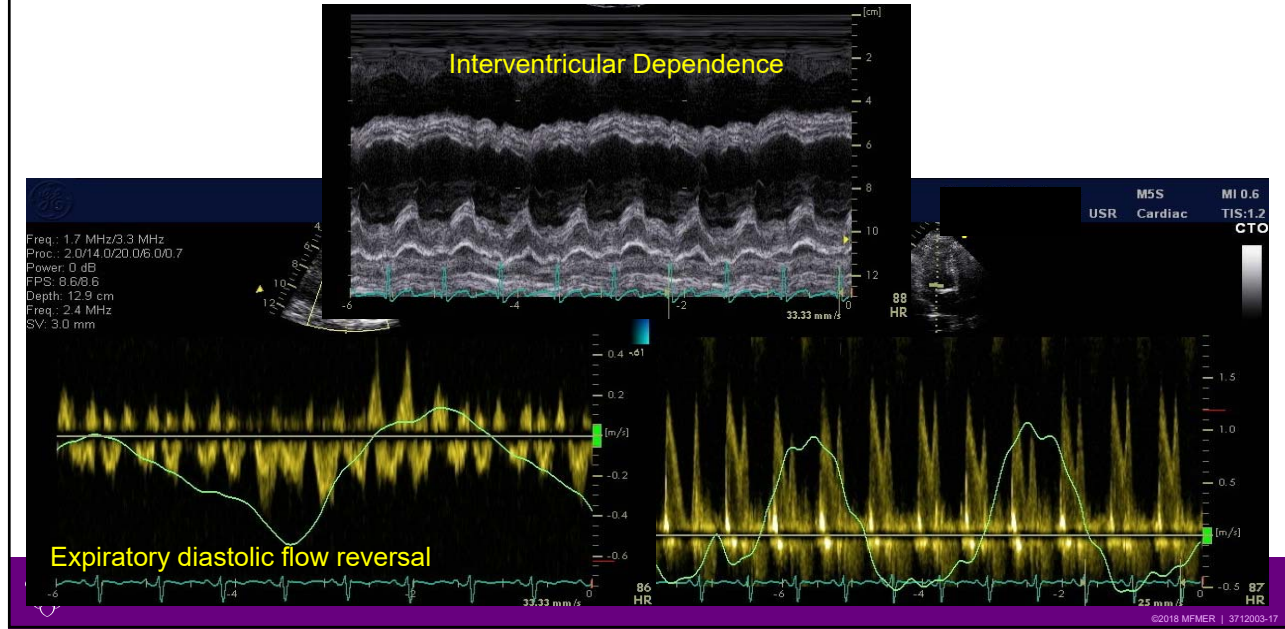
After Pericardiocentesis



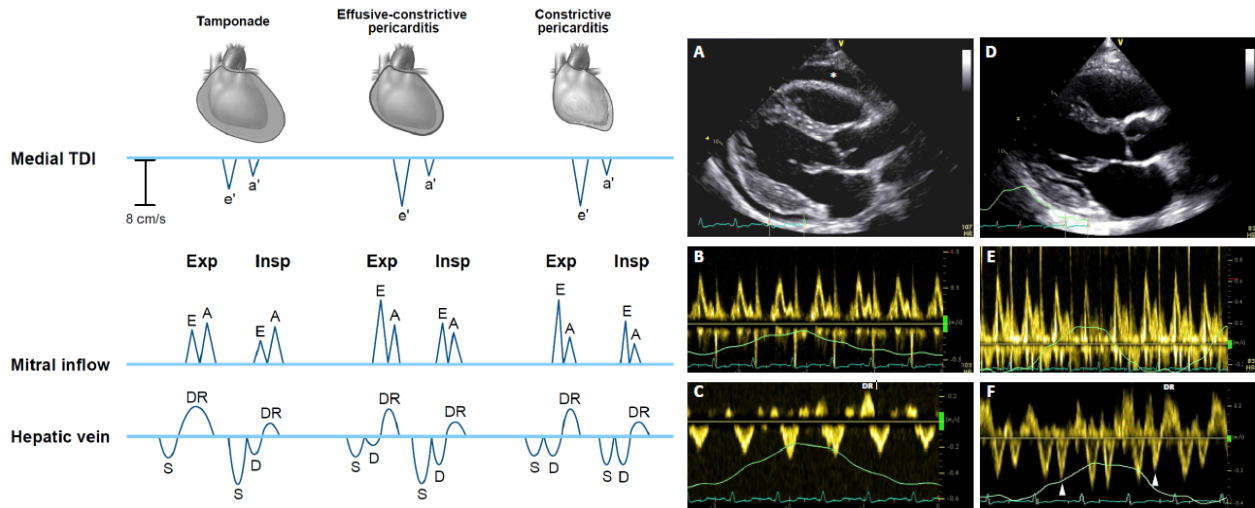
2 months later



Effusive-Constrictive Pericarditis



Tamponade vs Effusive CP



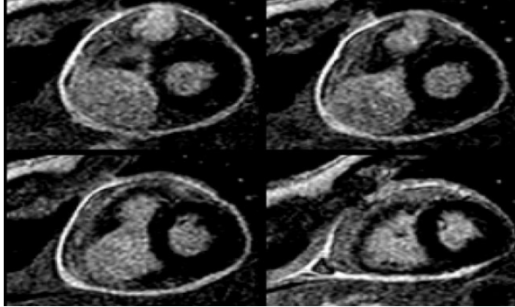
Miranda et al. In Preparation

©2018 MFMER | 3712003-18

Cardiac Magnetic Resonance Imaging Pericardial Late Gadolinium Enhancement and Elevated Inflammatory Markers Can Predict the Reversibility of Constrictive Pericarditis After Antiinflammatory Medical Therapy

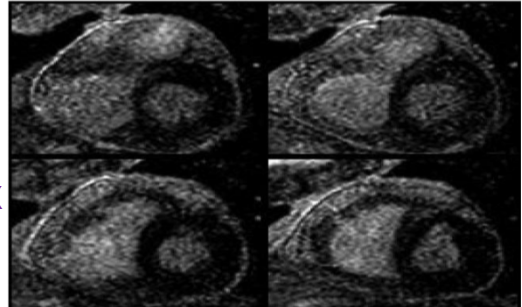
A Pilot Study

DaLi Feng, MD; James Glockner, MD, PhD; Kye-hun Kim, MD; Matthew Martinez, MD; Imran S. Syed, MD; Philip Araoz, MD; Jerome Breen, MD; Raul E. Espinosa, MD; Thoralf Sundt, MD; Hartzell V. Schaff, MD; Jae K. Oh, MD



Baseline

Medical RX



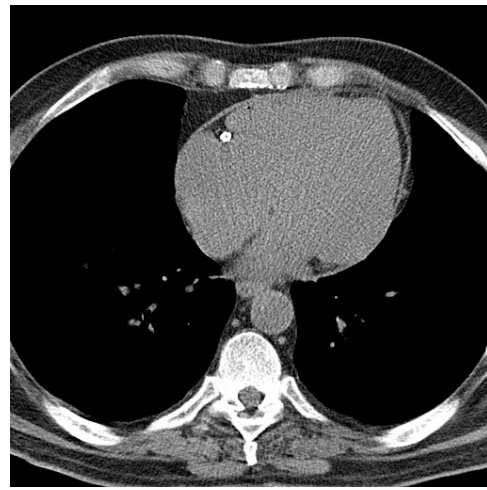
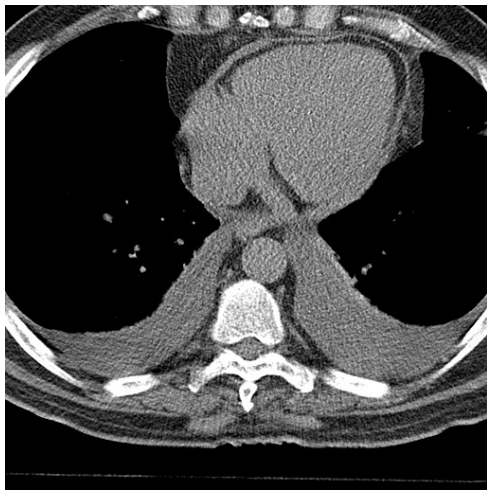
3 Months



Circulation Oct 3rd 2011

©2011 MFMR | 4886-10
©2018 MFMR | 3712003-19

Transient Constrictive Pericarditis One week of Steroid Rx



©2011 MFMR | 4886-20
©2018 MFMR | 3712003-20

Transient Constriction

	Reversible (N=14)	Persistent (N=15)
Age	54 ± 17	59 ± 16
LVEF	57 ± 3	60 ± 3
E' (cm/sec)	12 ± 1	11 ± 1
Steroid Rx	71 %	53 %
Pericardium	3.8 ± 0.6 mm	4.0 ± 0.6 mm
DE Pericardium	4.4 ± 0.4 mm	2.1 ± 0.4mm
Grade 3-4/4 DE	93 %	33 %
Sed rate	45 to 4	25 to 20
CRP	75 to 2	14 to 15

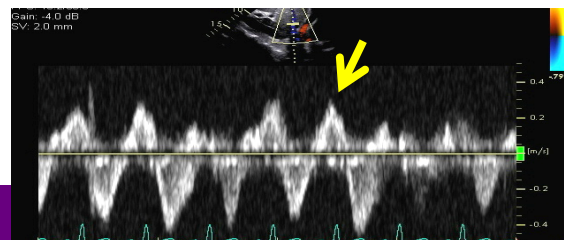
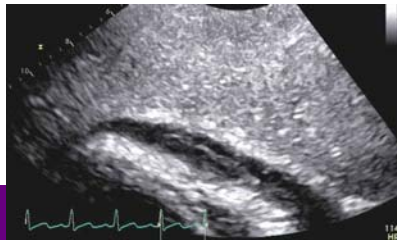
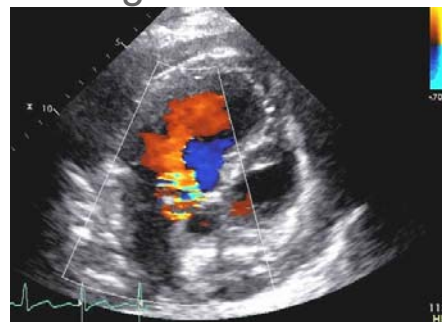
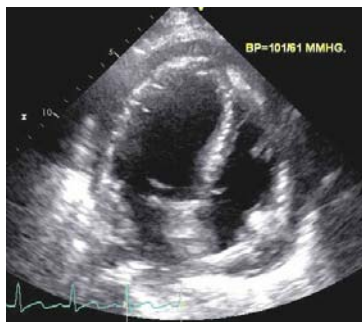

©2011 MFEMER | slide-21
©2018 MFEMER | 3712003-21

Case #8

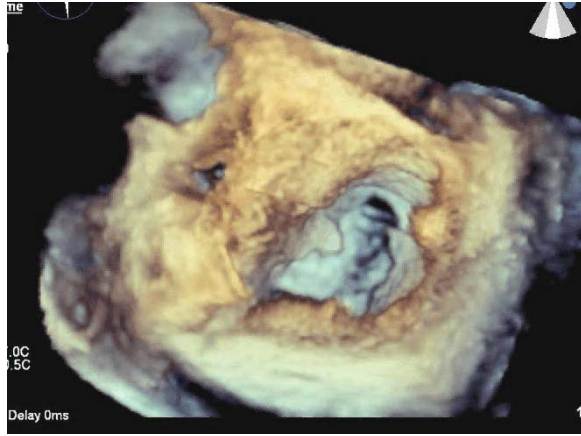
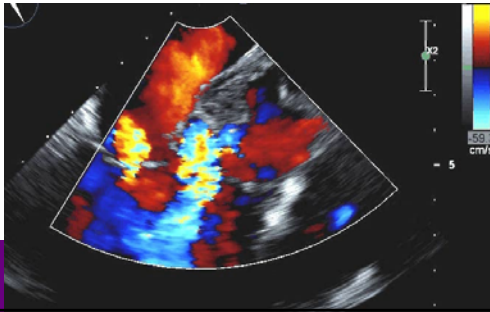
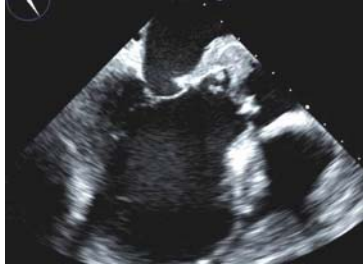35 yo man presents with dyspnea and fever

BP 80/40 mmHg



112 MER | 3712003-22

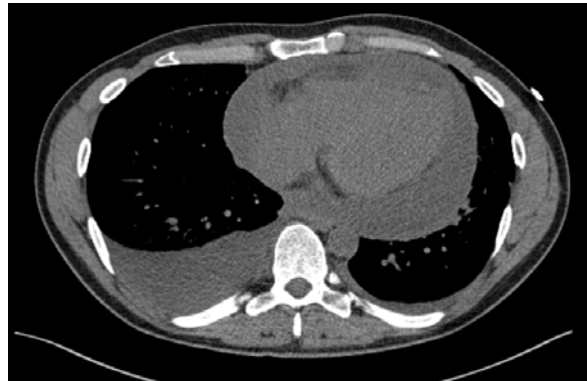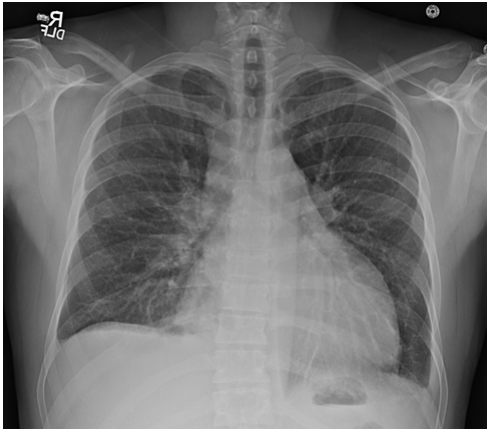35 yo man with tamponade and fever TEE after pericardiocentesis



©2018 MFMER | 3712003-23

Case #9

36 yo man with dyspnea, chest pain, and abd pain



©2018 MFMER | 3712003-24

Case #9

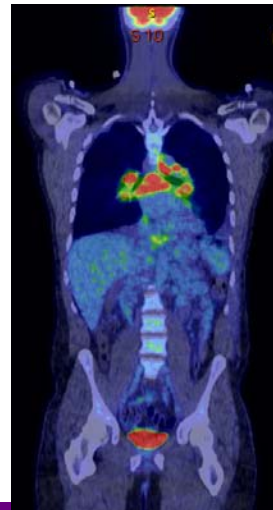
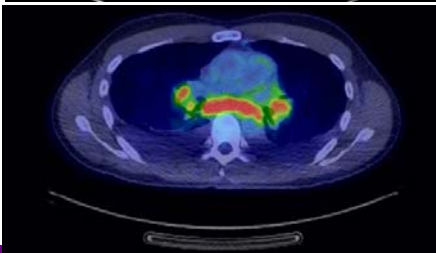
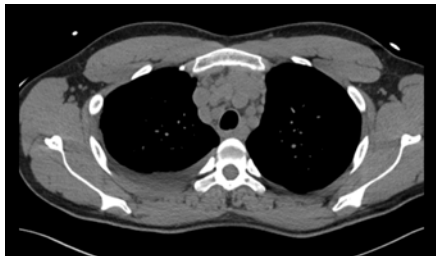
36 yo man with dyspnea, chest pain, and abd pain



©2018 MFMER | 3712003-25

Case #9

36 yo man with dyspnea, chest pain, and abd pain



Sarcoidosis

©2018 MFMER | 3712003-26

Pericardial Diseases and Tamponade

Take home message

- Always, identify underlying cause for pericarditis, pericardial effusion or tamponade
- Echo diagnosis of tamponade
 - Plethoric IVC
 - Diastolic collapse of RV, RA and LA
 - Interventricular dependence
 - Diastolic HV flow reversal with expiration
- We may be able to identify the patients who may develop effusive-constrictive pericarditis at the time of pericardiocentesis



©2018 MFMER | 3712003-27

Thank You !

Oh.jae@mayo.edu

Jaekuen.oh@samsung.com



©2018 MFMER | 3712003-28



©2012 MFMER | 3213949-29
©2018 MFMER | 3712003-29

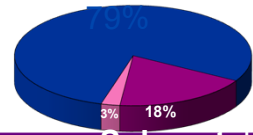
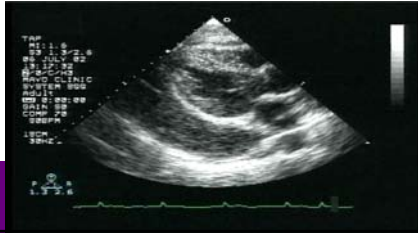
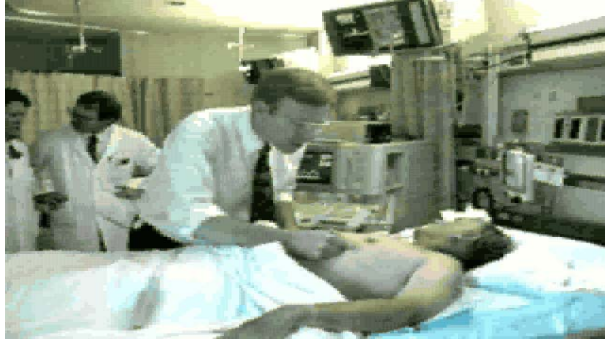

Questions & Discussion



©2018 MFMER | 3712003-30

Echo-Guided Pericardiocentesis



**Subcostal
Location**

