

MRI in Myocardial Disease: Where You Must Use It in 2017

Echo Florida 2017

Seth Uretsky, MD, FACC

Medical Director, Cardiovascular Imaging

Atlantic Health System

Associate Professor of Medicine, Sidney Kimmel Medical College

Thomas Jefferson University



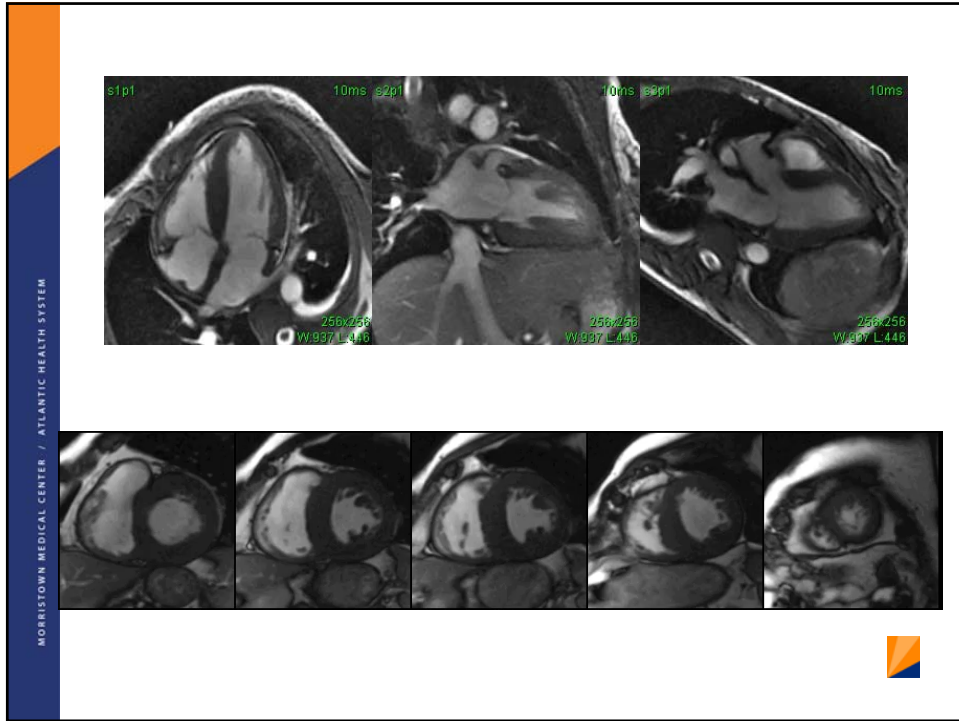
MORRISTOWN MEDICAL CENTER / ATLANTIC HEALTH SYSTEM

Case 1

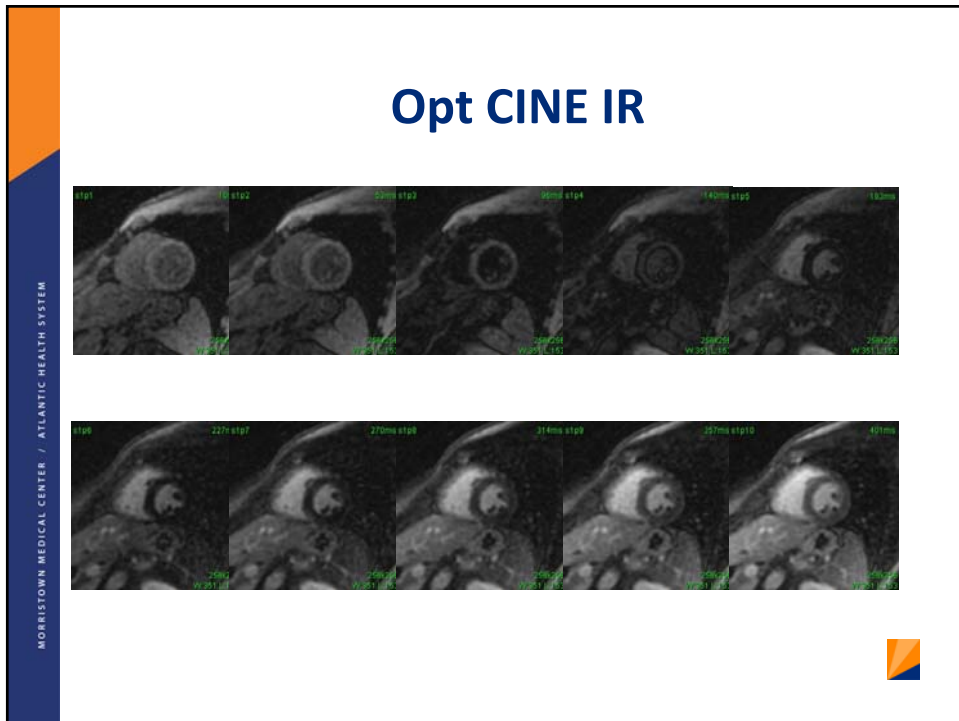
- 65 y/o male with LVH on TTE

MORRISTOWN MEDICAL CENTER / ATLANTIC HEALTH SYSTEM

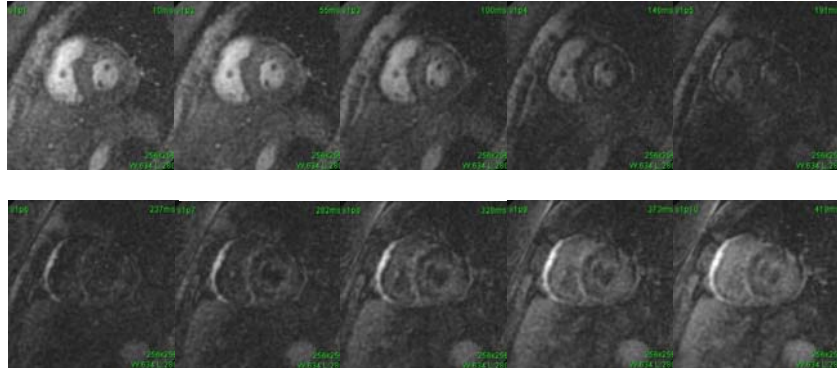




Opt CINE IR



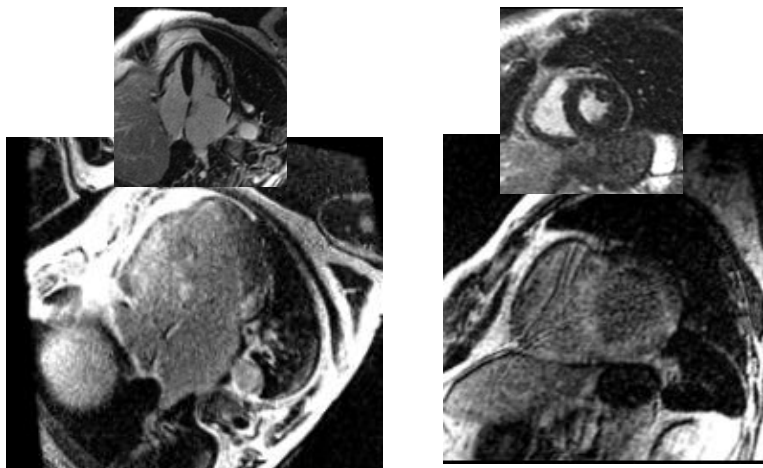
Opt CINE IR



MORRISTOWN MEDICAL CENTER / ATLANTIC HEALTH SYSTEM



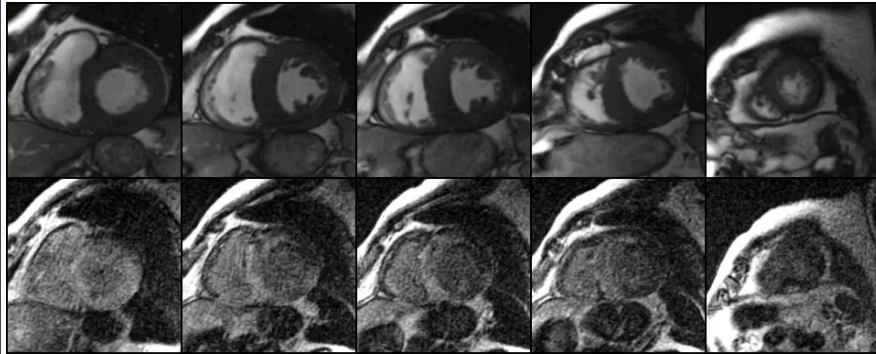
LGE: Amyloid



MORRISTOWN MEDICAL CENTER / ATLANTIC HEALTH SYSTEM



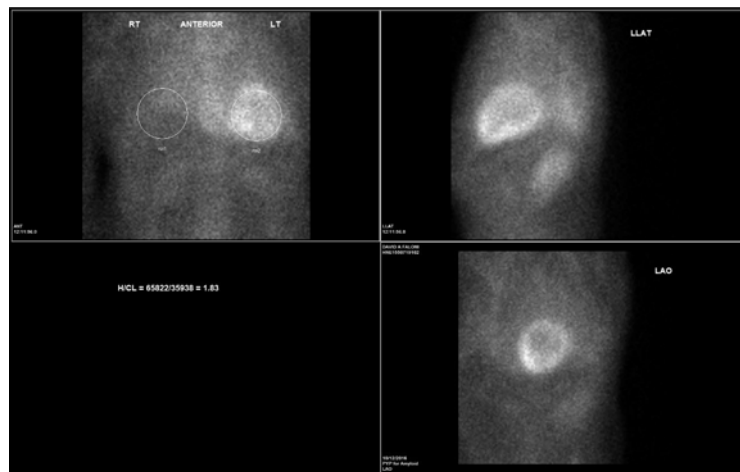
Amyloid



MORRISTOWN MEDICAL CENTER / ATLANTIC HEALTH SYSTEM

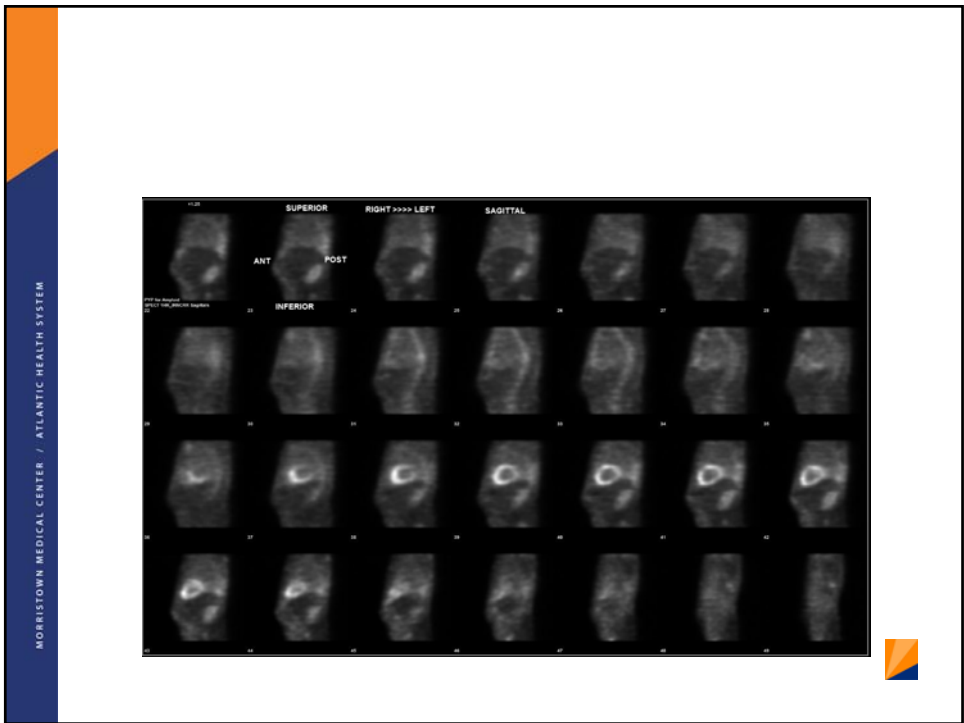
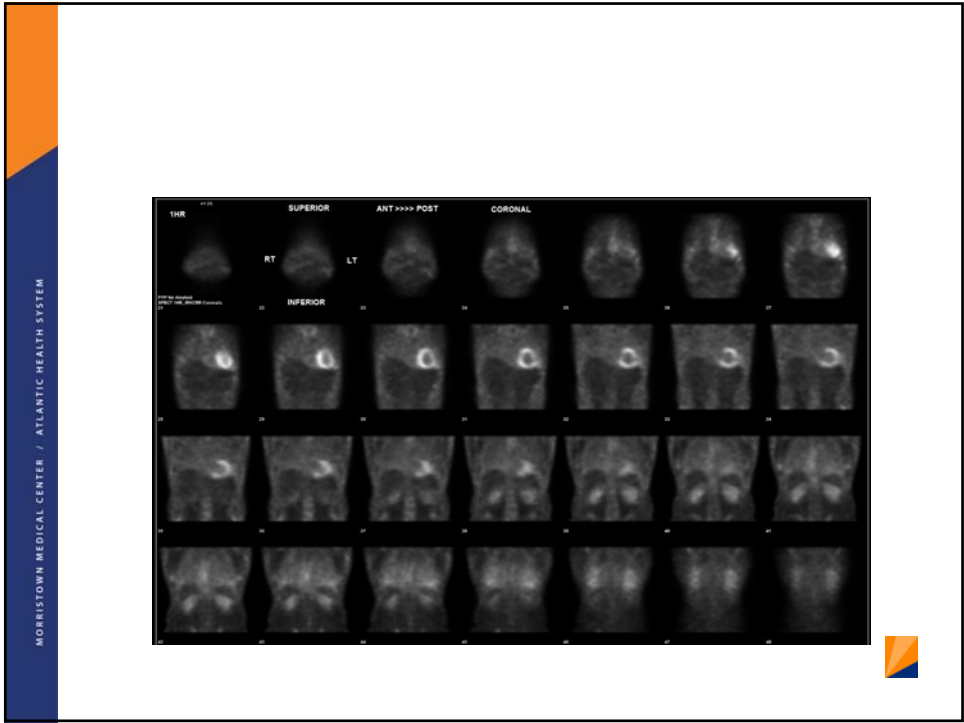


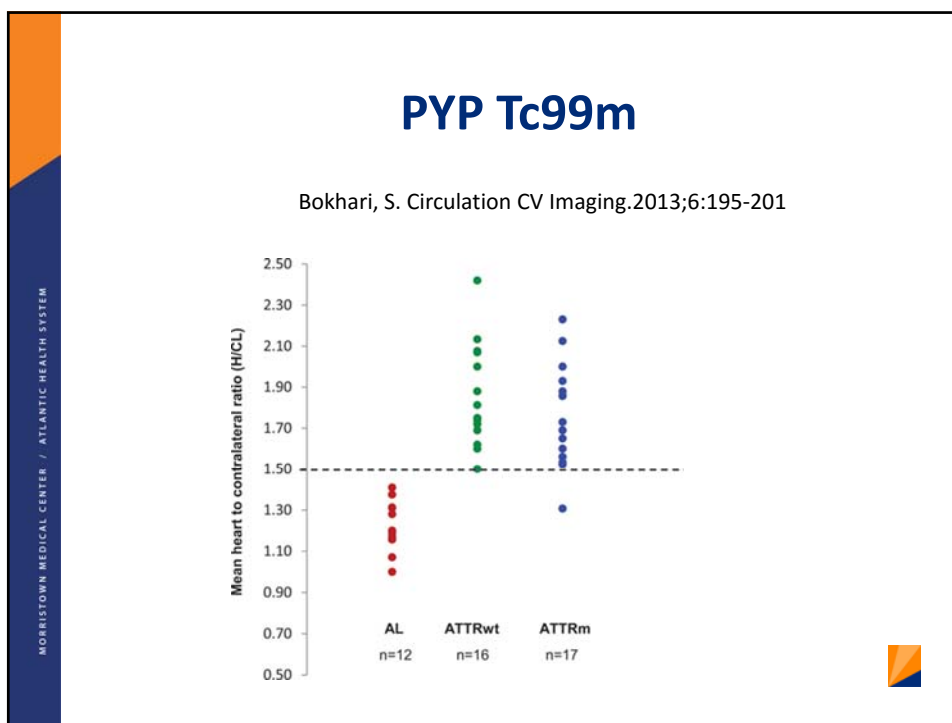
PYP Tc99m



MORRISTOWN MEDICAL CENTER / ATLANTIC HEALTH SYSTEM







Case 2

- 55 y/o male with NIDCM s/p ICD with increasing SOB despite optimal medical therapy.

