

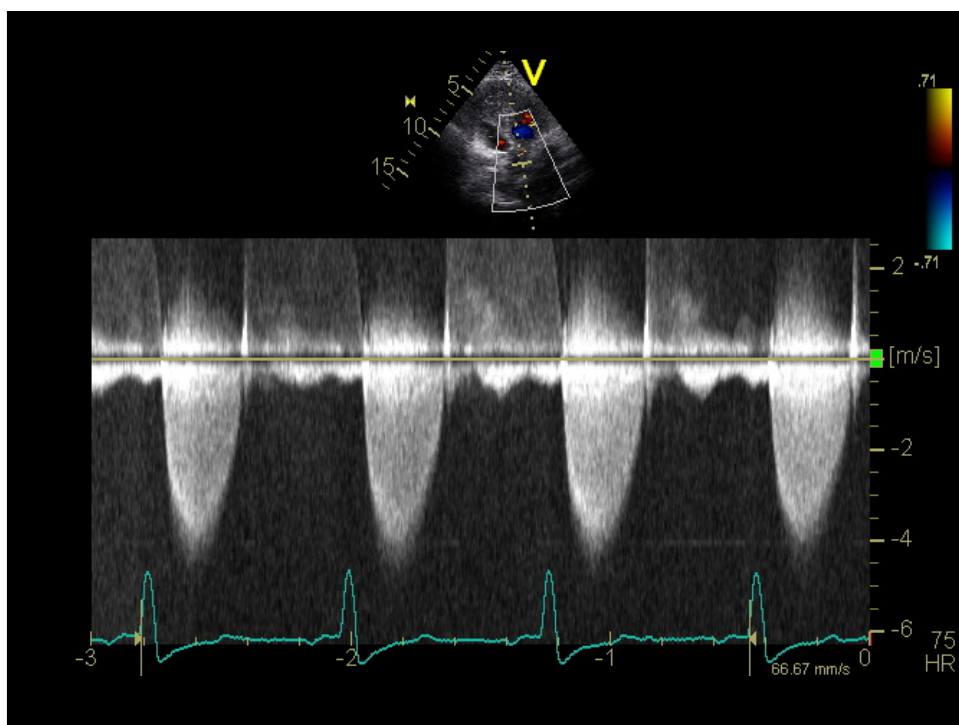
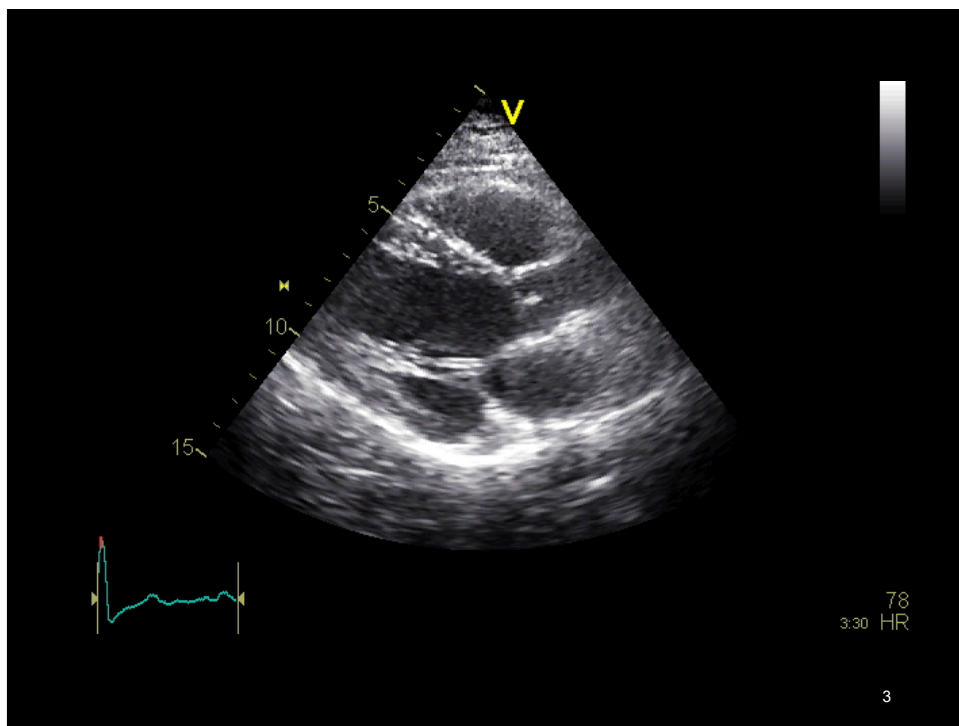
What's the Rush?

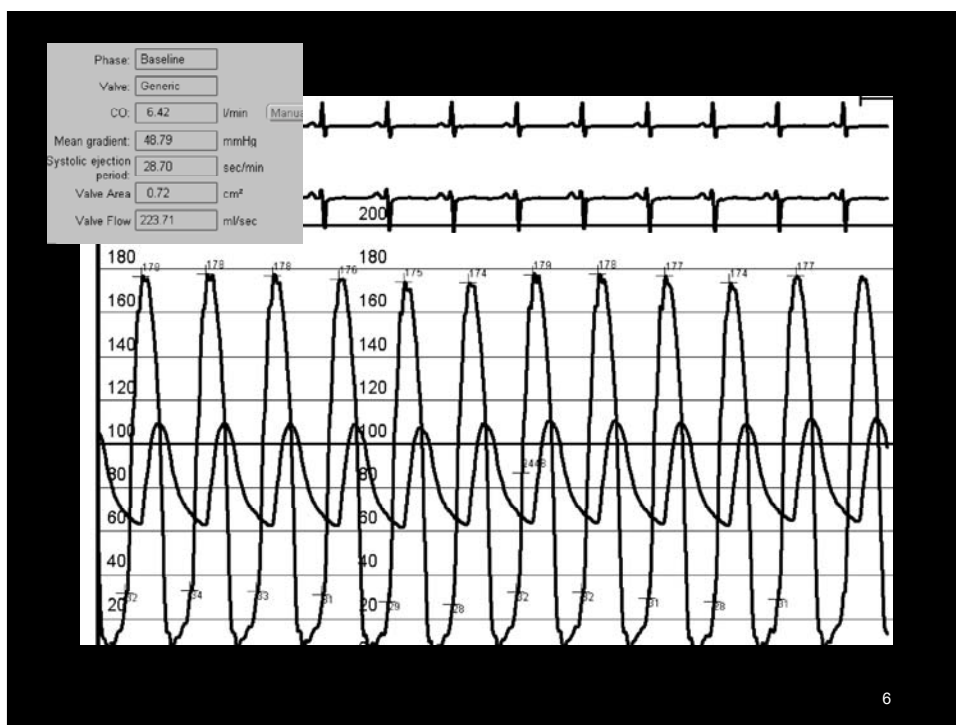
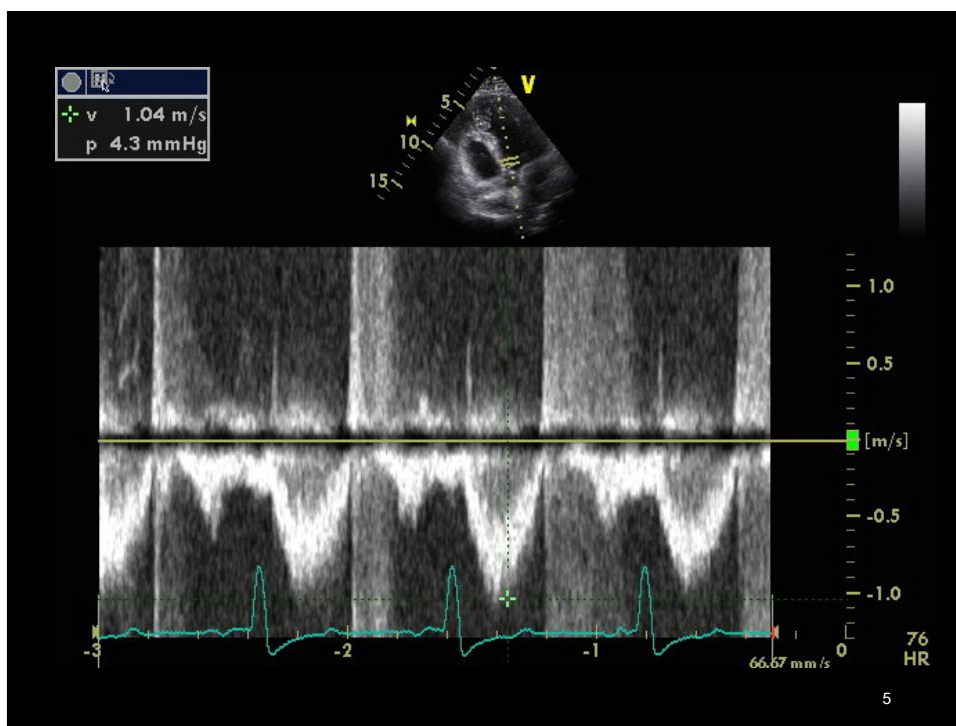
Matthew W Parker, MD, FACC
University of Massachusetts Medical Center

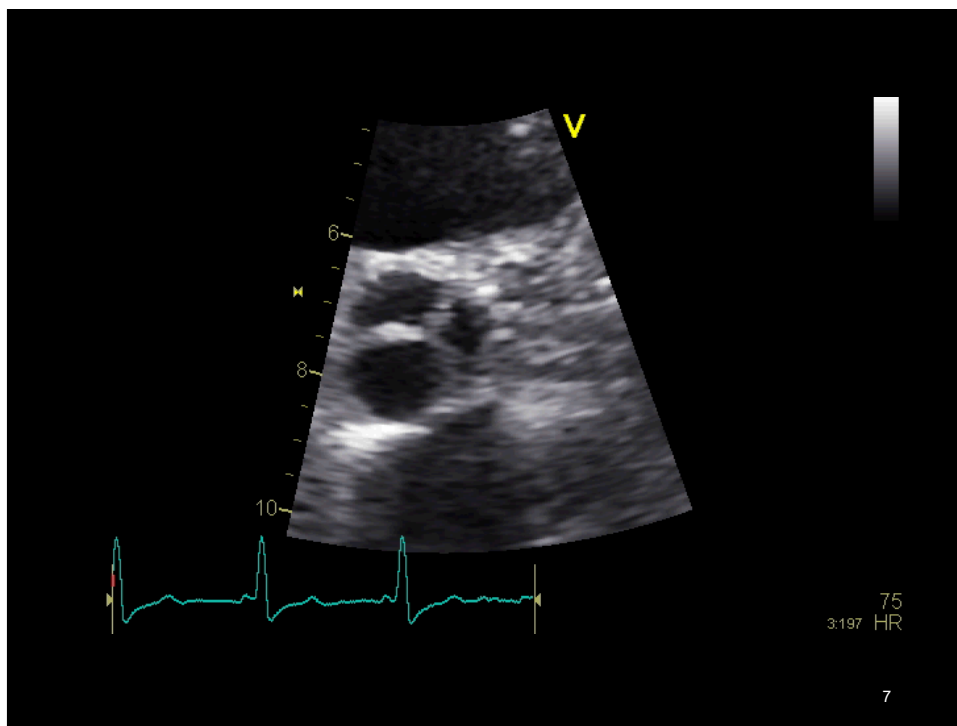
1

70 yo woman with systolic murmur

- Has intermittent atypical chest pain
- Dyspnea with exertion

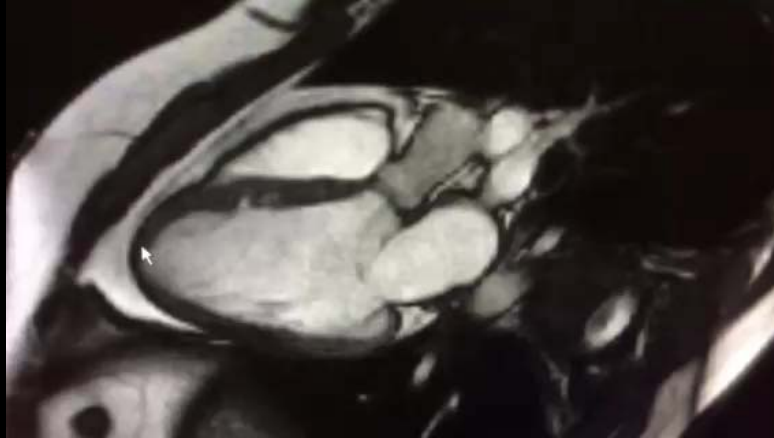





Causes of Area-Gradient Mismatch

- Errors of Measurement
- High Flow
- Pressure recovery
- Eccentric Jet
- Para-valvular Obstruction



**MRI measures
SOV 23 mm
STJ 20 mm
No supra- or subvalvular membranes**

9

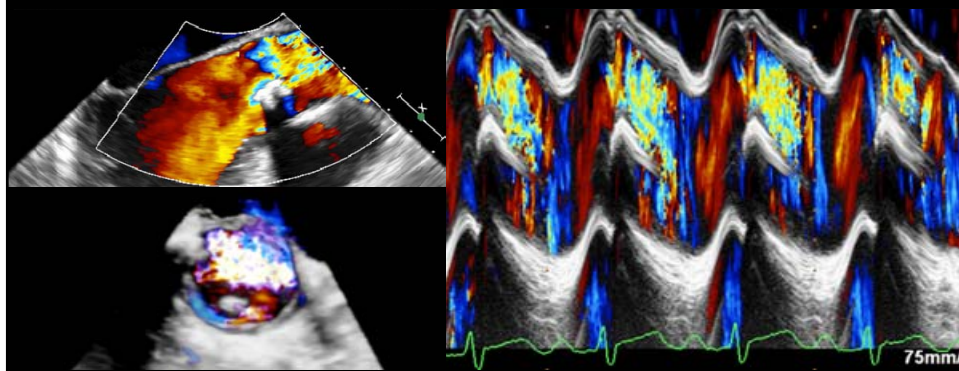
The Role of Jet Eccentricity in Generating Disproportionately Elevated Transaortic Pressure Gradients in Patients with Aortic Stenosis

Amr E. Abbas, M.D., F.A.C.C., F.S.C.A.I., F.S.V.M., F.A.S.E.,* Laura M. Franey, M.D.,* Steven Lester, M.D., F.R.C.P.(C), F.A.S.E.,† Gilbert Raff, M.D., F.A.C.C.,* Michael J. Gallagher, M.D., F.A.C.C.,* George Hanzel, M.D., F.A.C.C., F.S.A.I.,* Robert D. Safian, M.D., F.A.C.C., F.S.C.A.I., F.S.V.M.,* and Philippe Pibarot, D.V.M., Ph.D., F.A.C.C., F.A.H.A., F.A.S.E., F.E.S.C.‡

*Department of Cardiovascular Medicine, Beaumont Health Systems, Royal Oak, Michigan; †Department of Internal Medicine, Division of Cardiovascular Diseases, Mayo Clinic, Scottsdale, Arizona; and ‡Department of Medicine, Laval University & Québec Heart and Lung Institute, Québec, Canada

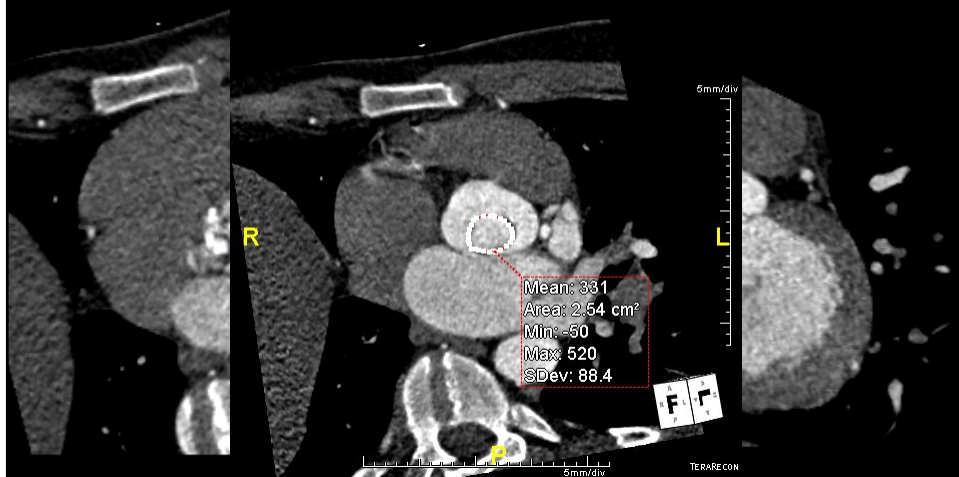
10

Eccentric Jet: Echo



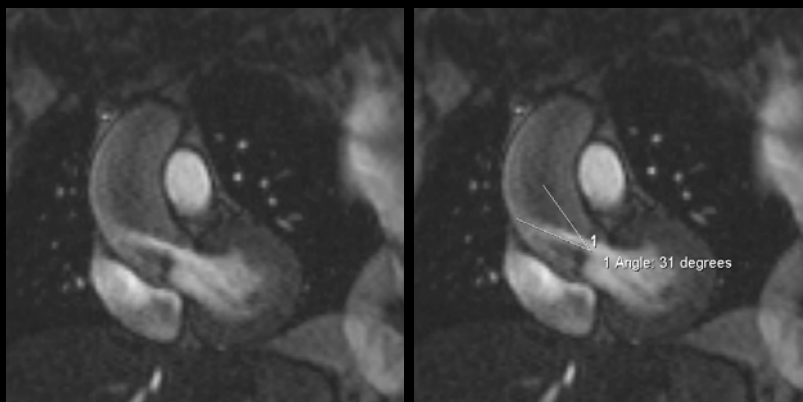
Courtesy Amr Abbas

Eccentric Jet

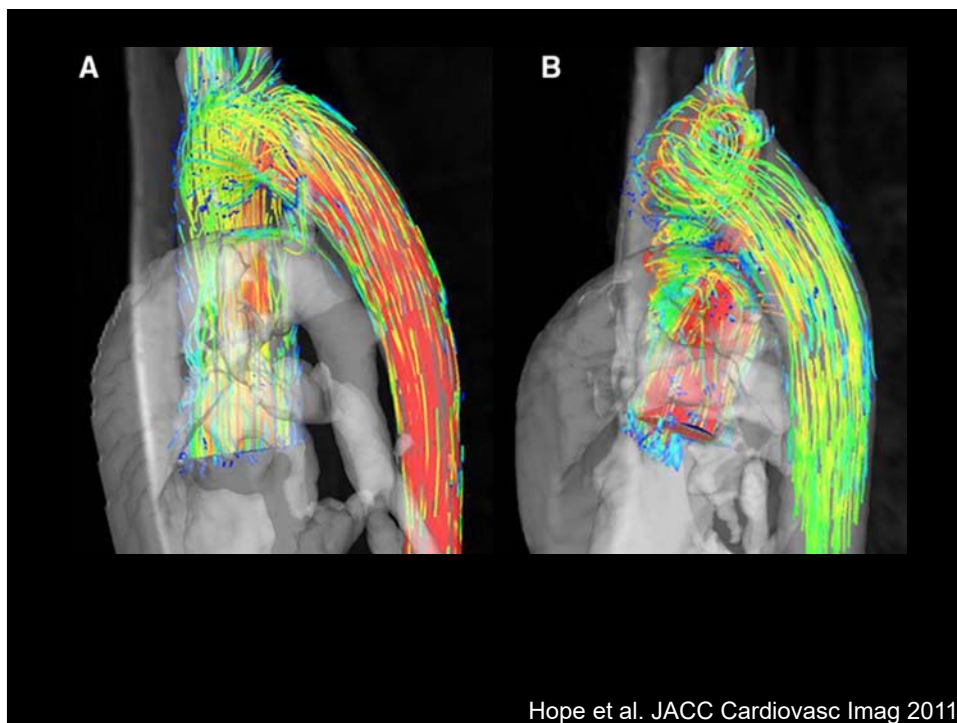


Courtesy Amr Abbas

Eccentric Jet: MRI



Courtesy Amr Abbas



Hope et al. JACC Cardiovasc Imag 2011

**YOU KEEP TAILGATING
I'LL KEEP SLOWING DOWN**

15