

Goofs, Coups and Things I Have Learned

Linda D. Gillam, MD, MPH, FACC, FASE
Chair, Department of Cardiovascular Medicine
Morristown Medical Center/Atlantic Health System

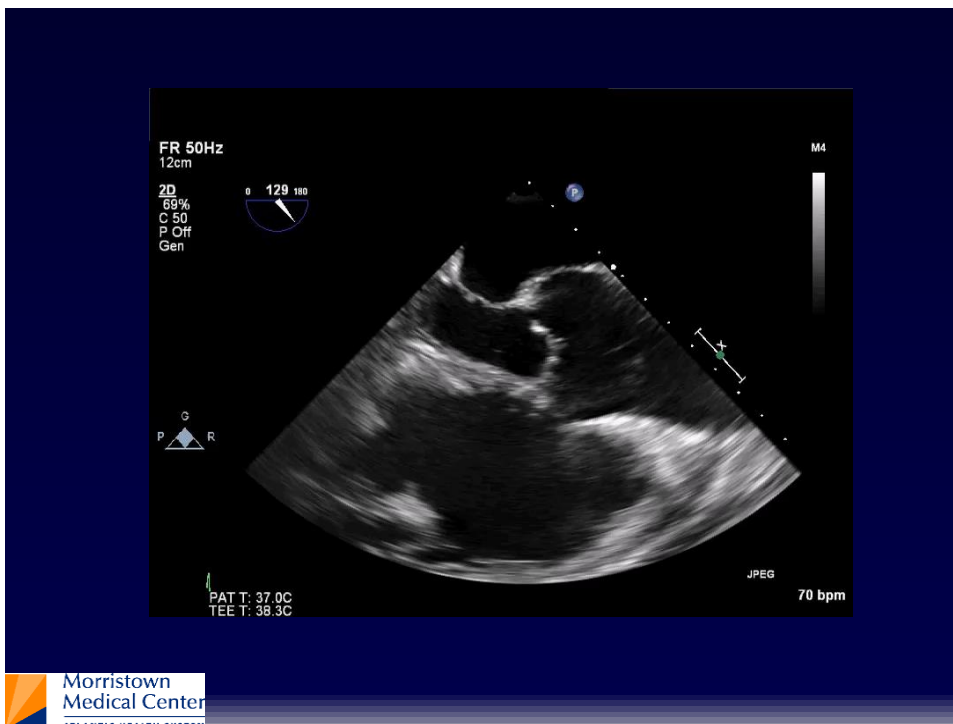


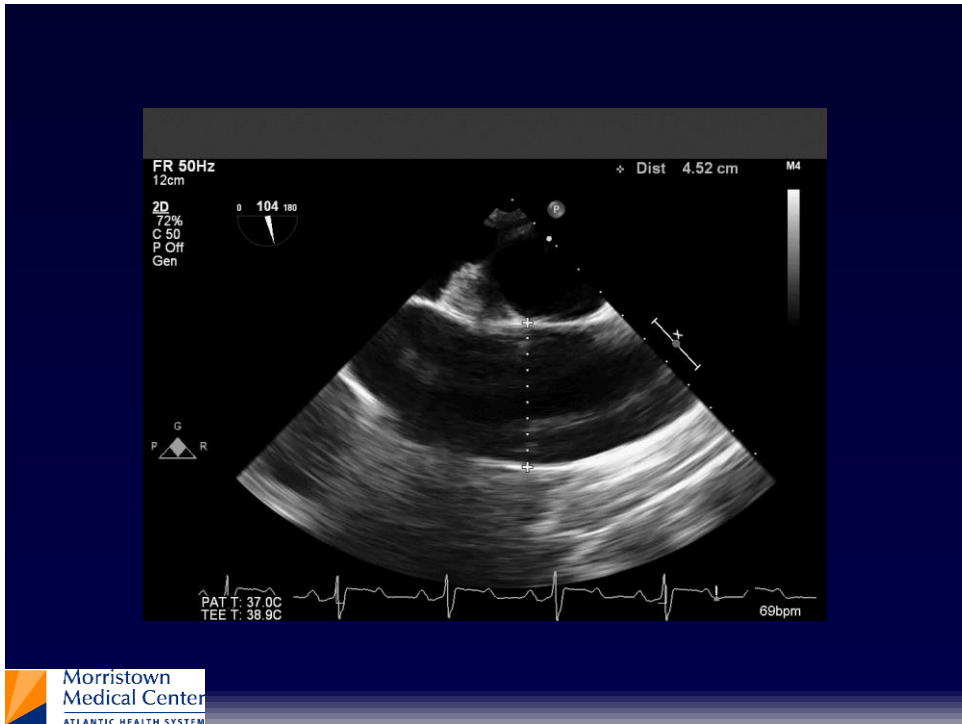
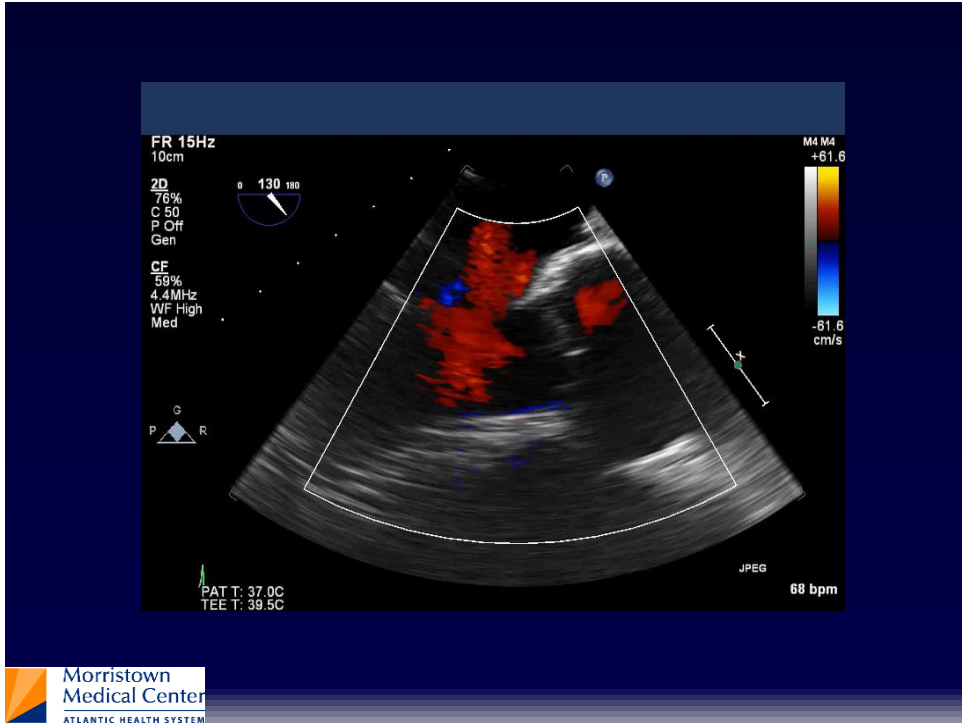
No disclosures

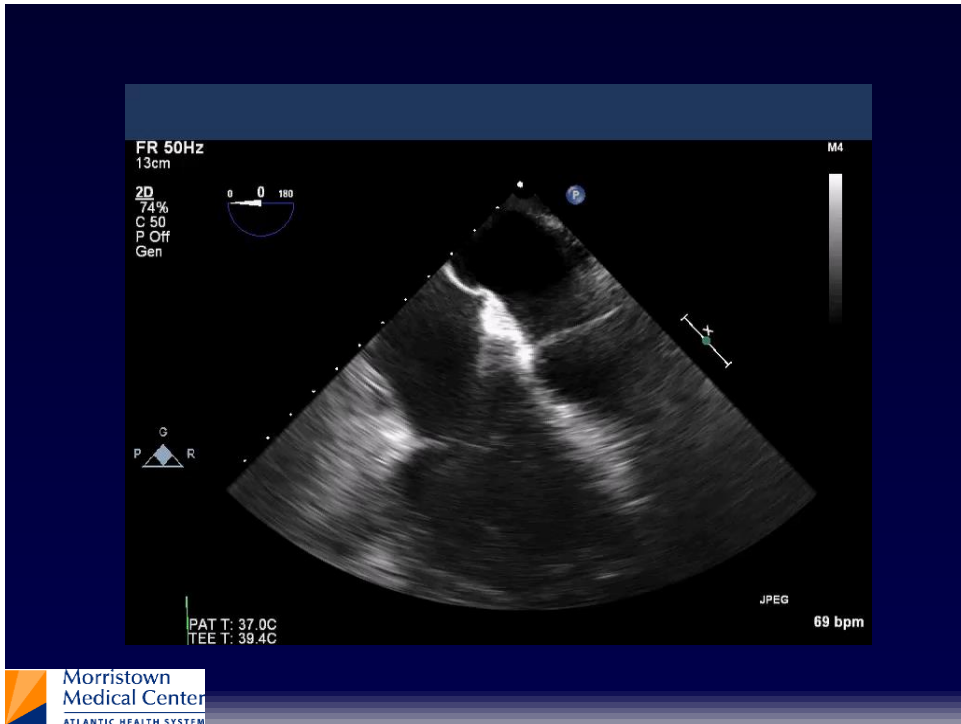
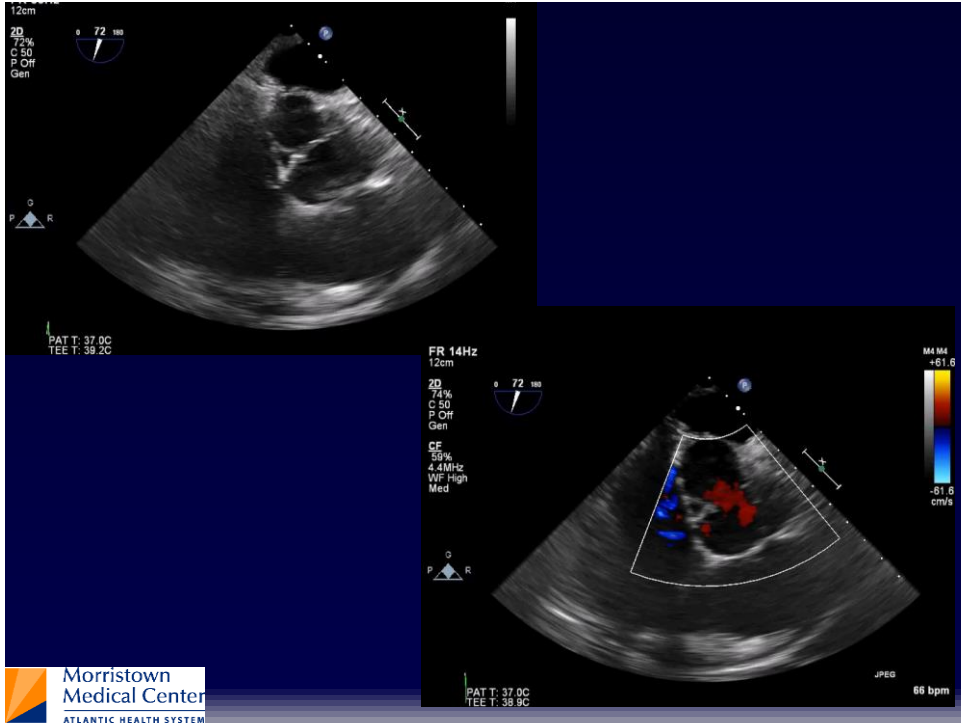


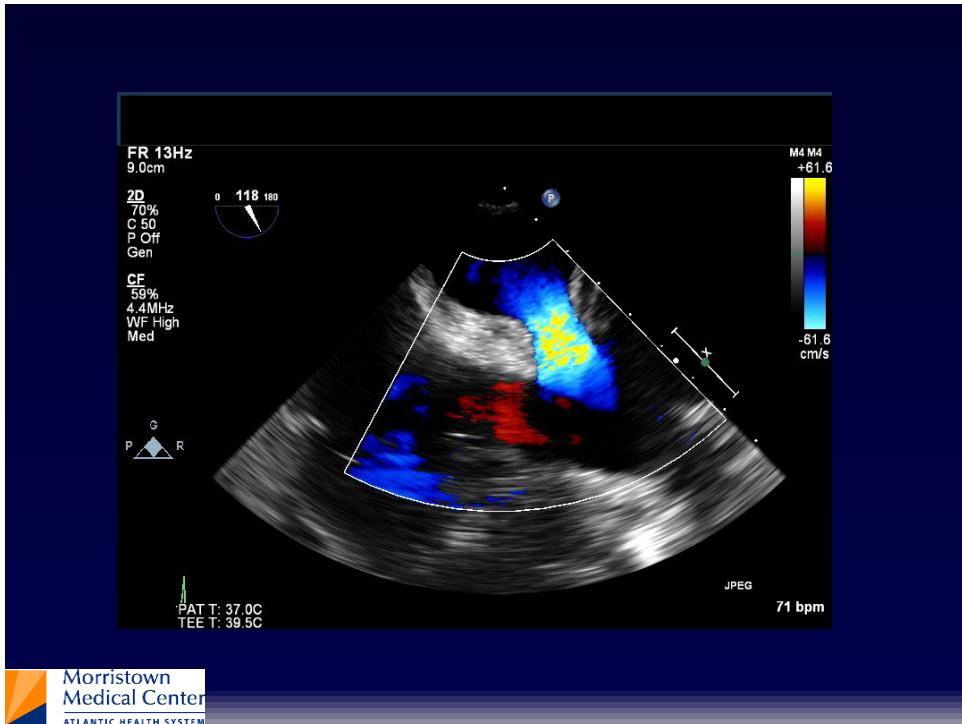
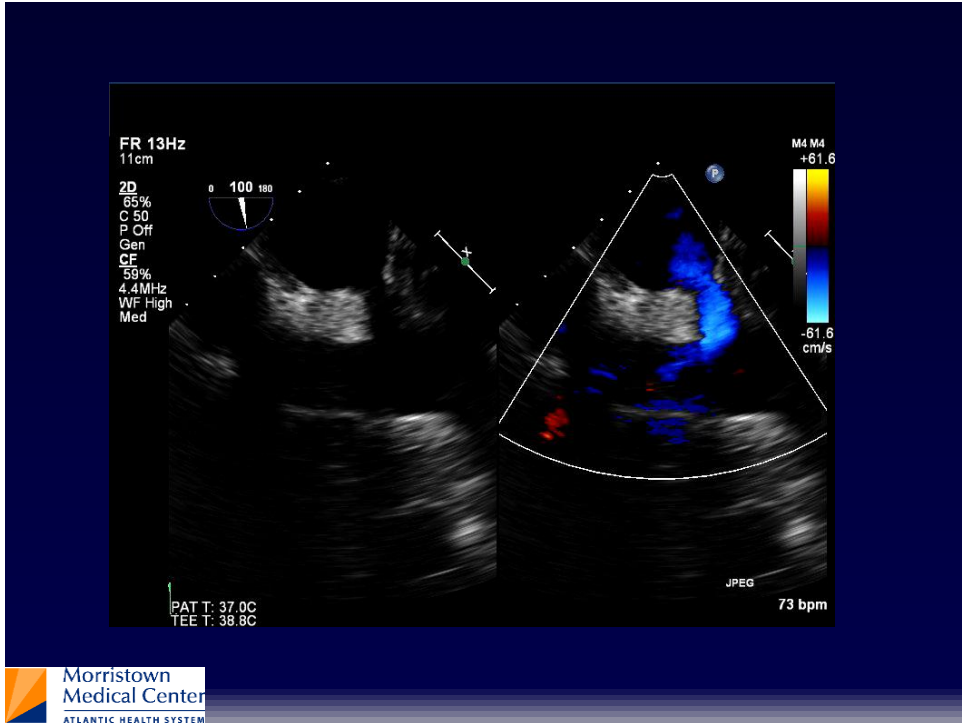
Case

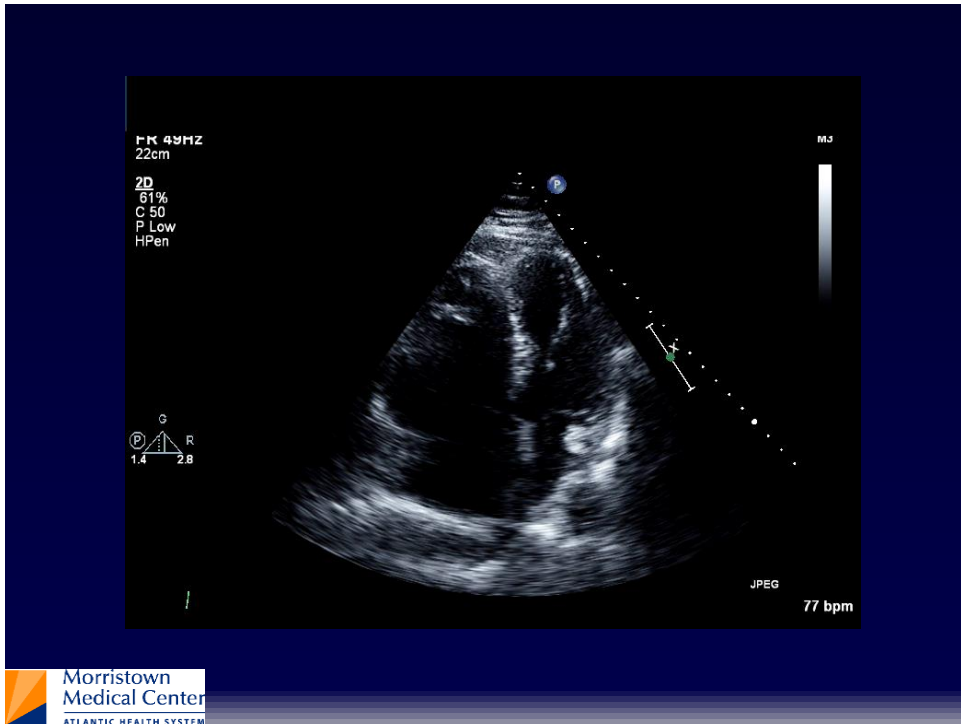
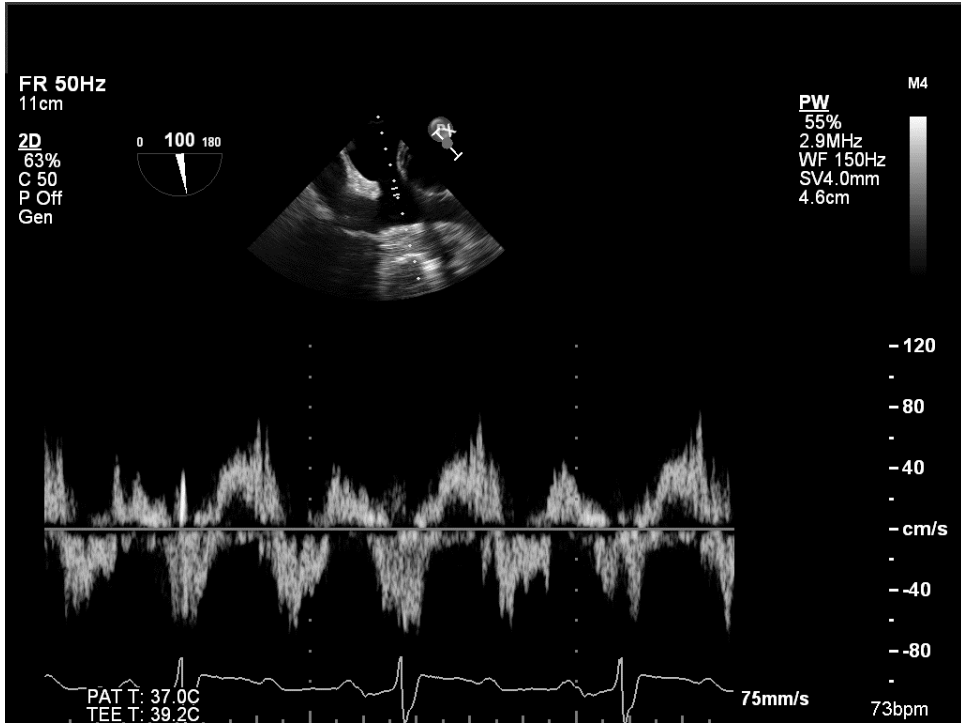
- 52 yo female sent from outside hospital for surgery for ascending aortic aneurysm (known bicuspid valve)
- TEE ordered by surgeon to confirm aortic valve function/structure

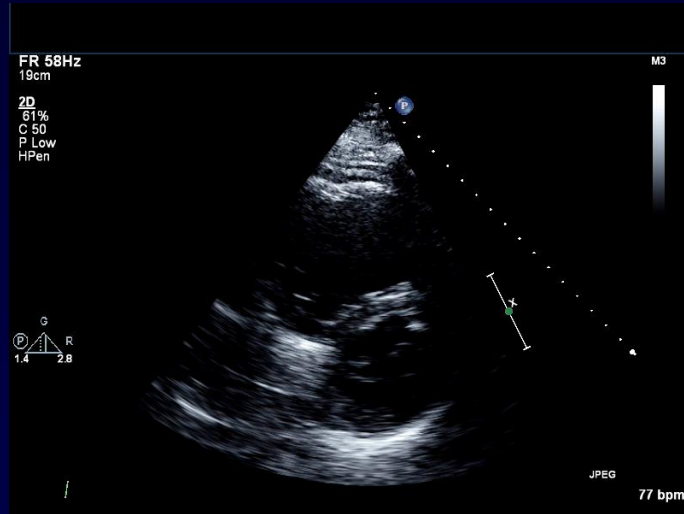




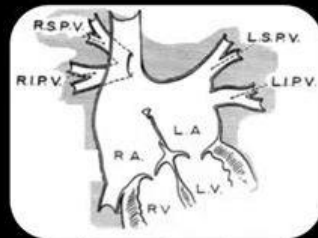




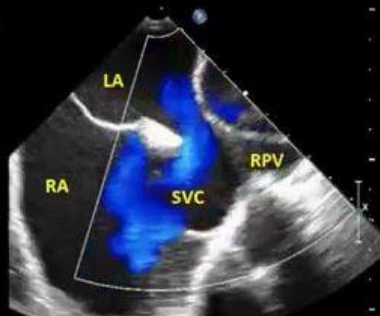


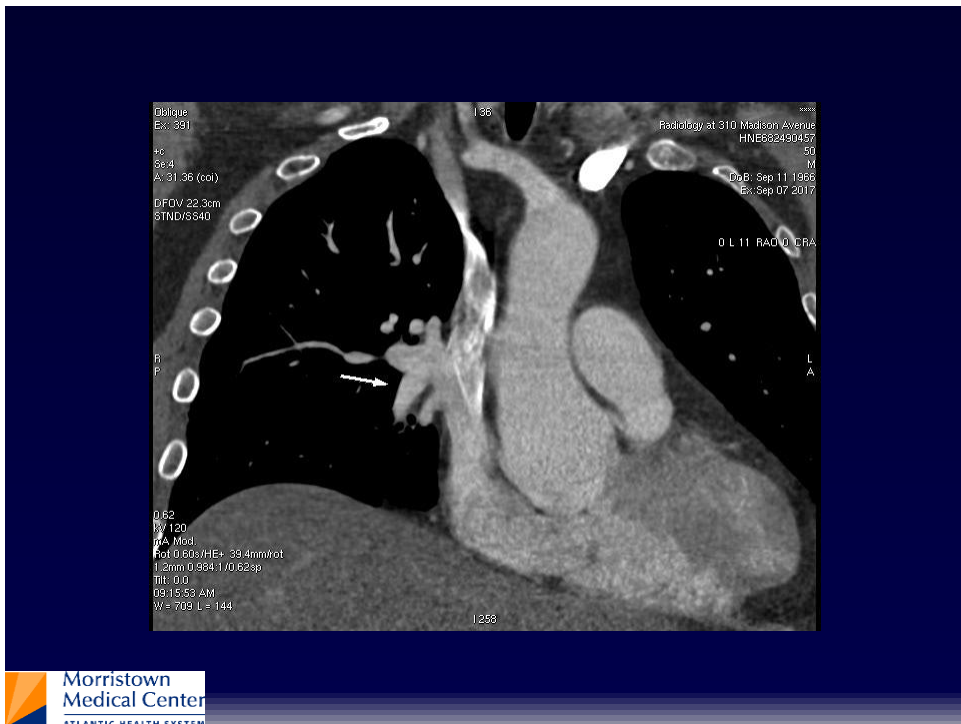
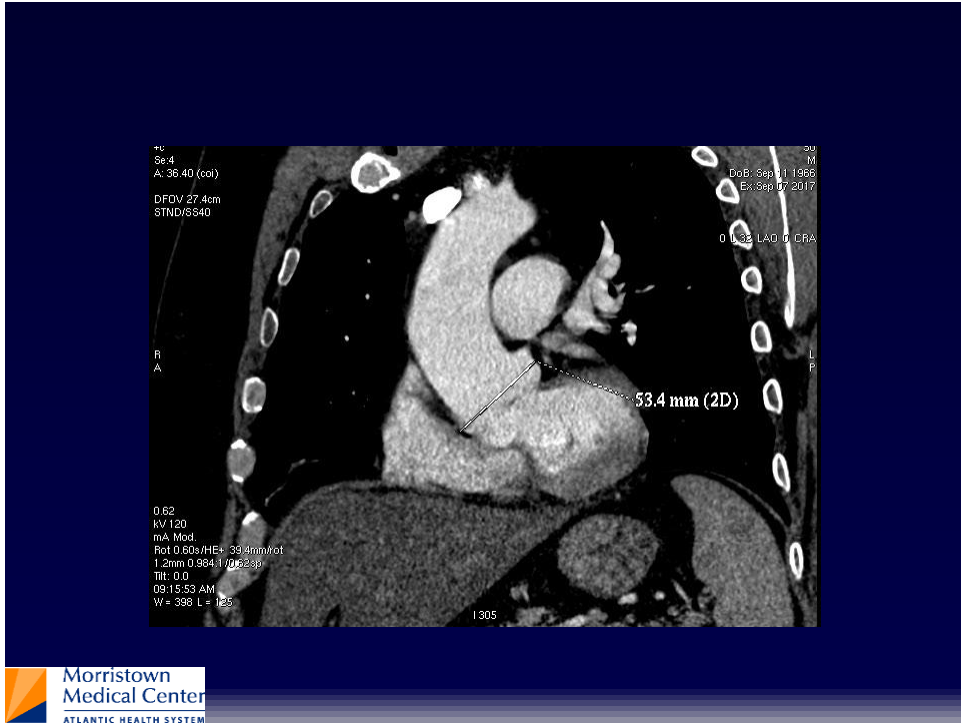


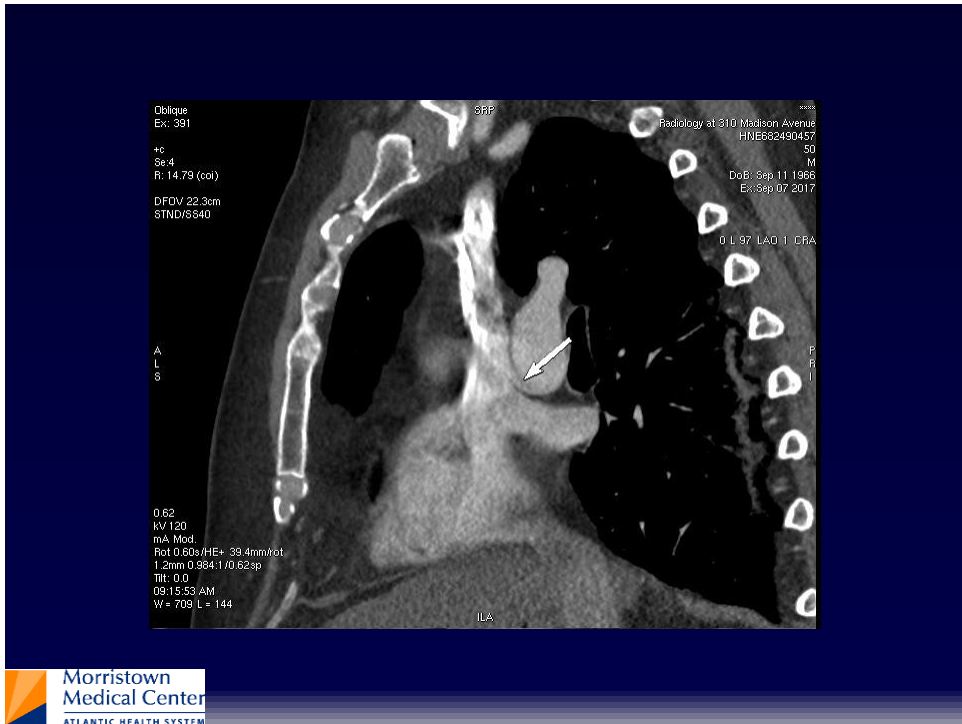
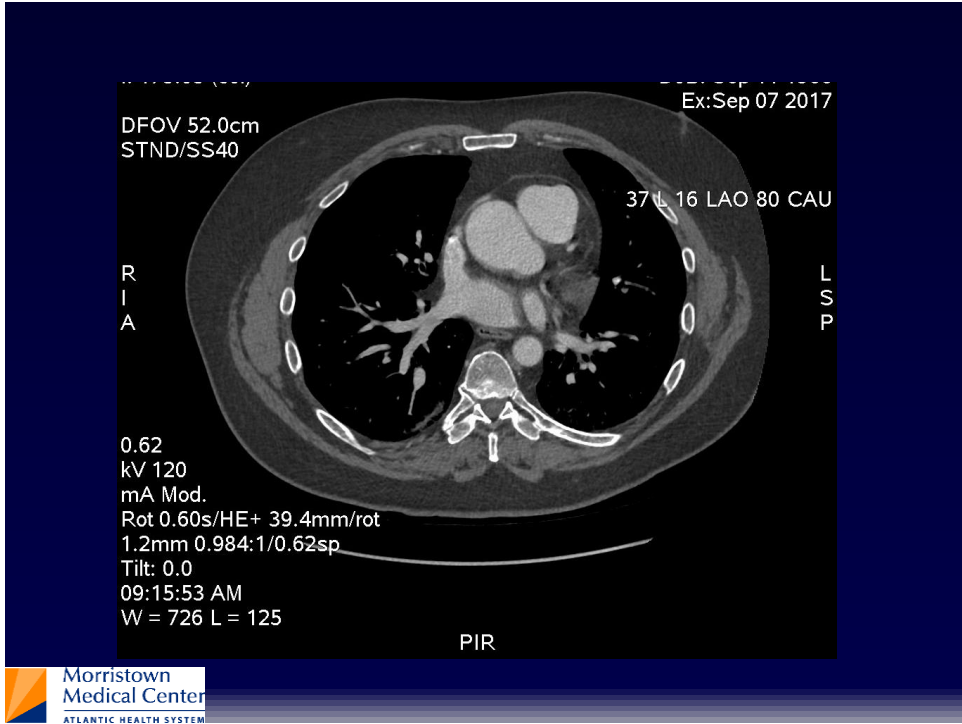
Partial anomalous pulmonary venous connection (PAPVC)



- Partial anomalous pulmonary venous connection (PAPVC) of right side pulmonary veins (RPV)







Summary

- Suspect the unsuspected
- Do complete studies

