10/8/2017
11:50 AM-12:10 PM

GOOFS, COUPS, AND THINGS I HAVE LEARNED IN THE PAST YEAR: PART I

Rebecca T. Hahn, MD, FACC, FASE
Director of Interventional Echo
Professor of Medicine
Columbia University

Disclosures

- Core Lab Director for multiple tricuspid device trials for which I receive no direct compensation:
  - SCOUT Trial
  - Triluminate Trial
  - Tri-Repair Trial
- Speaker: Abbott Structural, GE, Philips, Boston Scientific
- Consultant: Gore&Associates, NaviGATE, Abbott Structural, GE, Philips

Case 1

An 80-year-old Russian speaking female with a past medical history of

- Severe mitral stenosis status-post valvuloplasty in Moscow in 1963
- Atrial fibrillation on Coumadin
- Hypertension
- Chronic kidney disease

- Complained of increased dyspnea on exertion and fatigue that started six months prior and had progressively worsened.

Pre-procedural transthoracic echocardiogram

Pre-procedural transthoracic echocardiogram showed:

- Rheumatic mitral valve with stenosis and a mitral valvuloplasty score of 9 (Mobility = 2, Leaflet thickness = 2, Subvalvular thickening = 4 and Calcification = 2)
  - Mean gradient 5 mmHg
- Heavily calcified aortic valve. Severe aortic stenosis
  - Peak/mean gradients of 96.4/43.8mmHg
- Ejection fraction 65-70%

- Given the findings on transthoracic echocardiogram the plan was to perform a transcatheter aortic valve implantation (TAVI).

Intra-procedural TEE: Mitral Valve

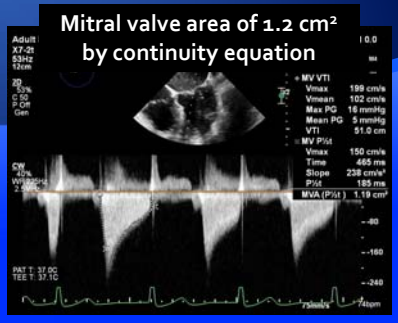

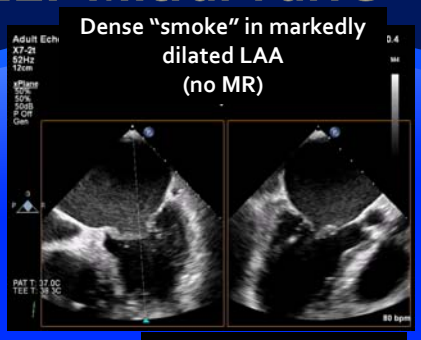

Intra-procedural TEE showed:

- Severe mitral stenosis by multiple methods
- Dense "smoke" in the LAA consistent with very slow flow but no thrombus
- No mitral regurgitation

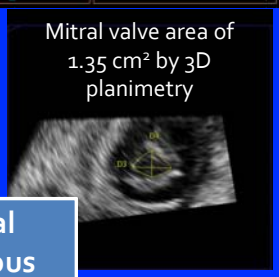

In light of TEE findings, an intra-procedural decision was made to perform a percutaneous balloon mitral valvuloplasty (PBMV) prior to TAVR

PBMV

Valvuloplasty

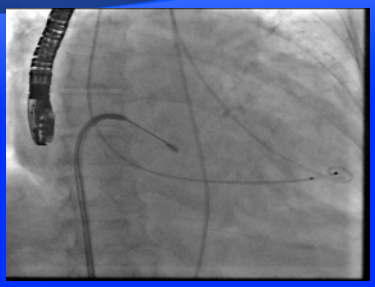

Valvuloplasty

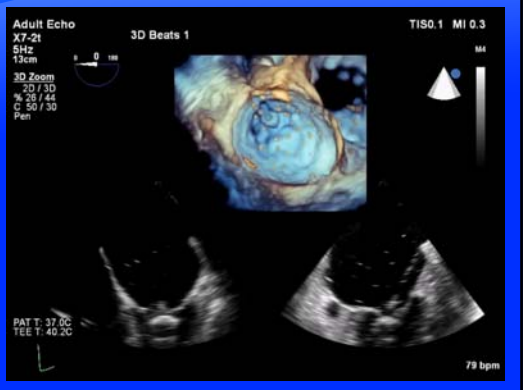

Percutaneous balloon mitral valvuloplasty was performed using a 23mm Inoue balloon. Two inflations were performed resulting in lateral commissural fracture and improved valve opening

PBMV

Pre-PBMV

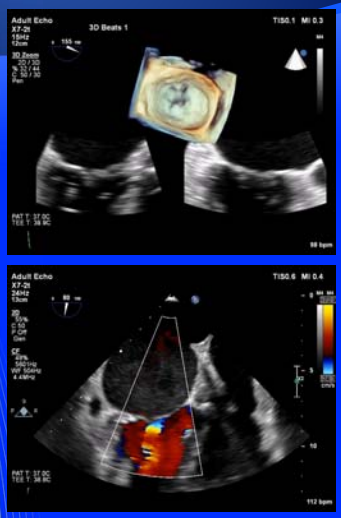

Post-PBMV



Planimetered MVOA= 1.7 cm²

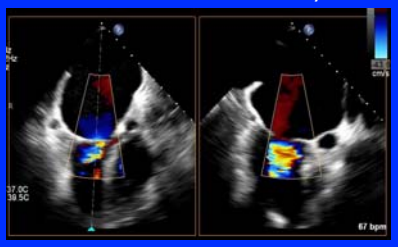

- Single jet of mild mitral regurgitation was seen (EROA by 3D = 13mm²)
- Smoke resolved

Hemodynamics

Pre-PBMV

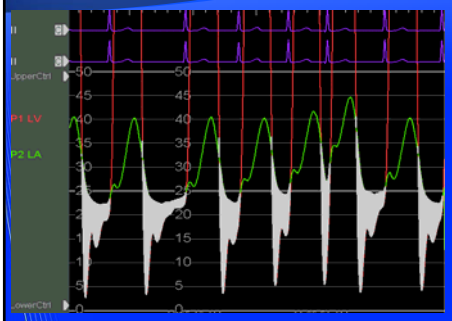

MG 9.1 mmHg

Post-PBMV

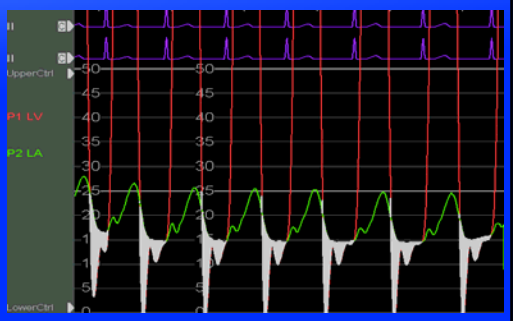

MG 4.9 mmHg

3D TEE Assessment of Aortic Valve and Left Coronary Artery

- Annular perimeter = 67 mm
- Annulus-to-left main distance of 10.7mm and a left coronary cusp (LCC) length of 14.5 mm with a sinus of Valsalva (SOV) diameter of 2.85 cm.

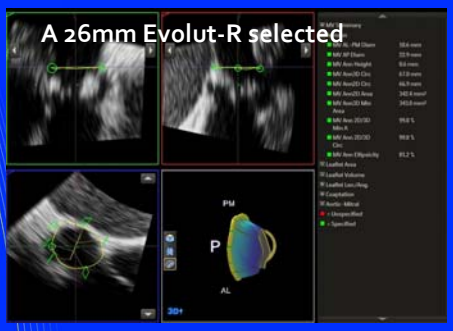

Diagnostic BAV to assess LM ostium

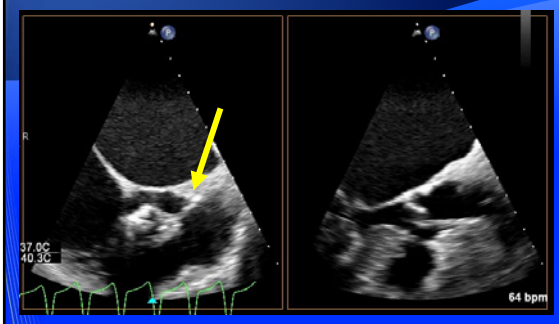

During BAV the left main coronary ostium was covered by the left coronary cusp (yellow arrow) on TEE with slow/faint filling was seen on contrast injection (red arrow).

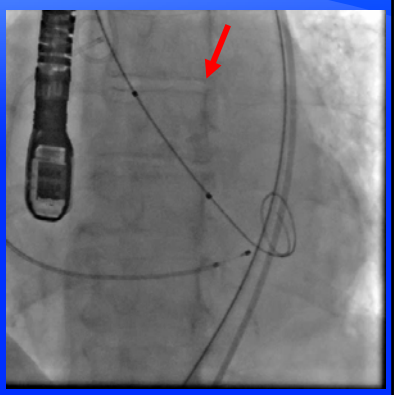

20mm Z-Med II balloon

Protection of LM ostium

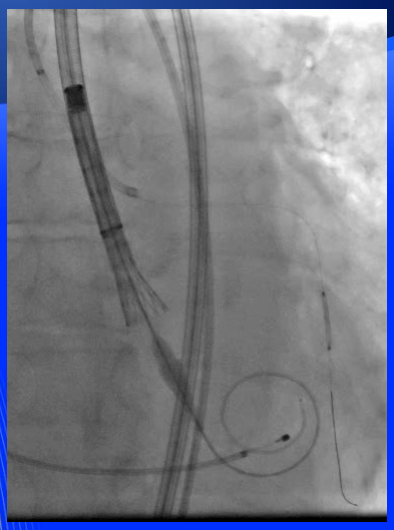

- 6F JL 3.5
- 6F Guideliner
- 3.5 x 15mm DES placed in mLAD

Valve Deployment

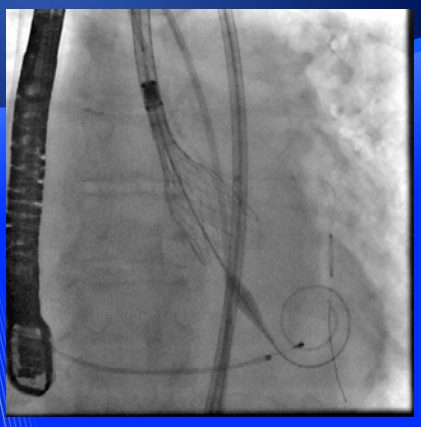

Evolut-R 26mm

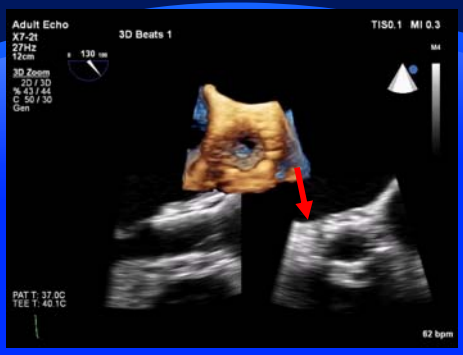

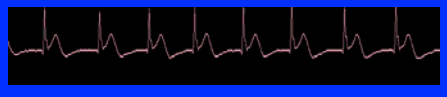

ST elevations noted on monitor

Valve Deployment

Evolut-R 26mm

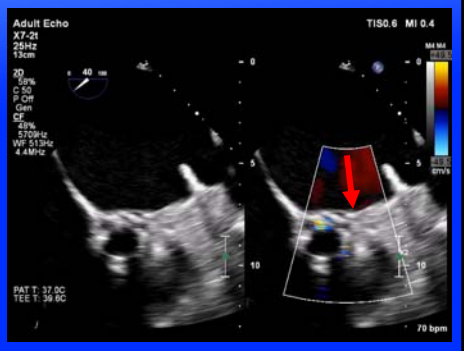

Marked reduced flow in LM ostium

Urgent stent deployment in LM

Deployed at 12 atm

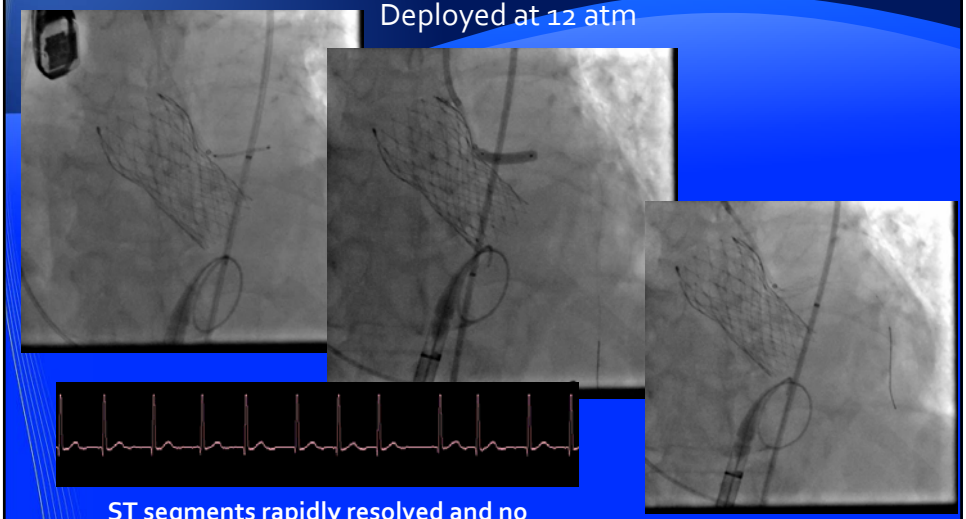

ST segments rapidly resolved and no wall motion abnormalities were detected

Left Main Stent

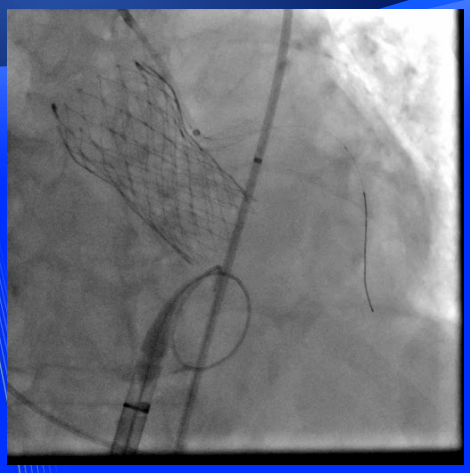

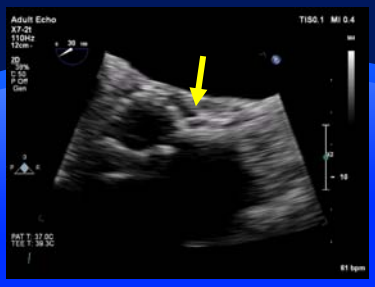

Final AR Assessment

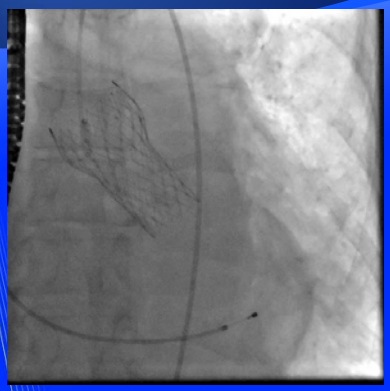

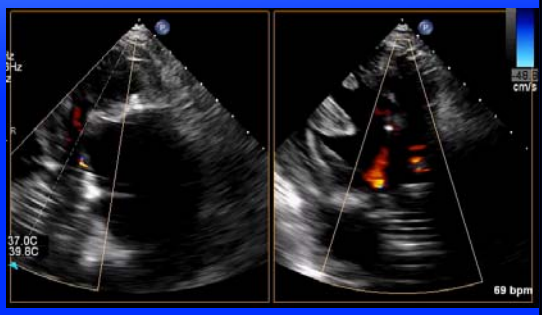

2+ AR

No Post-dilatation was performed

Case 2: History

- 67 year old woman
- BSA: 1.57 m^2
- NYHA Class III
- Comorbidities:
  - Degenerative Mitral Regurgitation (years)
  - HFpEF (50%)
  - Chronic Atrial Fibrillation (on warfarin)
  - Hypertension
  - Restrictive lung disease due to severe kyphoscoliosis
  - Iron-deficiency anemia
- Multiple recent hospitalizations in 4/2016 for pneumonias
  - Admitted to outside hospital with Serratia pneumonia s/p course of meropenem and ertapenem
  - Transferred for treatment of severe MR

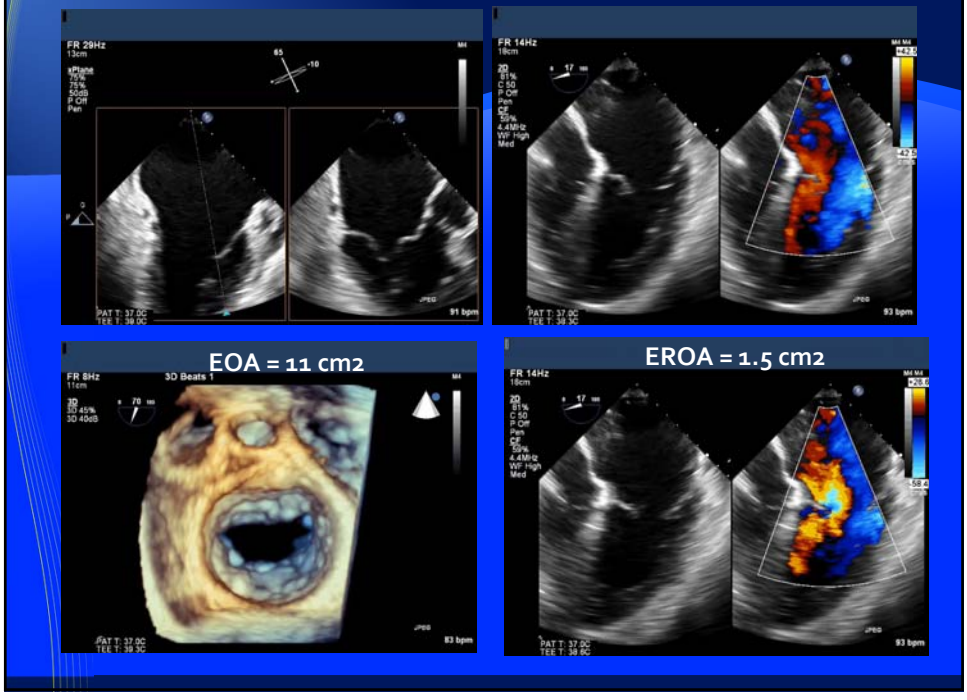

Large Regurgitant Jet

Prominent Prolapse with Partial Flail (lateral portion of P2)

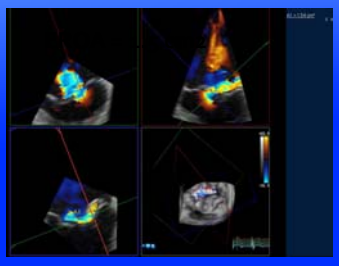

EOA = 11 cm2

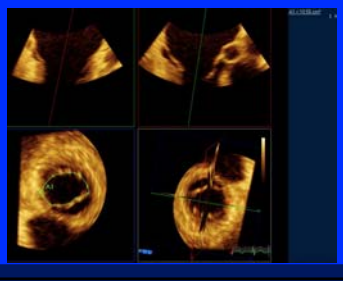

Optimizing the Transseptal Puncture

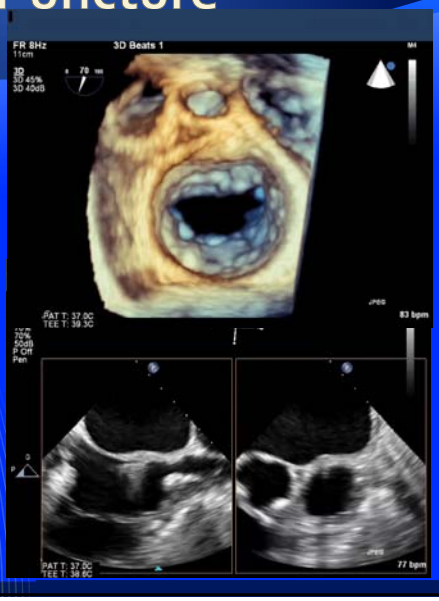

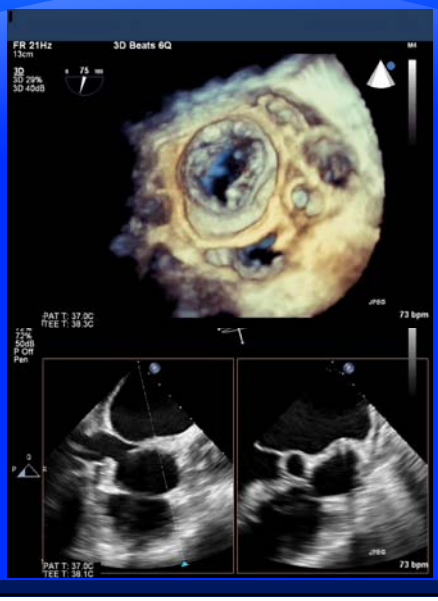

Rotated Heart!!

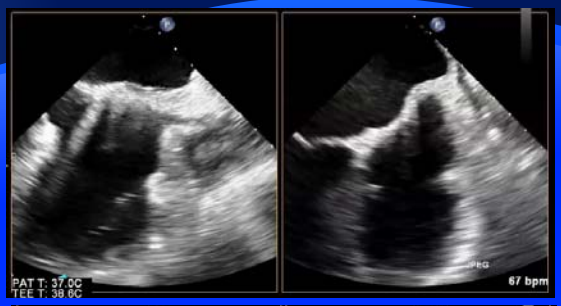

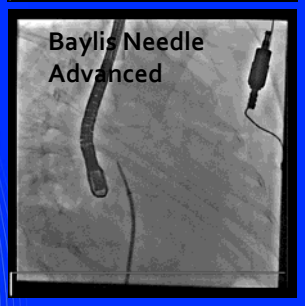

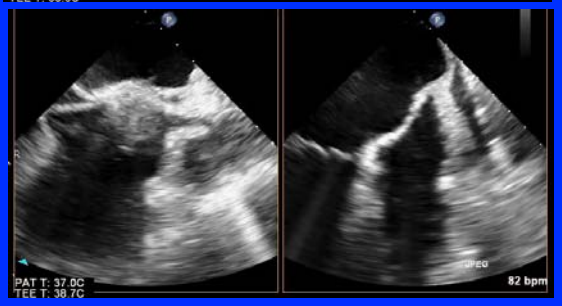

How is the location of the Trans-septal Puncture?

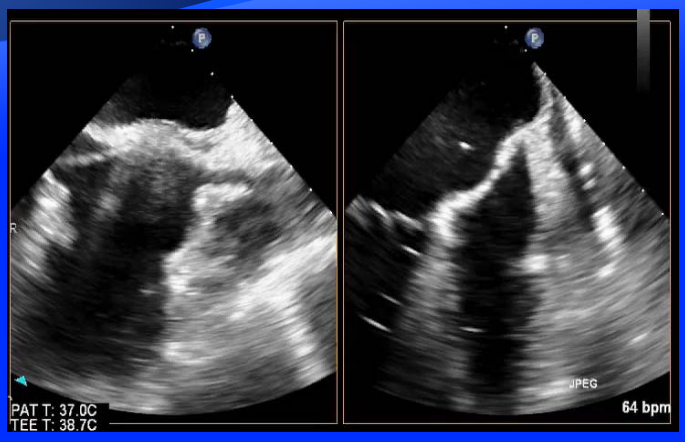

An Earlier Case: Complications of Trans-septal

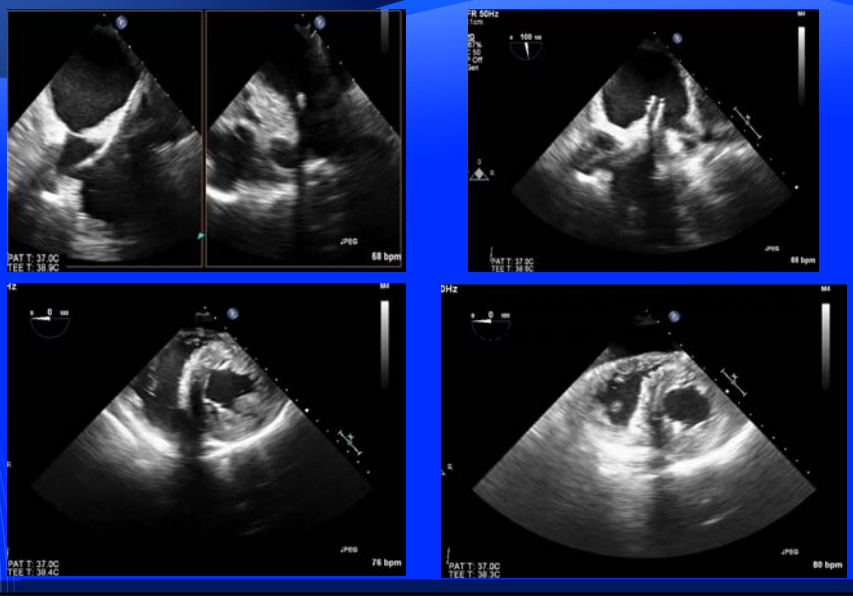

An Earlier Case: Perforation

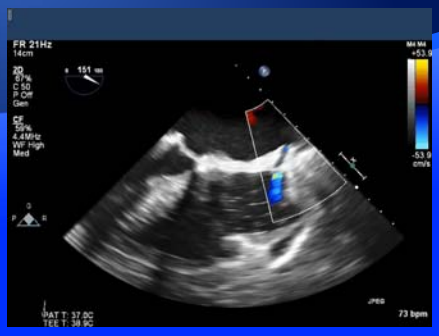

- Auto-transfused 500 cc
- Required 2 U PRBC, 2U FFP, platelets
- Eventual stabilization, removal of drain after 3 days
- Discharge POD 5

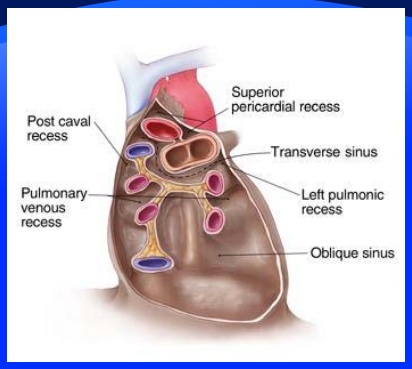

The reflections that surround the venae cavae and pulmonary veins create a dead ended pocket behind the left atrium termed the *oblique sinus*.

How is the location of the Trans-septal Puncture?

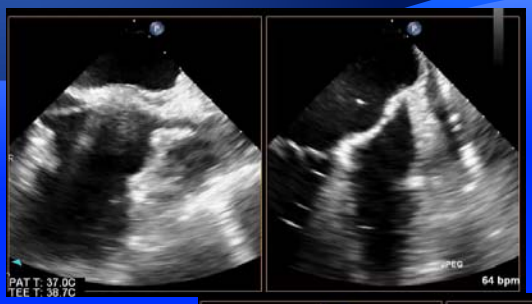

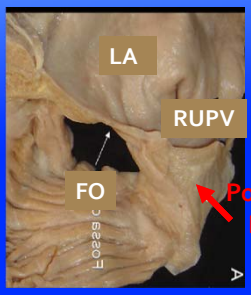

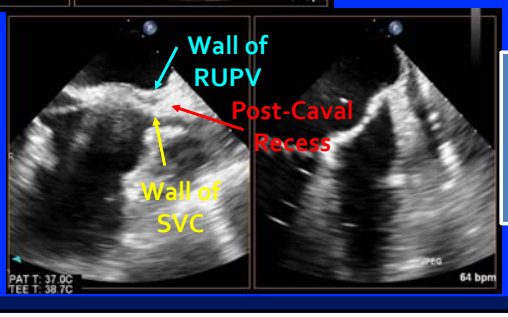

Imager asked for repositioning of the trans-septal puncture

Redo Trans-septal Puncture

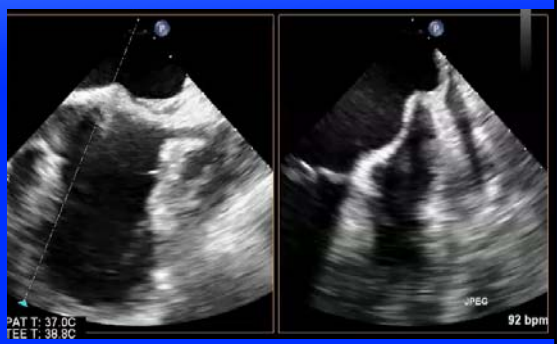

Redo Trans-septal Puncture

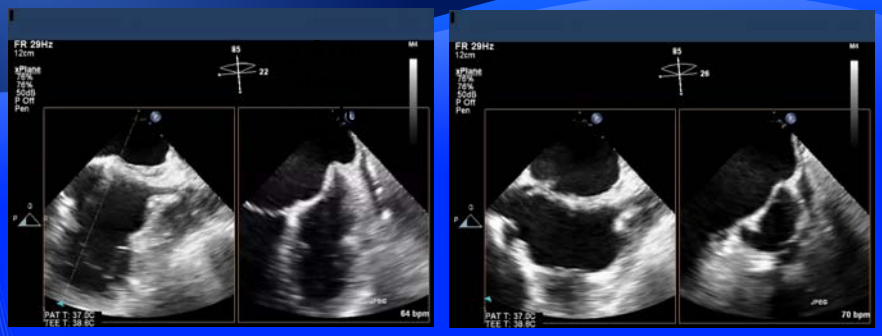

Locate the position and direction of transseptal catheter puncture

- 3.5-4 cm above the annular plane
- Mid-posterior fossa
- Posterior and superior direction of the catheter

Orienting Clip Arms over MR

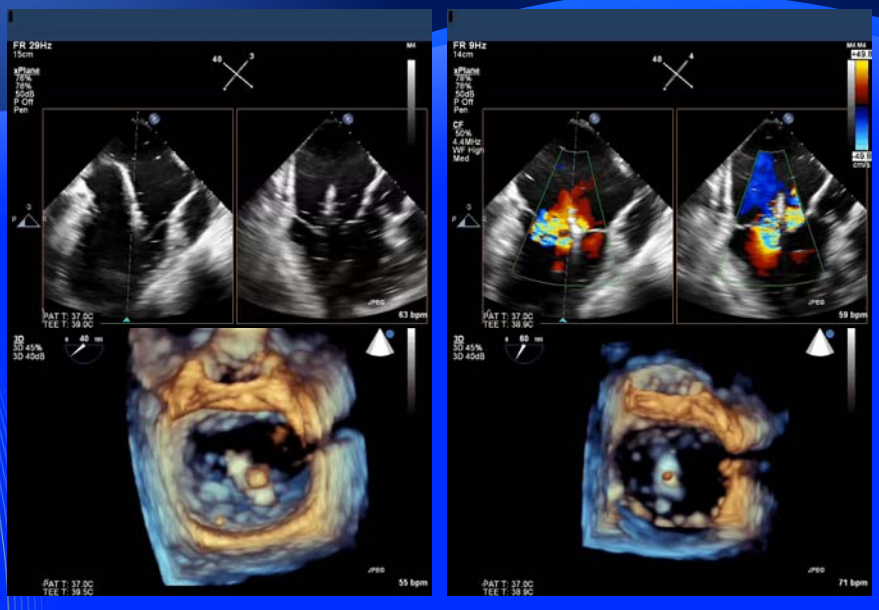

Ensuring Capture of First Clip Positioning Second Clip

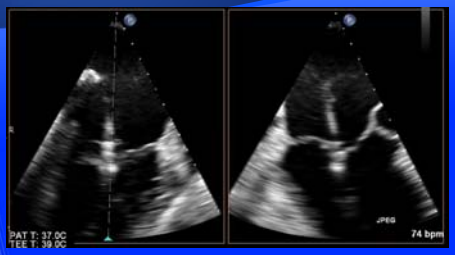

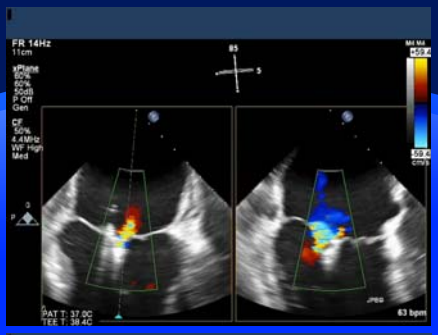

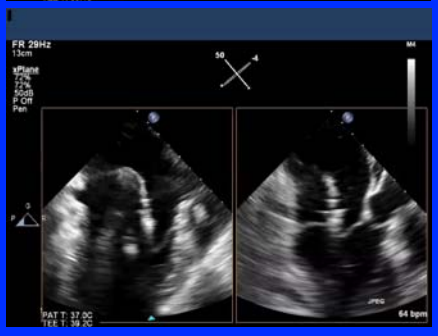

- **Prior to clip release**
  - Peak/mean transmitral gradients were 11 and 3 mmHg respectively
  - Mitral valve orifice areas by planimetry were 3.26 and 1.6 cm2 (total MVA = 4.8 cm2).
  - Residual EROA of lateral jet by 3D = 52 mm2).

Final 2-Clip Results

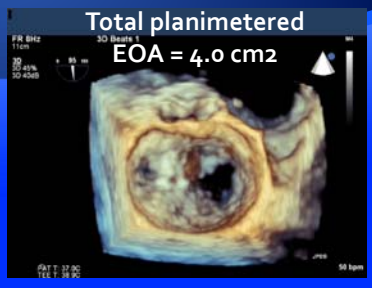

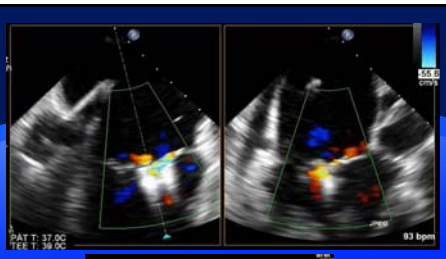

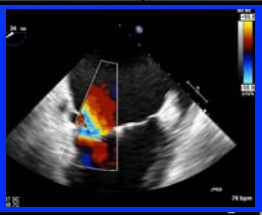

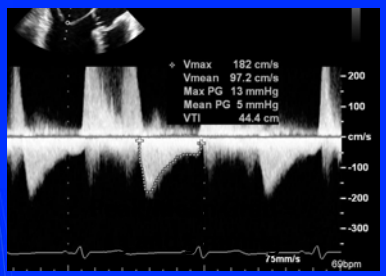

Removing Clip Delivery System

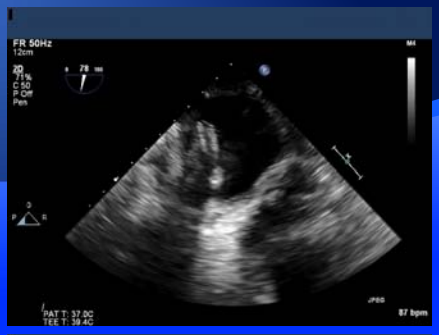

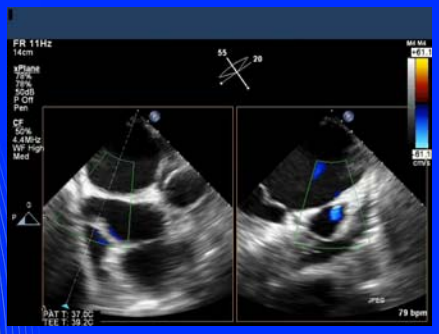

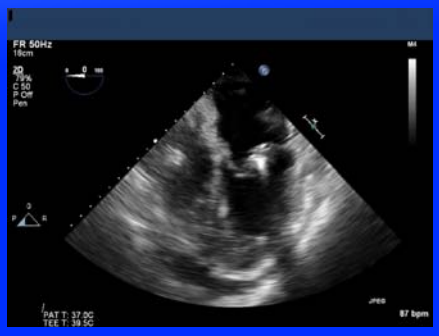

Immediately after Delivery System removed, a pericardial effusion was seen (no hemodynamic compromise seen)

Acute Pericardial Effusion

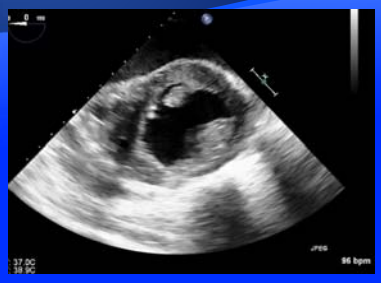

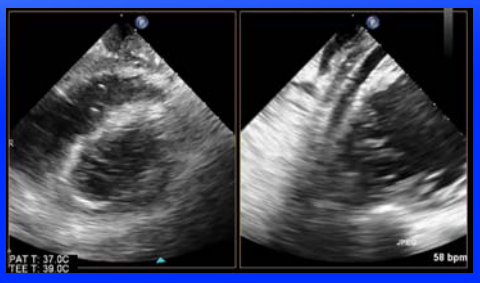

- Emergent pericardiocentesis was performed with auto-transfusion (700cc).

Post-Pericardiocentesis

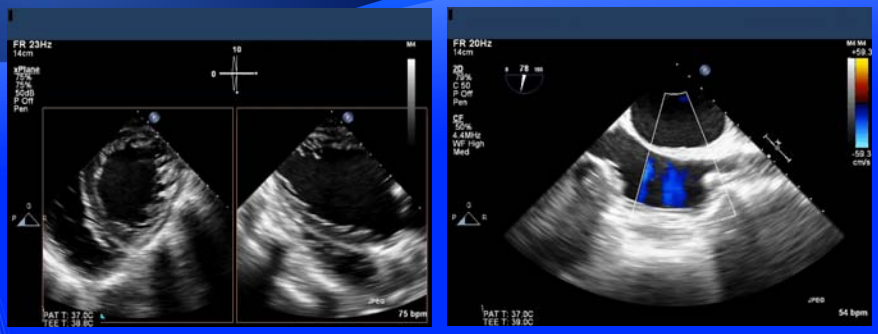

- After protamine was given, the patient become stable HD and required no pressor support or transfusion
- Drain removed and patient extubated the following day and discharged POD 5 (after completing course of Abx for pneumonia)

Case 3: Direct Flow Medical Valve Characteristics

Non-metallic DFM Percutaneous Aortic Heart Valve

Tri-leaflet valve constructed of bovine pericardium

Aortic and Ventricular Rings
-Inflate independently to facilitate repositioning in native annulus
- fulldevice retrieval through any 18F introducer

Multilumen Catheter

3 Position Fill Lumens (PFLs)
-Used to position/reposition valve
-Complete inflation media exchange

Conformable, polyester fabric cuff

Direct Flow Medical® Transcatheter Aortic Valve System

Recommended Sizing Guidelines

Native Annulus, Perimeter-Derived Diameter (mm):

19	20	21	22	23	24	25	26	27	28

Sizing Chart (mm):

Valve Size	23mm	25mm	27mm	29mm
Patient Annulus, Perimeter-Derived Diameter	19 – 23	21 – 25	24 – 27	26 – 29
Patient Annulus, Perimeter	60 – 72	66 – 78	76 – 85	82 – 91
Minimum Annular Dimension	≥ 17	≥ 19	≥ 22	≥ 24
Aortic Ring Diameter*	25	27	29	31
Ventricular/Annulus Ring Diameter	23	25	27	29
Annulus to Aortic Ring Height *(minimum coronary height)*	15	15	15	16

Note:
- Measurements made in Diastole and focus on the perimeter vs. area
- Perimeter is measured then divided by Pi (P = D*π) to find the equivalent circular diameter
- The diameter is compared to DFM valve size with a strategy of sizing 1:1

Case

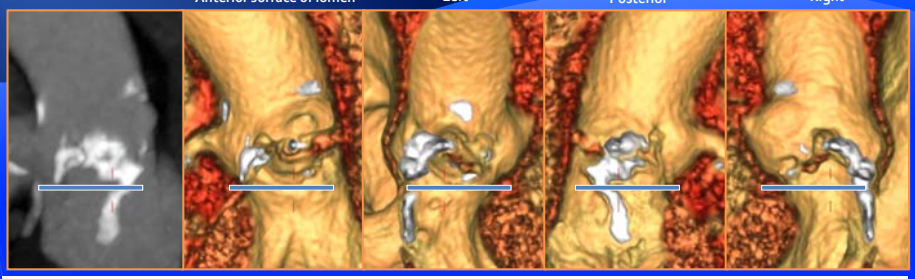

Vessel Diameters

Distance distal to valve root (mm)	Diameters calculated from perimeter (mm)	Average diameter (mm)	Major axis	Minor axis
20	---	25	25	24
15	---	28	*(sinuses: 30, 29, 26)*	
10	---	28	*(sinuses: 29, 28, 27)*	
5	---	26	*(sinuses: 27, 26, 25)*	
0	22	21	23	20
-3	21	22	25	18
-6	---	21	25	17

Coronaries

Valve to center line of LM (mm)	**15**
Valve to center line of RCA (mm)	**16**

Plaque distribution

Center line length above valve (mm)	**13**
Center line length below valve (mm)	**13**

Case

Asymmetric Leaflet Calcification (heavier at NC, lighter at RC)

Annulus measurements

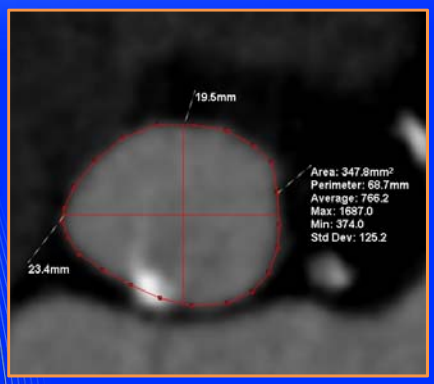

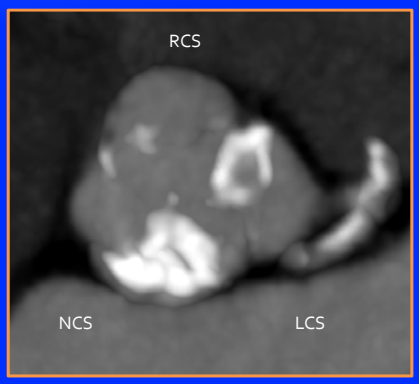

Case: Baseline TEE

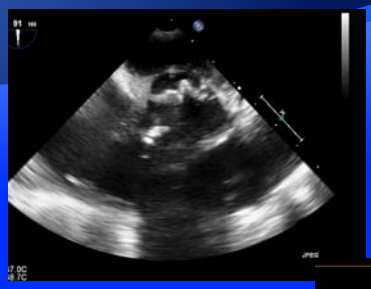

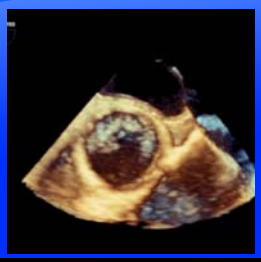

Bulky calcification of the Non-coronary cusp

Note: biplane imaging reversed the SAX view

Case: Baseline TEE

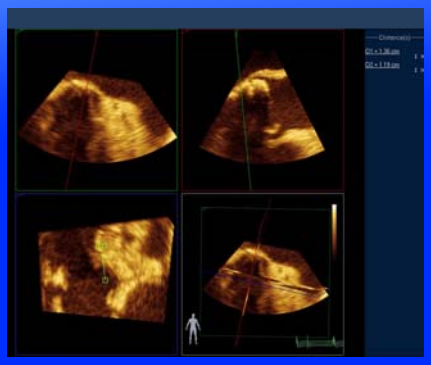

Perimeter = 70 cm
Area = 370 mm2

Height to LM orifice = 13.6 mm
Vertical Height LM = 11.9 mm

Case: Direct Flow Immediate Post-deployment

Markedly asymmetric deployment

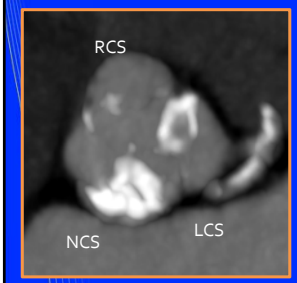

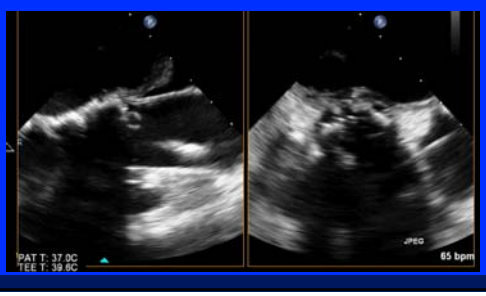

Case: Immediate Post-deployment

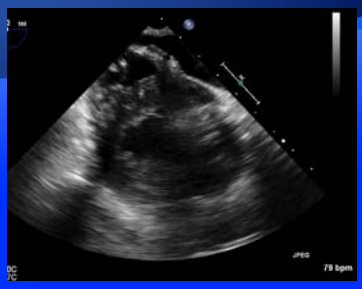

Normal LV function

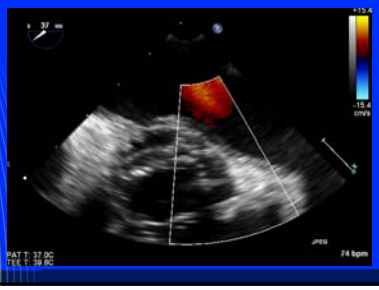

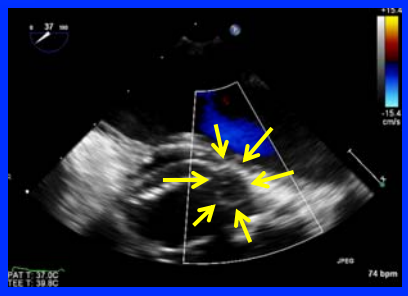

Distal Ring at level of LM

Case: 10 minutes post-polymer

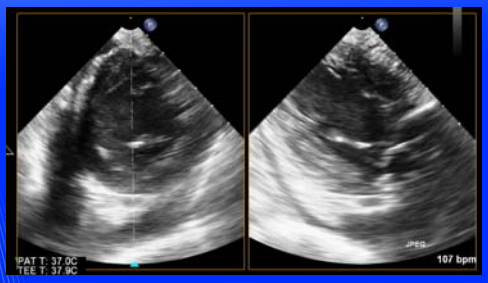

Severe LV dysfunction

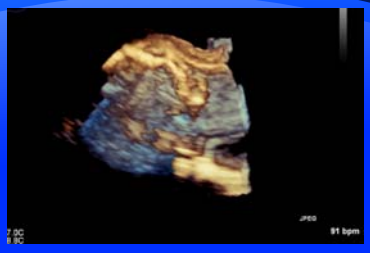

Occlusion of the entire Left coronary sinus of Valsalva

Case: Emergent LM Stent

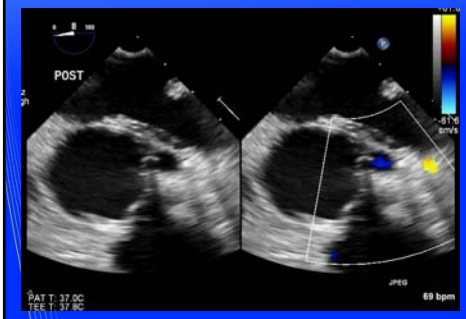

Stent intentionally positioned with proximal edge within the aorta and above the Direct Flow distal ring

Direct Flow Ring

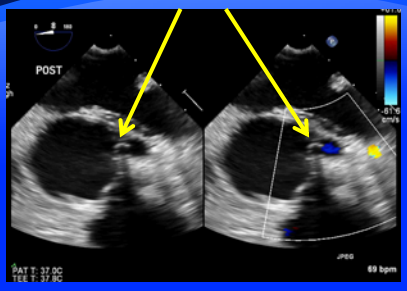

Protruding Stent

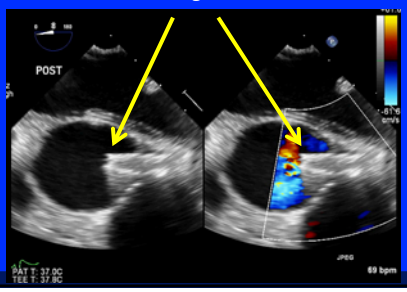

Case: Emergent LM Stent

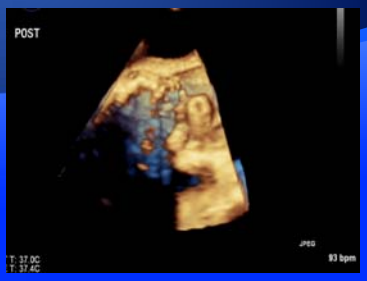

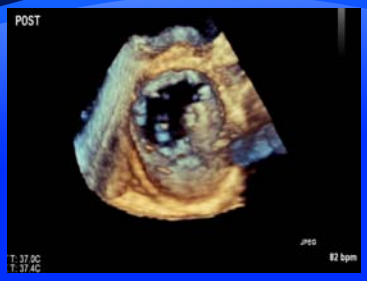

Stent intentionally positioned with proximal edge within the aorta and above the Direct Flow distal ring

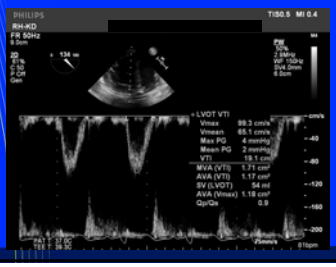

Aortic valve area = 1.26 cm2

"If what you've done is stupid but it works, then it really isn't that stupid at all."

~David Letterman

Thank You