Tricuspid and Pulmonary Valve Disease

Lawrence Rudski MD FRCPC FACC FASE
Professor of Medicine
Director, Division of Cardiology
Jewish General Hospital
McGill University

McGill

Jewish General Hospital

Question 1

- All of the following are compatible with severe Tricuspid Regurgitation except:
- A RV basal dimension measuring 50mm
- B Flow reversal in the hepatic veins after the P wave
- C PISA radius of 10 mm at an aliasing velocity of 30 cm/s
- D Non-parabolic TR CW Doppler signal with an early peak

Question 2

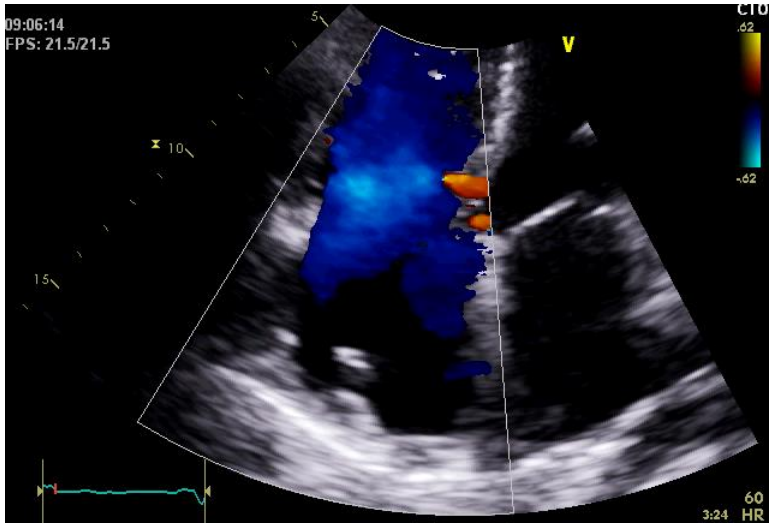

All of the following are true except:

A) The simplified Bernoulli equation is not valid

B) The septum is D-shaped in diastole

C) The PAP may be overestimated due to the presence of laminar flow

D) The RA pressure is likely > 15 mmHg

Question 3

Which of the following is least likely

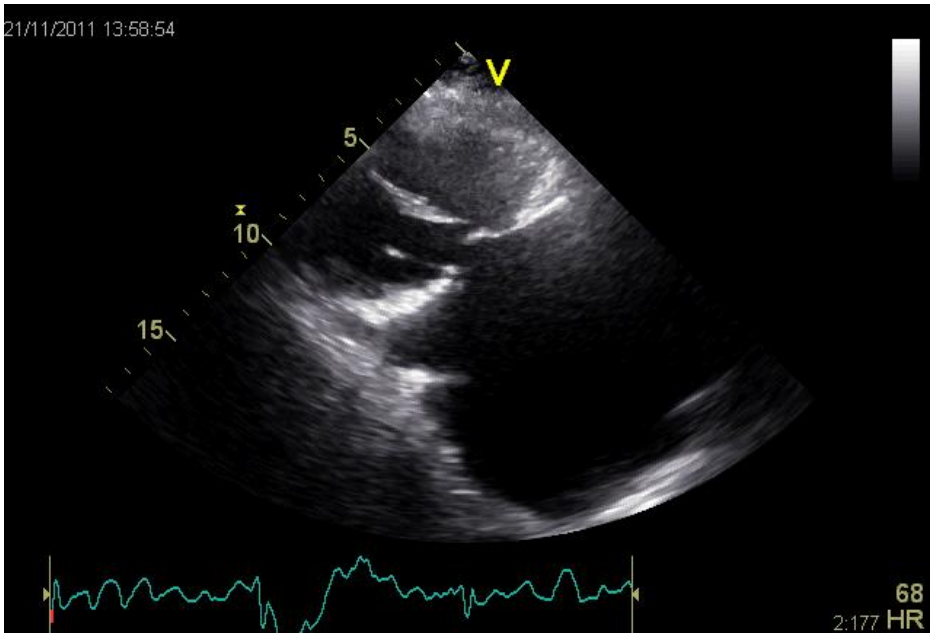

- A) A diastolic rumble will be heard over the apex
- B) The IVC will be markedly dilated
- C) Mitral inflow pulsed Doppler will demonstrate E:A reversal
- D) The RV systolic pressure will be significantly elevated

Tricuspid Regurgitation
So What?

- Right Sided Failure
  - Edema
  - Gut congestion
  - Atrial fibrillation
  - DEATH – associated with increased risk of death



Dyspnea!!!

Little TR – OK (useful for us, in fact)

Lots of TR - BAD

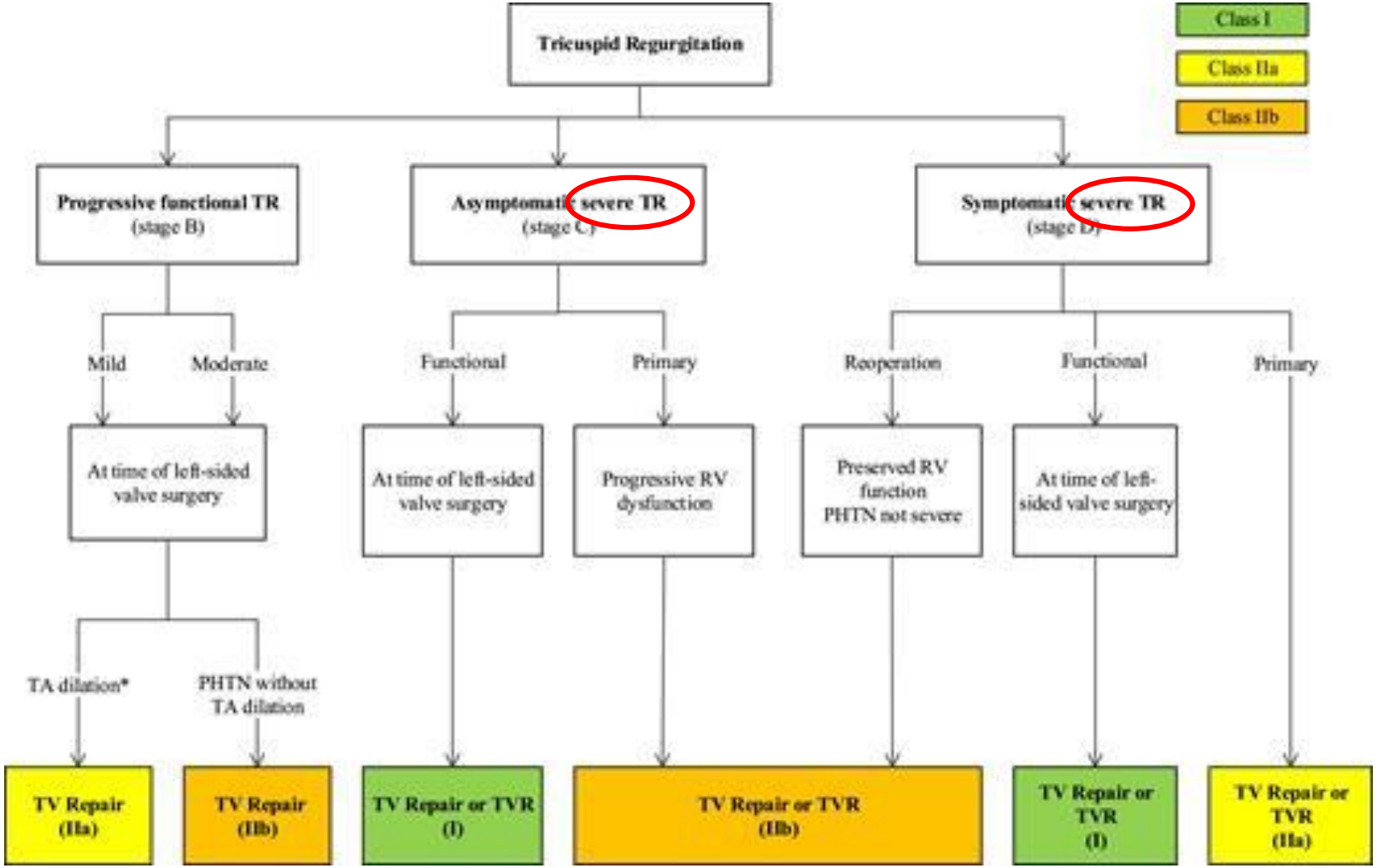
Tricuspid Regurgitation
Class I
Class IIa
Class IIb
Progressive functional TR
(stage B)
Asymptomatic severe TR
(stage C)
Symptomatic severe TR
(stage D)
Mild
Moderate
Functional
Primary
Reoperation
Functional
Primary
At time of left-sided valve surgery
At time of left-sided valve surgery
Progressive RV dysfunction
Preserved RV function
PHTN not severe
At time of left-sided valve surgery
TA dilation*
PHTN without TA dilation
TV Repair (IIa)
TV Repair (IIb)
TV Repair or TVR (I)
TV Repair or TVR (IIb)
TV Repair or TVR (I)
TV Repair or TVR (IIa)

TR predicts survival (n=5,223)

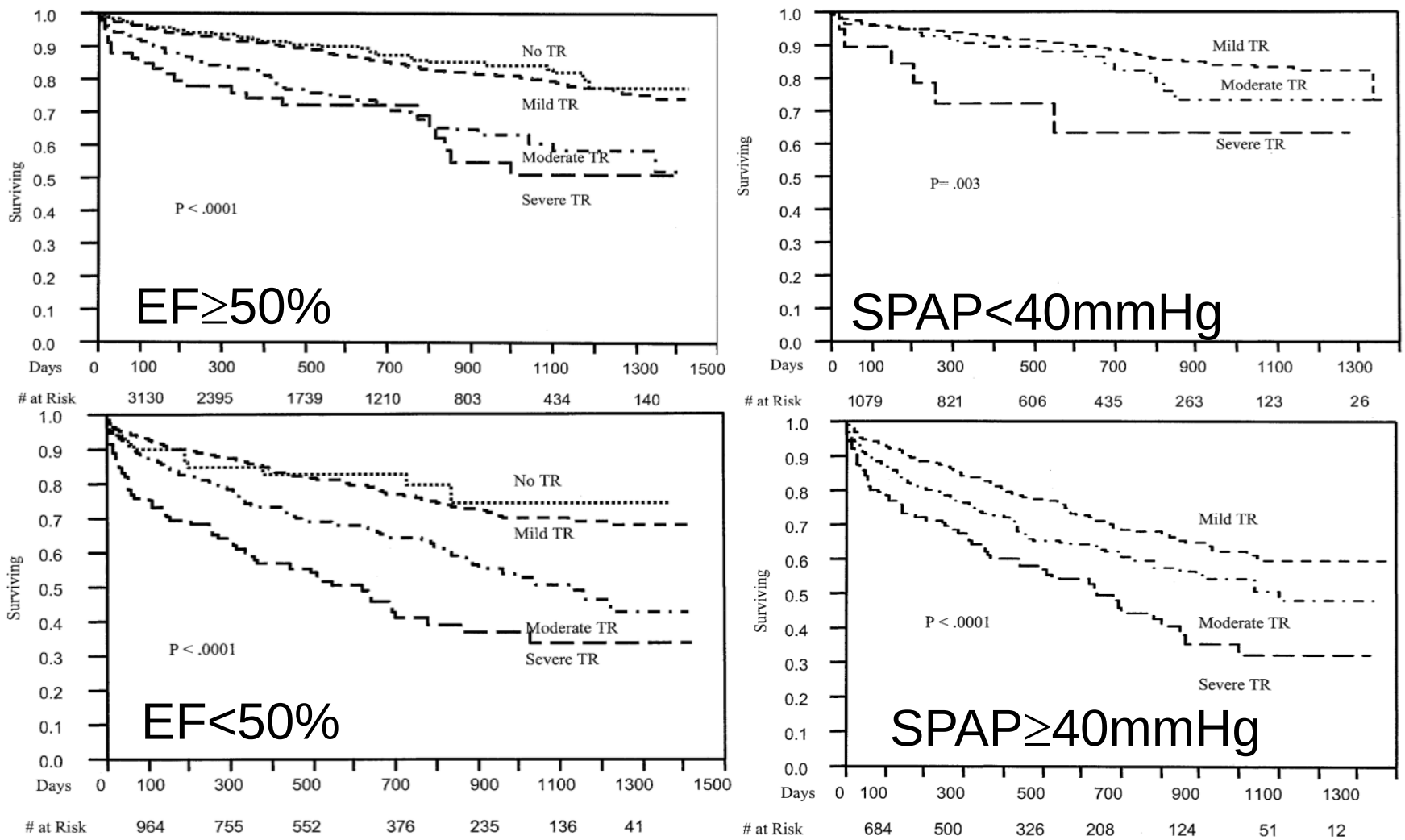

Nath et al (VA, Palo Alto), JACC 2004

“Complex” Anatomy (literally)

- Leaflet(s) – One continuous leaflet with indentations into Anterior, Septal, Posterior
- Annulus – D-shaped, with flatter portion along the central fibrous body - contractile
- Chordae
- Papillary muscles – usually 3
- Underlying Right Ventricular Myocardium

View from Above

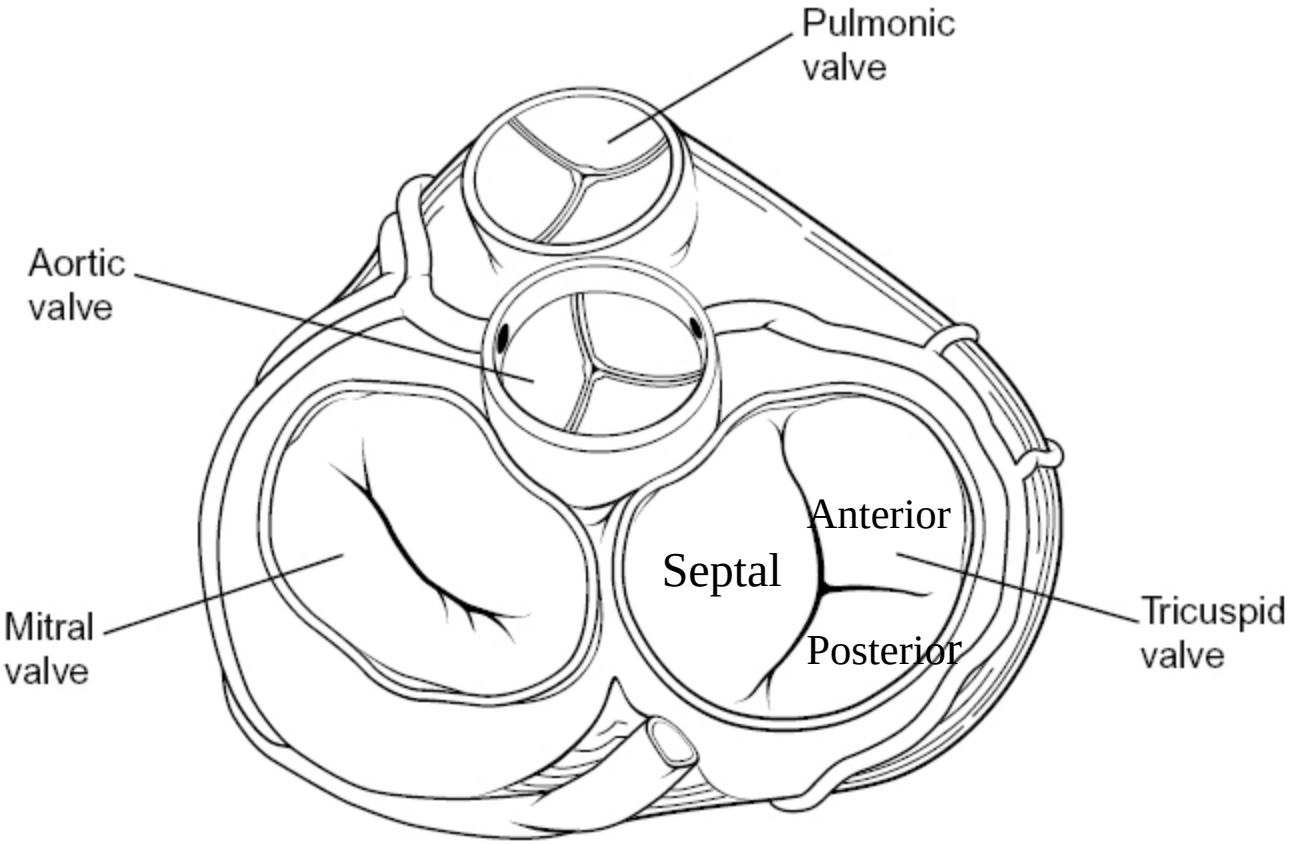

Tricuspid Valve Anatomy - TTE

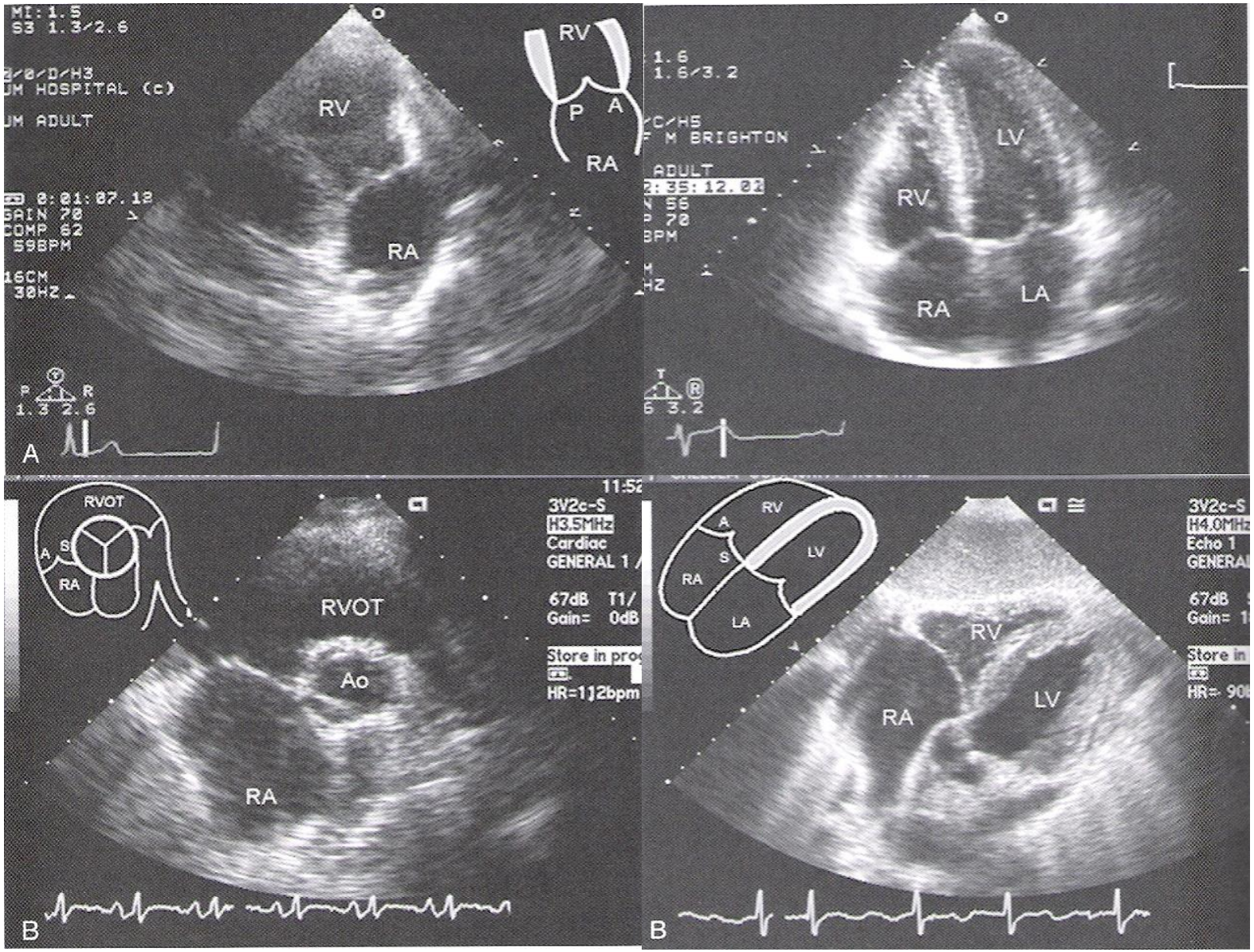

Tricuspid Valve Anatomy - TEE

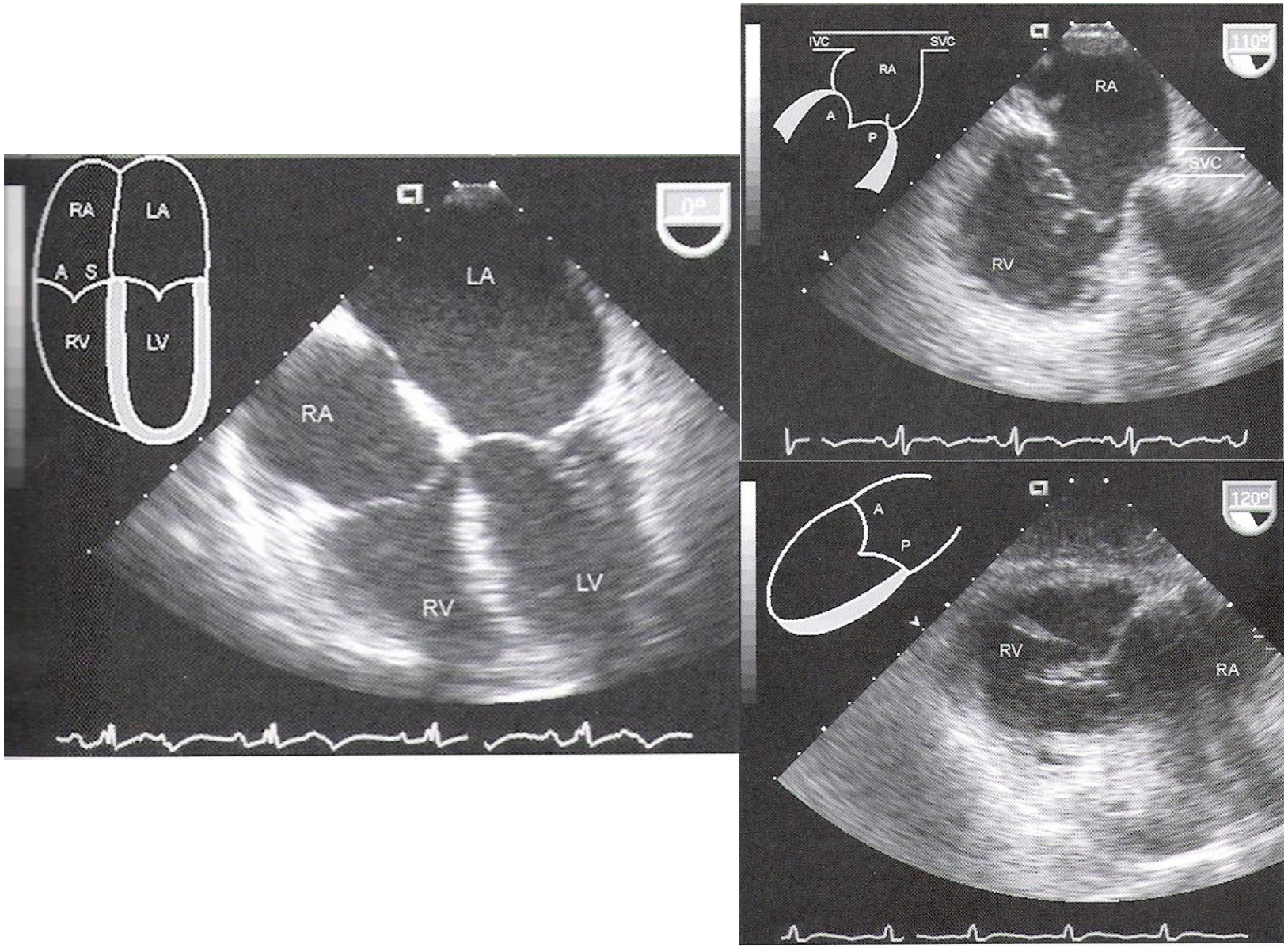

Incremental Value of the En Face View of the Tricuspid Valve by Two-Dimensional and Three-Dimensional Echocardiography for Accurate Identification of Tricuspid Valve Leaflets

Ivan Stankovic, MD, Ana Maria Daraban, MD, Ruta Jasaityte, MD, Aleksandar N. Neskovic, MD, PhD, Piet Claus, PhD, and Jens-Uwe Voigt, MD, PhD, *Leuven, Belgium; Belgrade, Serbia*

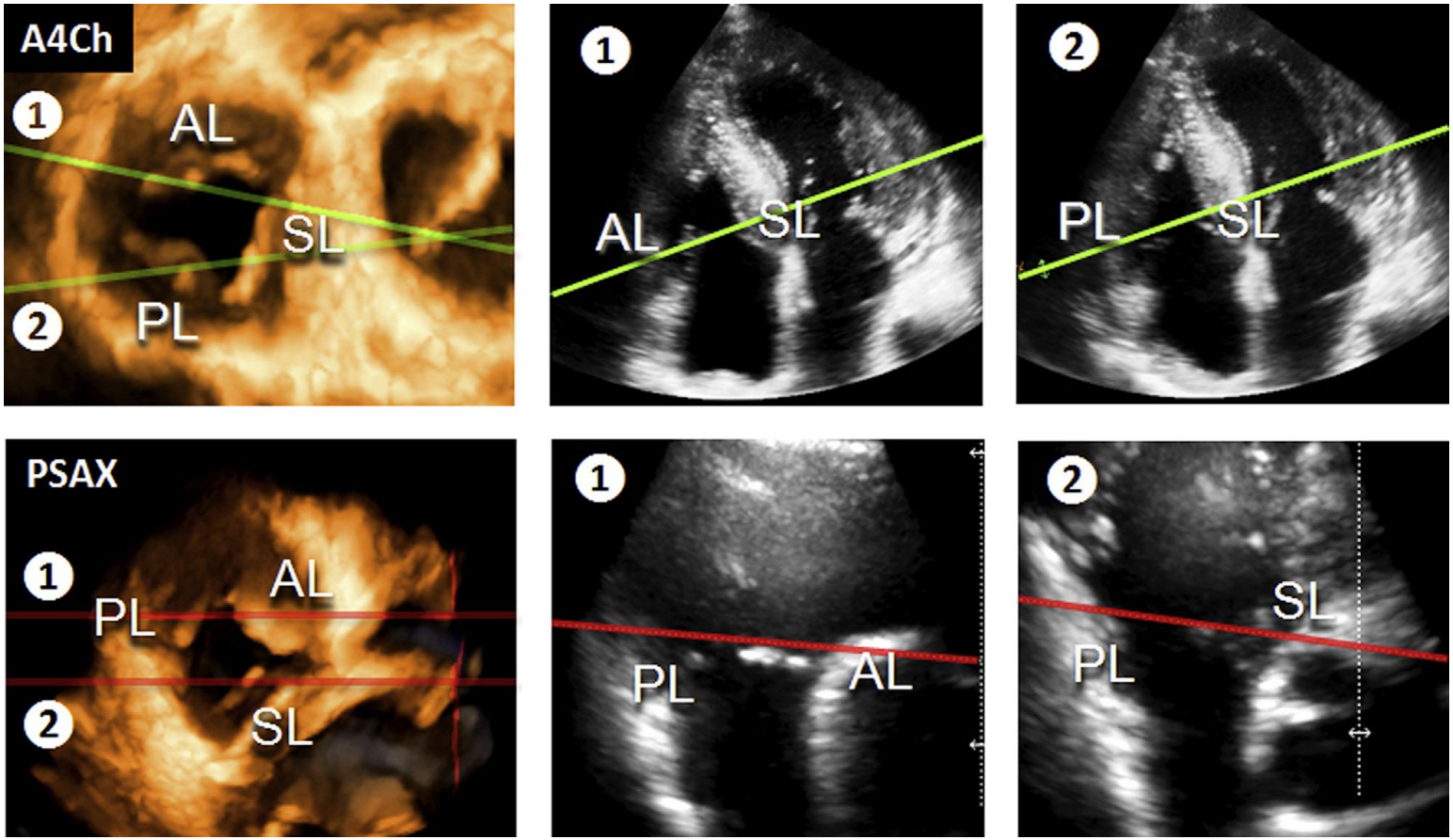

Journal of the American Society of Echocardiography
Volume 27 Number 4

Why is this important ?

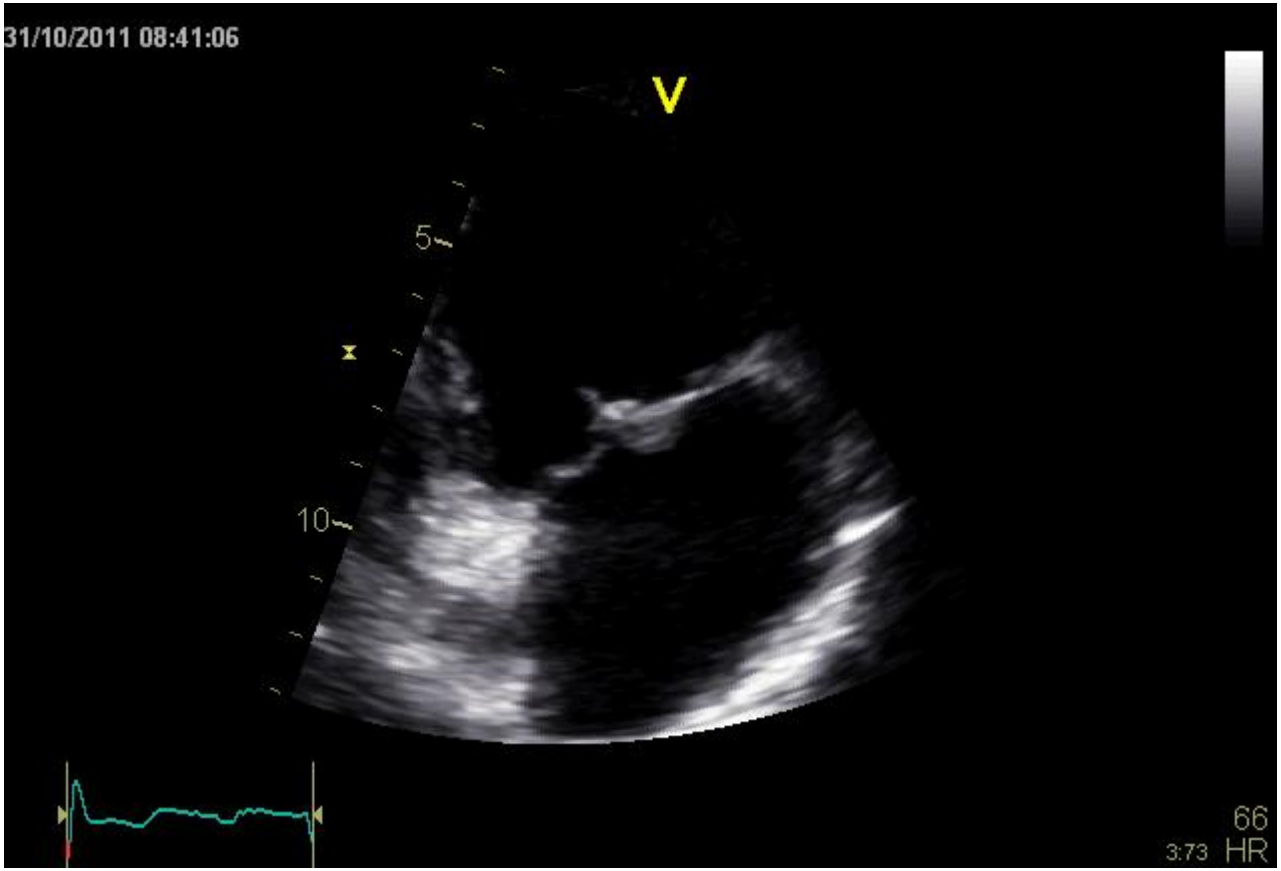

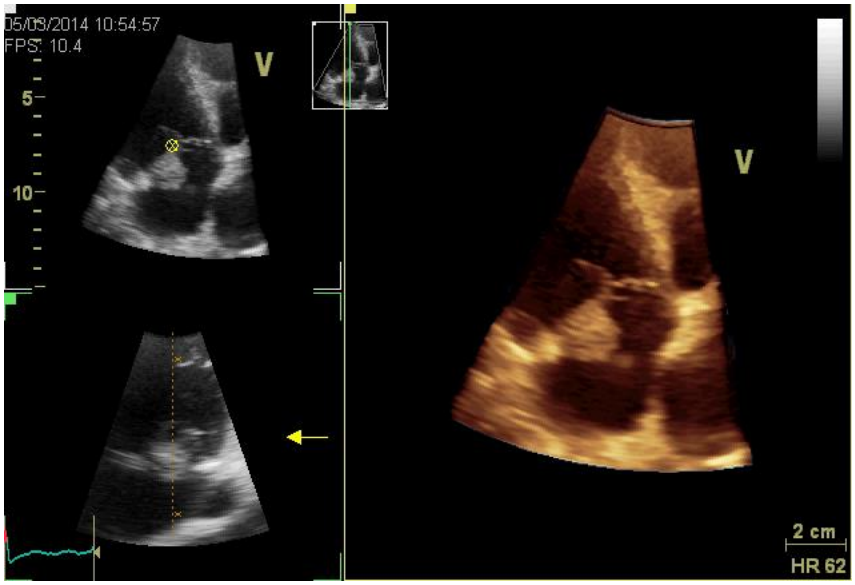
05/03/2014 10:54:57
FPS: 10.4
V
5
10
V
2 cm
HR 62

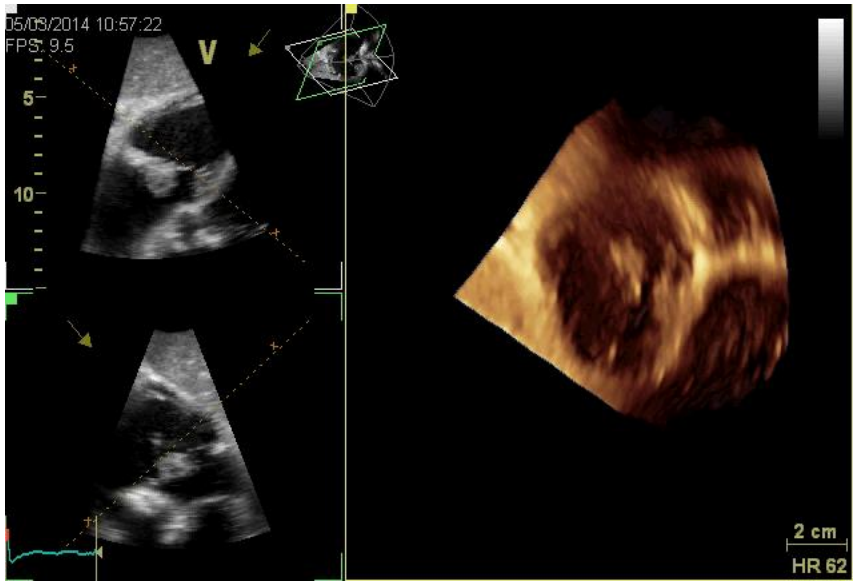
05/03/2014 10:57:22
FPS: 9.5
V
5
10
2 cm
HR 62

What Can Go Wrong?

- Leaky
  - Stretched
  - Infected, with long-term sequelae
  - Perforated
  - Skewered
  - Ripped
- Narrowed
  - Rheumatic
  - Evil Humors

Etiologies of TR

- Functional TR
  - PAH
  - Vol. Overload e.g. ASD
  - Cor Pulmonale
  - Left heart Disease
  - RV myocardial Disease
    - RV dysplasia
    - RV ischemia
    - Post-transplant
- Primary TR
  - Rheumatic
  - Myxomatous
  - Ebstein's Anomaly
  - Endocarditis
  - Carcinoid/Infiltrative
  - Traumatic – anterior structure-MVA
  - Iatrogenic
    - Pacer/ICD wires
    - RV biopsy

No reason why Carpentier's Classification can't apply

Primary or Secondary?
PA Pressure - As a ***general rule***…

- In setting of severe TR, PAPs > 55 mmHg is often associated with anatomically normal tricuspid valves, while PAPs < 55 mmHg usually associated with an abnormality of the tricuspid valve apparatus.

Tricuspid Valve Assessment

- Leaflets
  - Thickening, doming, restriction
  - Coaptation
  - Flail
- Annulus diameter
- Mean gradient
- TR severity
- RA + RV dilatation, septal flattening
- RV systolic function
- PA pressure

Leaflets

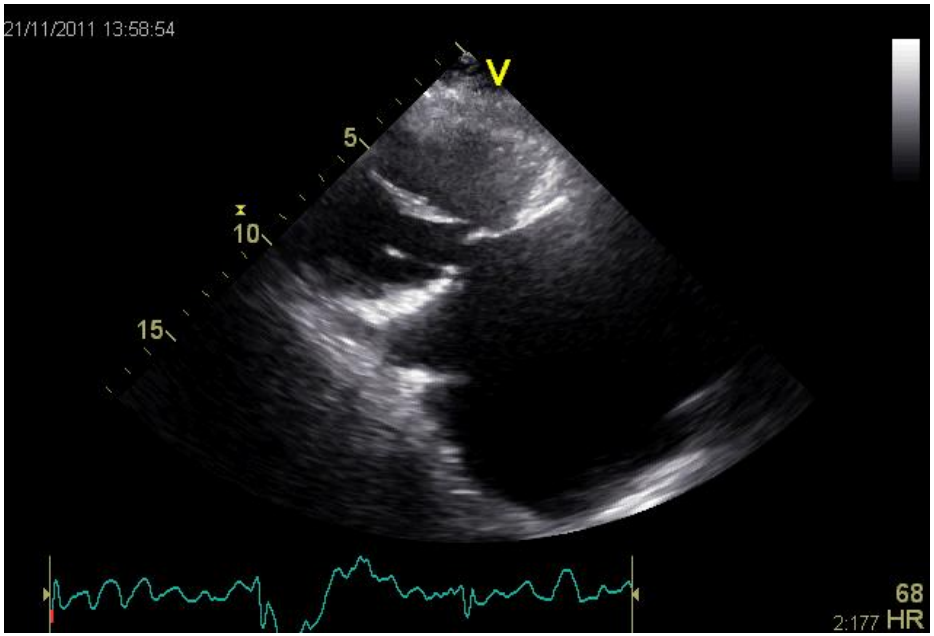

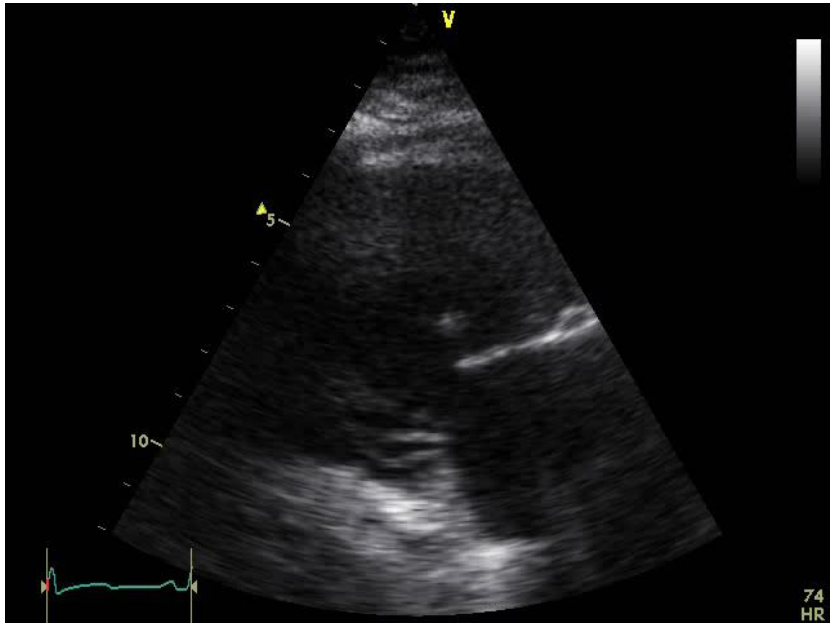

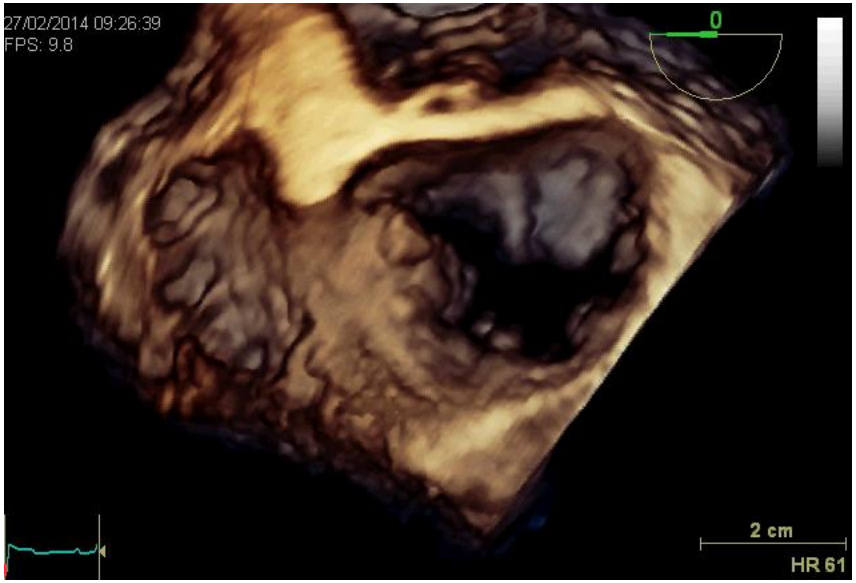
27/02/2014 09:26:39
FPS: 9.8
0
2 cm
HR 61

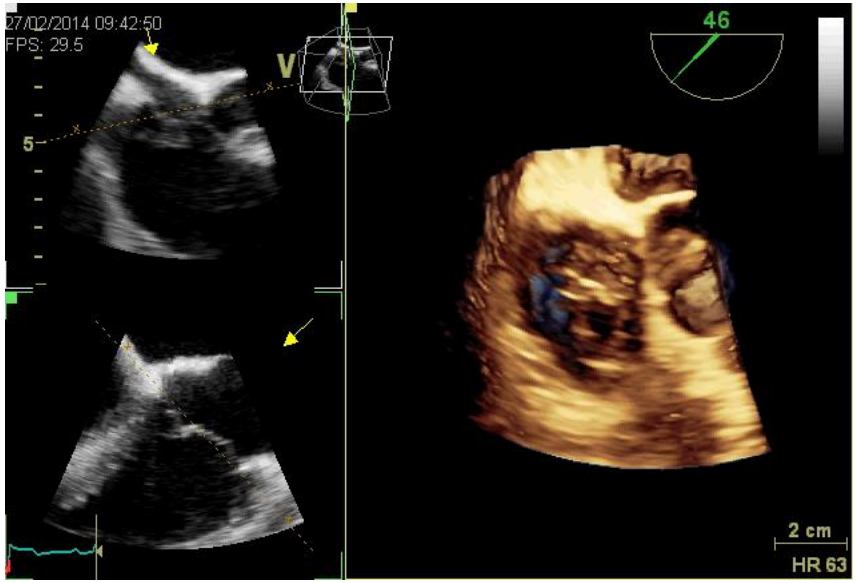
27/02/2014 09:42:50
FPS: 29.5
V
5
46
2 cm
HR 63

Bicuspid TV Valve

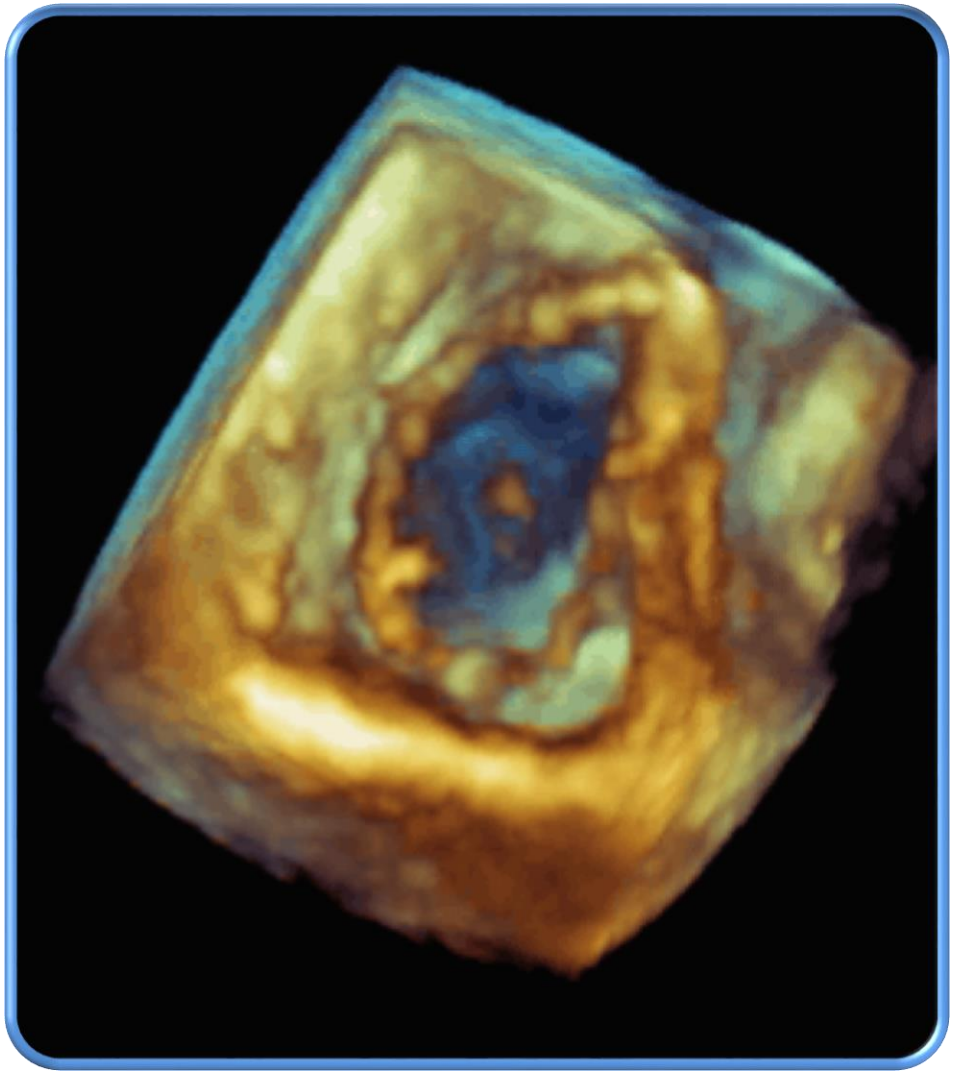

Courtesy of Dr. Roberto Lang

Pacemaker Lead Impingement

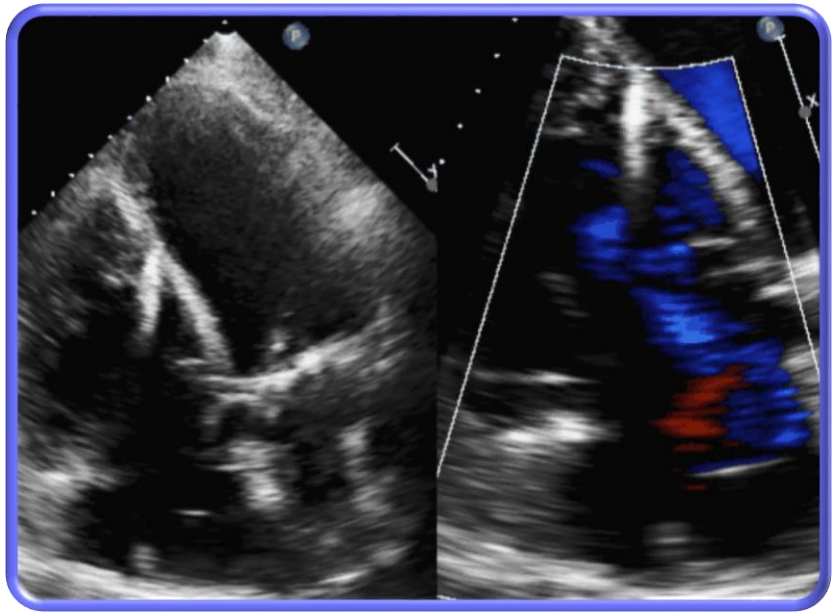

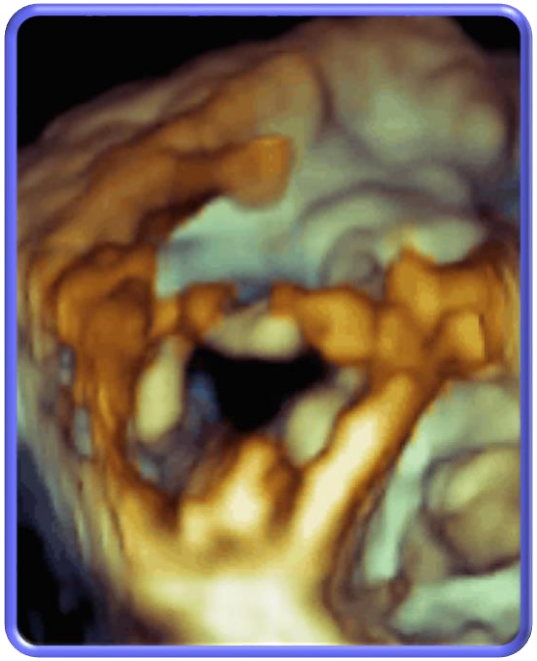

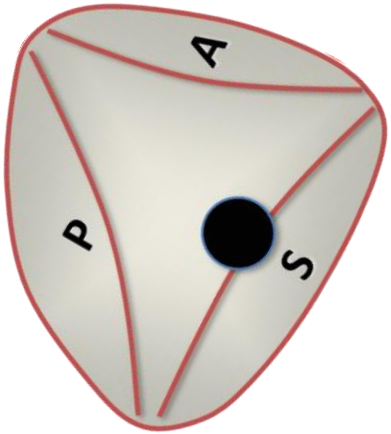

Courtesy of Dr. Roberto Lang

Not TV Dinner, but TV Kebab

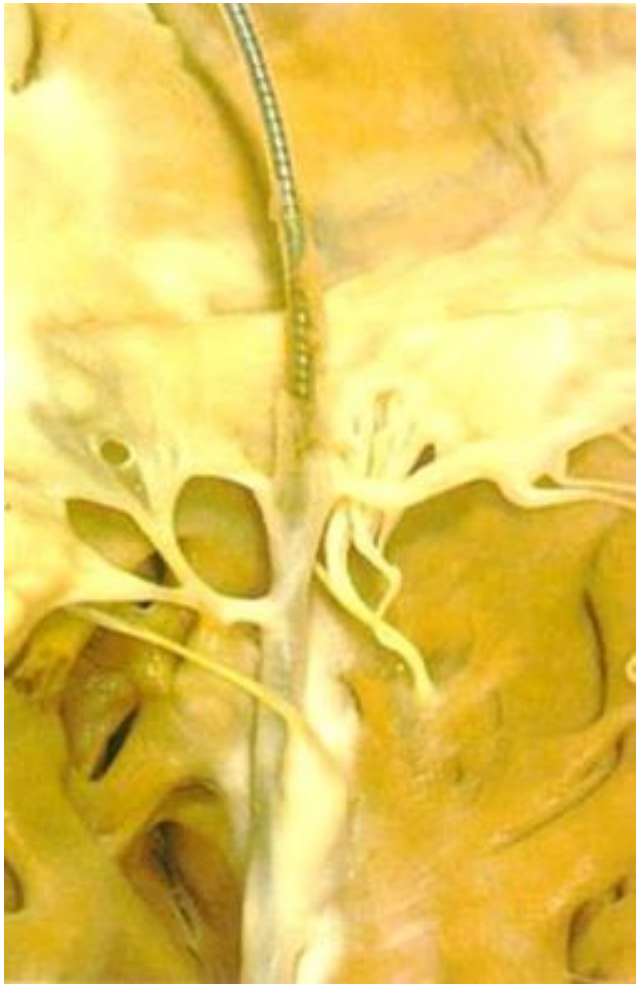

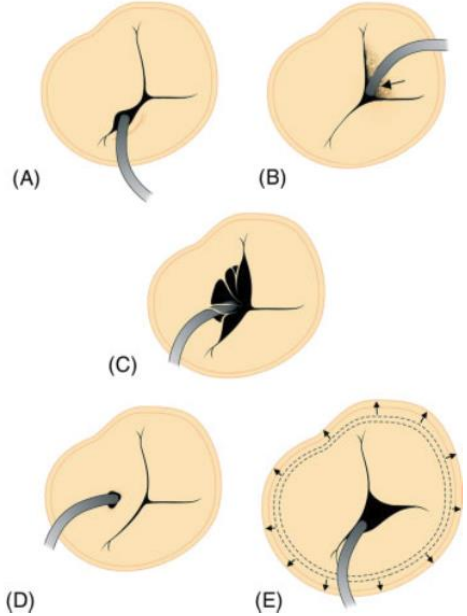

R. Al-Bawardy et al: TR in patients with pacemakers and ICDs
Clin. Cardiol. 36, 5, 249–254 (2013)

- (a) Valve obstruction caused by lead placed in between leaflets.
- (b) Lead adherence due to fibrosis and scar formation to valve causing incomplete closure.
- (c) Lead entrapment in the tricuspid valve apparatus
- (d) Valve perforation or laceration.
- (e) Annular dilatation.

Al-Mohaissen and Chan (J Am Soc Echocardiogr 2012;25:245-52.)

Annular Dimension

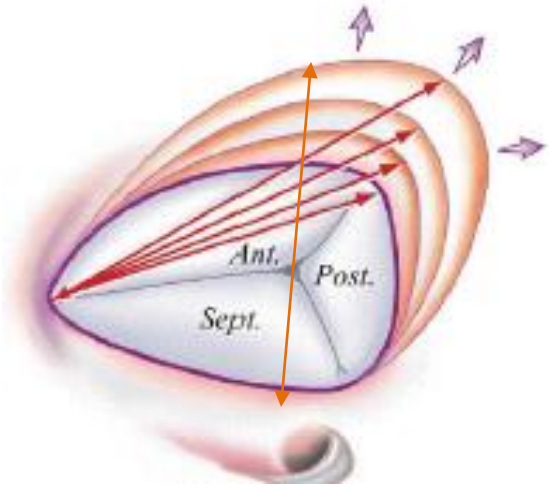

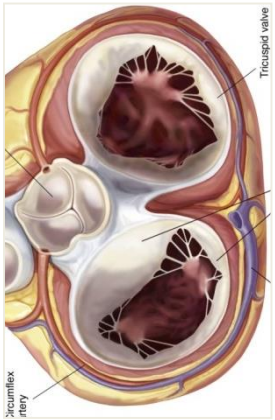

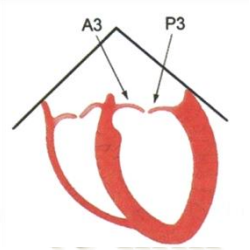

70 mm

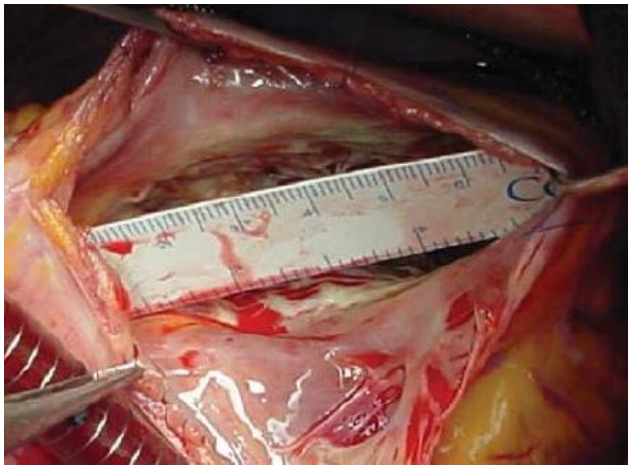

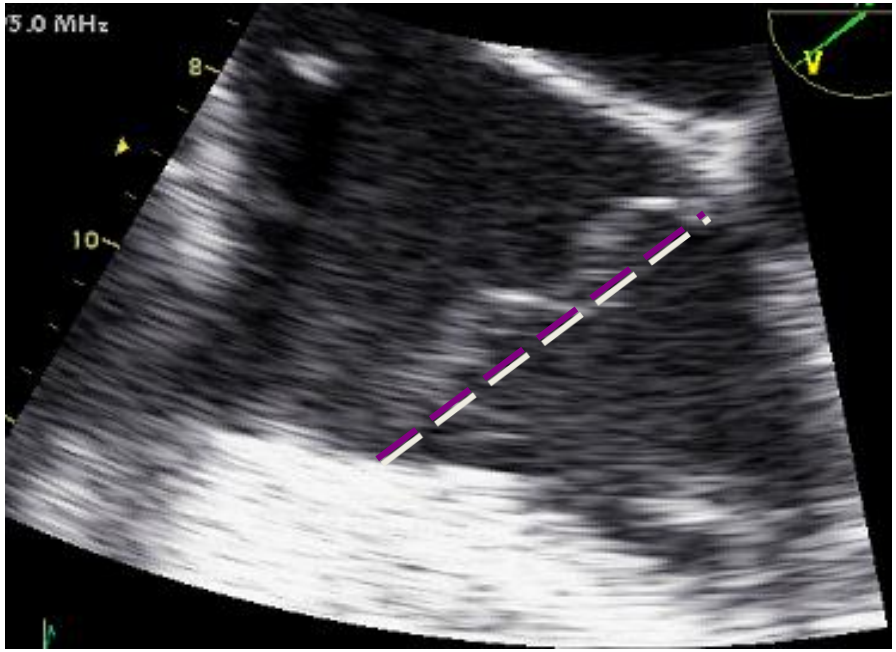

Dreyfus G and al. Ann Thorac Surg 2005;79:127–32

Annulus Diameter

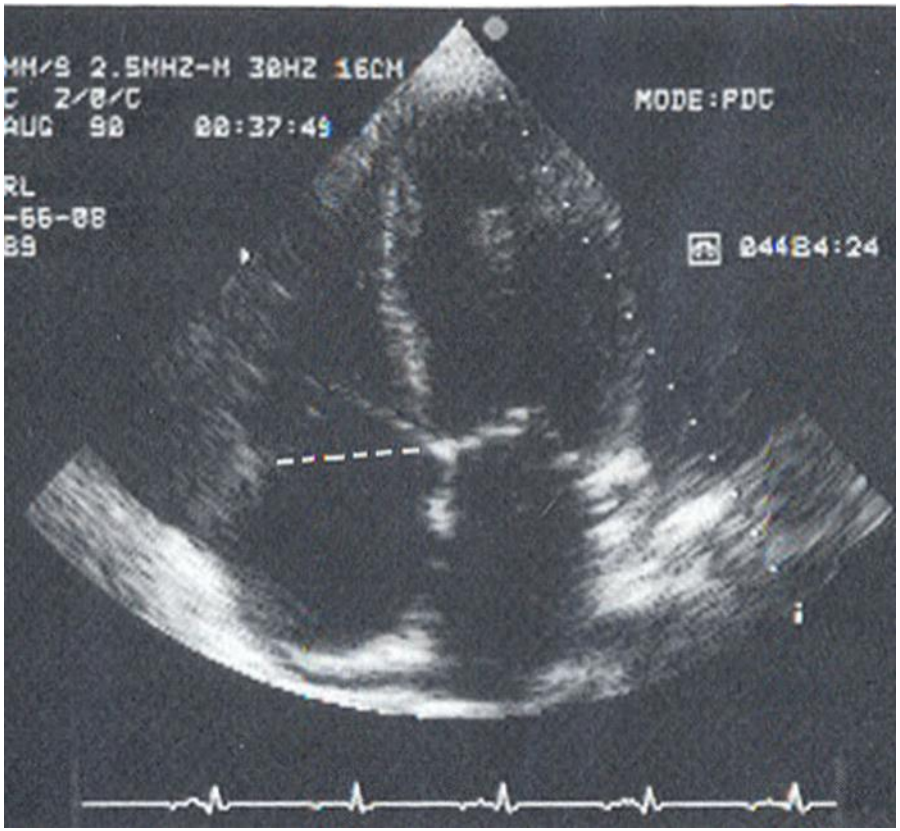

40 mm or 21 mm/m2

Quantitation?

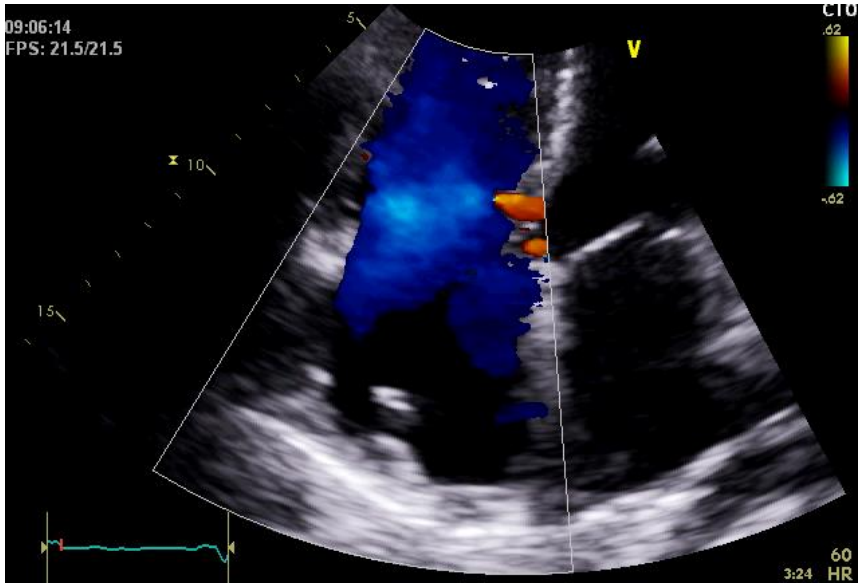

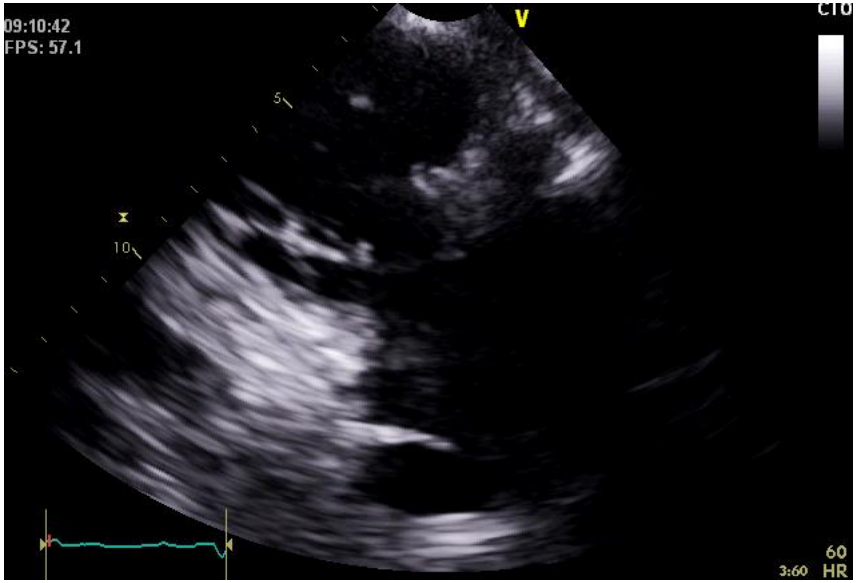

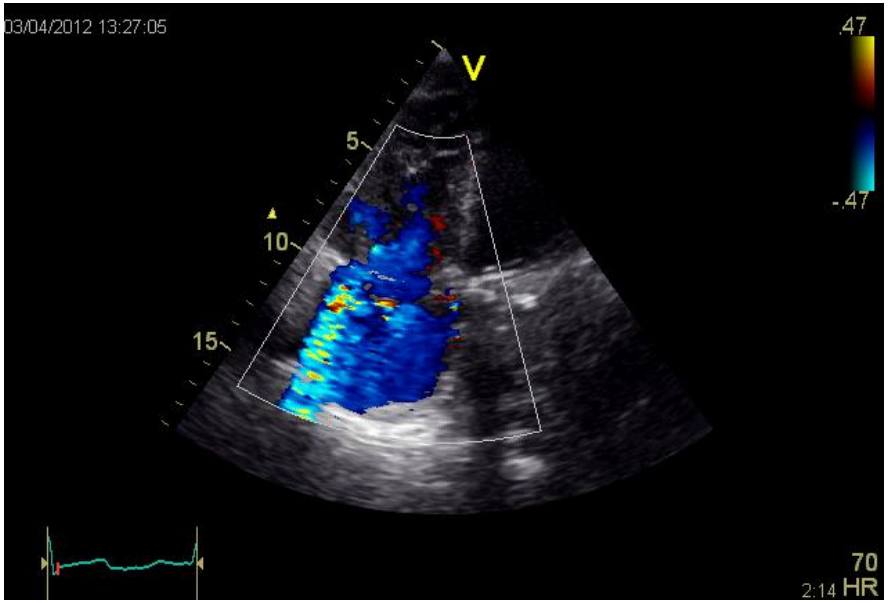

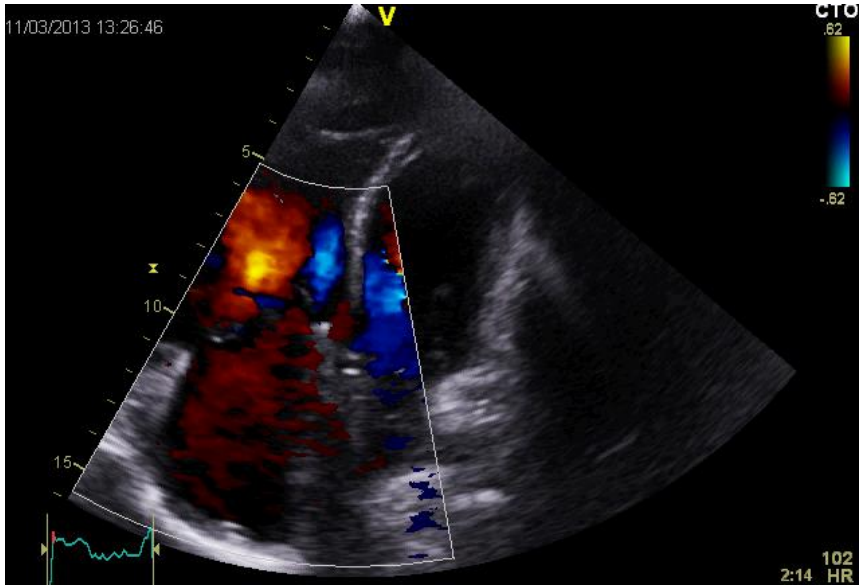
11/03/2013 13:26:46
V
CTO
.62
-.62
5
10
15
102
2:14 HR

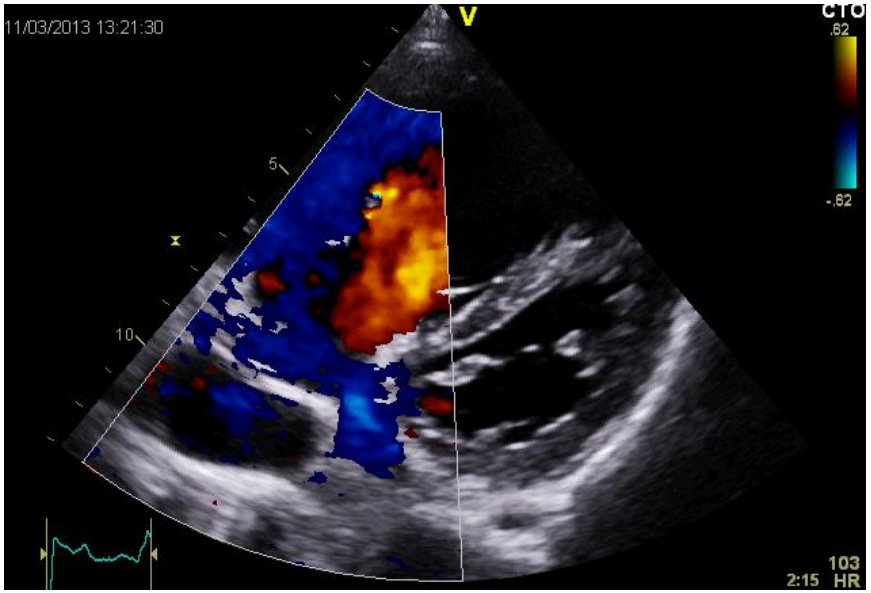
11/03/2013 13:21:30
V
CTO
.62
-.62
5
10
103
2:15 HR

Quantification of TR by Color Doppler

- Simplest and quickest way to evaluate TR severity but limitations and uncertainties

<u>Analogous to MR Assessment by color Doppler</u>

- A large color jet represents more significant tricuspid regurgitation than a small jet
- Visualisation of the color jet depends on:
  - Hemodynamic/Loading Conditions
    - Hyper/Hypotension
    - RA Pressure and pressure gradient between RV-RA
    - RA size and capacitance
    - Phase of respiration
  - Cause of regurgitation
    - Excentric Jet (Coanda effect)-use multiple views
    - Vs. Central Jet
  - Technical Limitations
    - Sub-optimal views
    - Gain settings

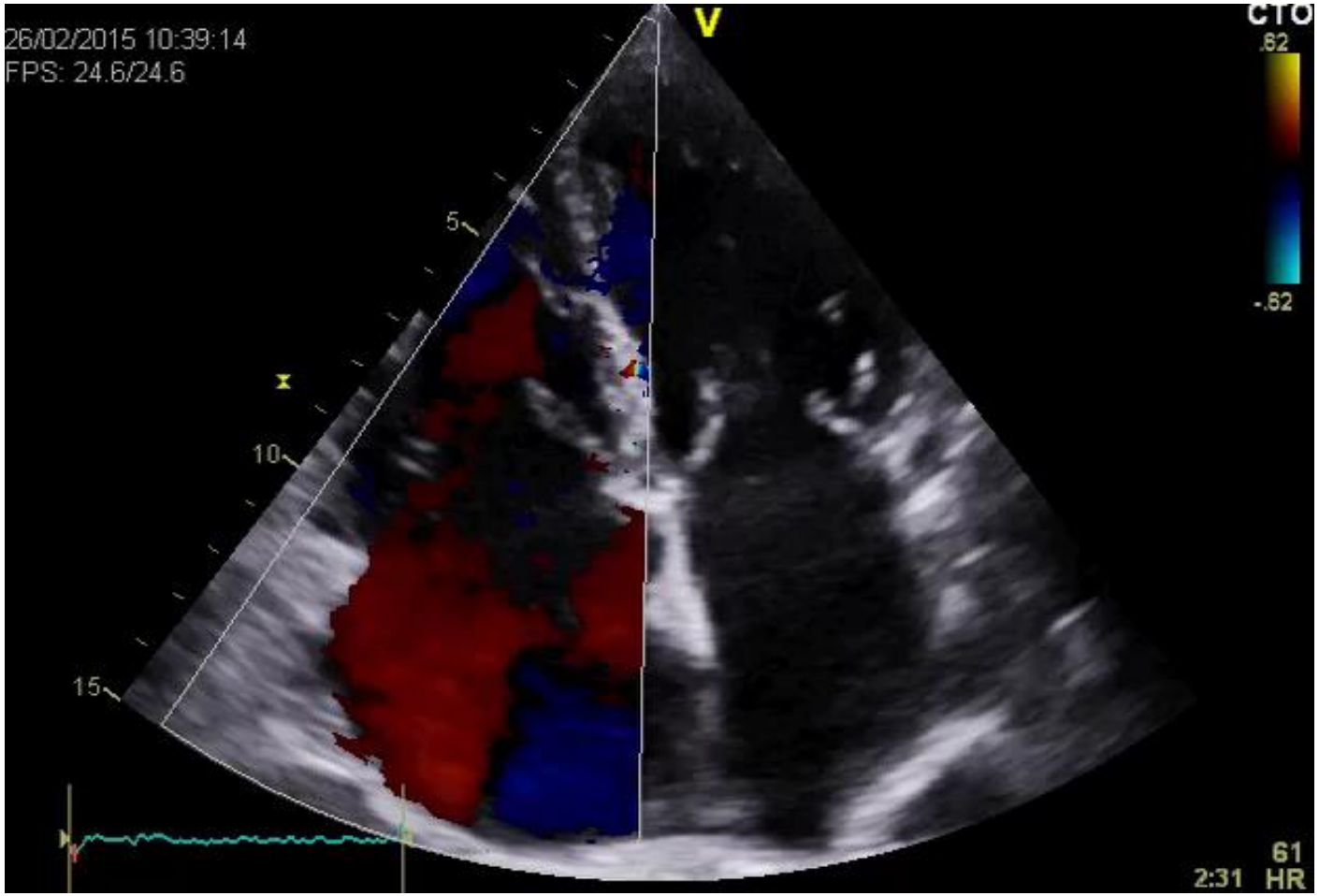
26/02/2015 10:39:14
FPS: 24.6/24.6
V
CTO
.62
-.62
5
10
15
61
2:31 HR

Quantitation – Vena Contracta

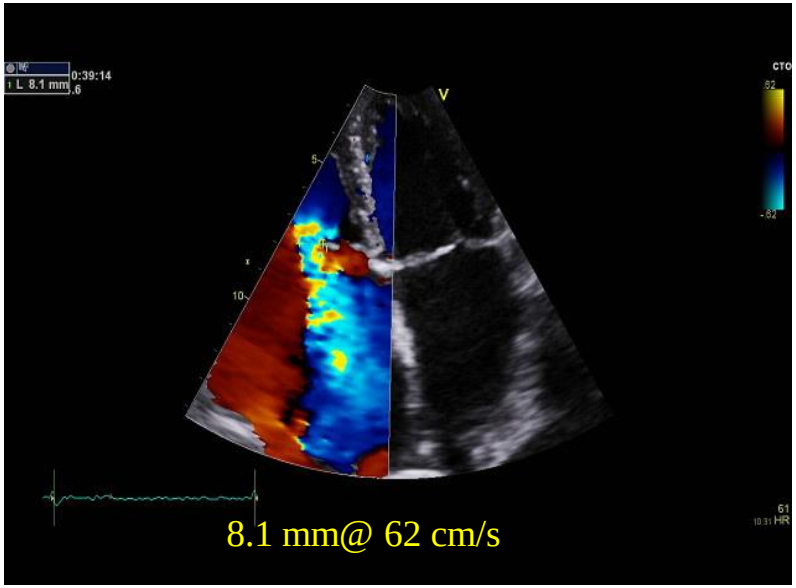

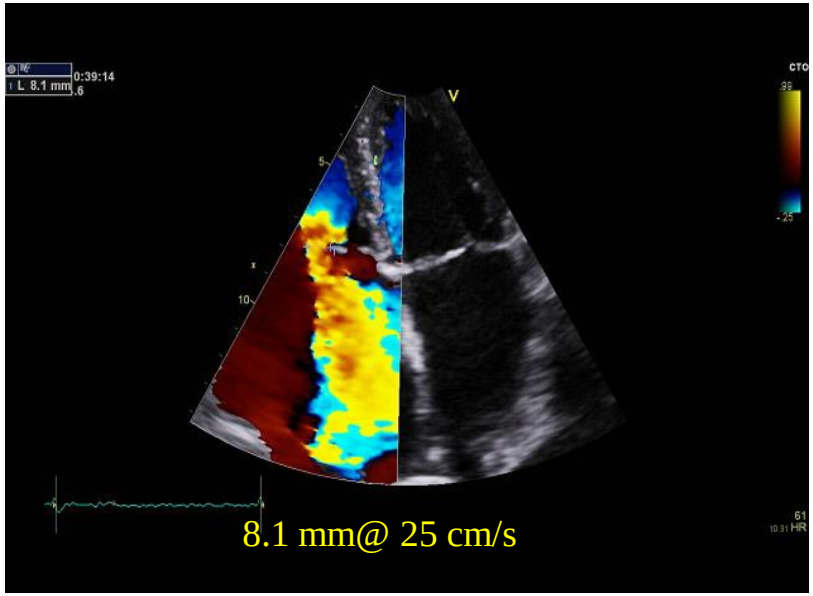

Severe : VC > 0.7 cm

Nyquist 50-60 cm/s

TR by PISA

- Set Nyquist Limit to aliasing velocity of 28 cm/s
- A Radius of > 9mm correlates with severe TR
- 6-9mm moderate TR
- < 5mm, usually with mild TR

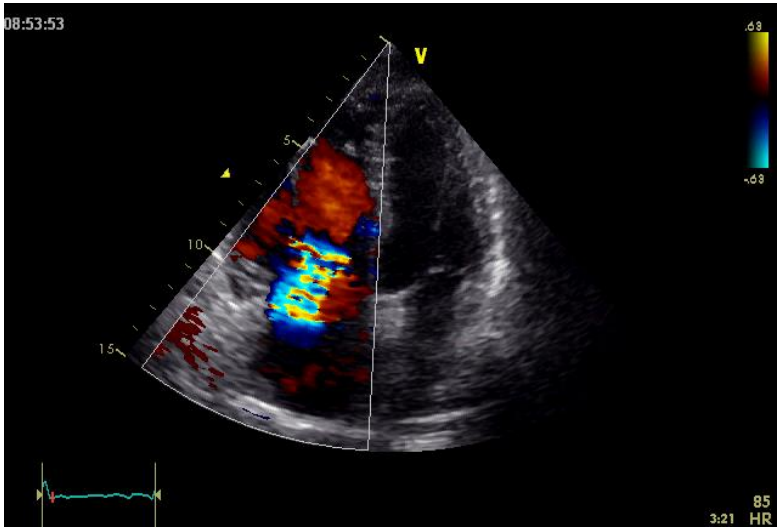

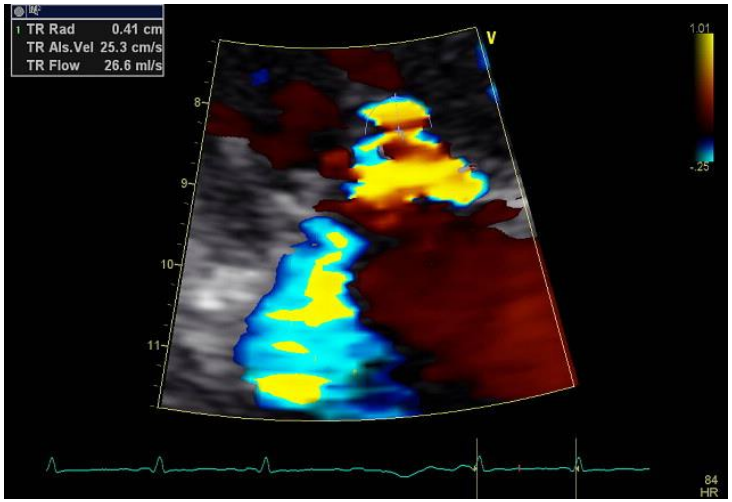

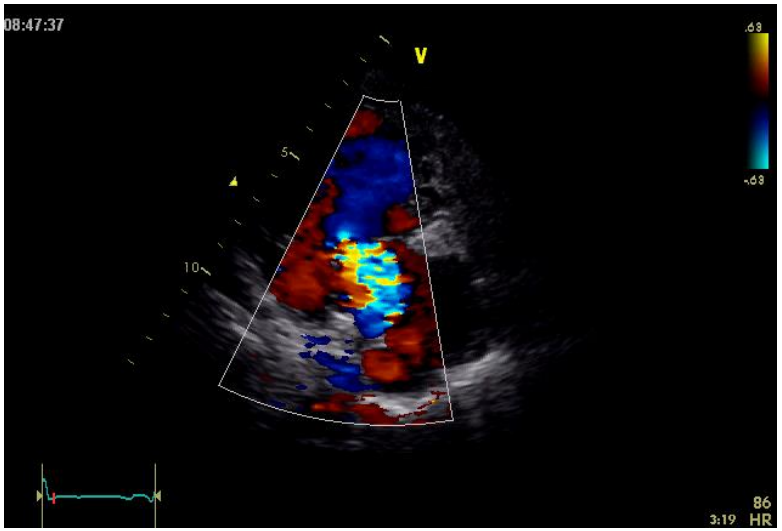

$EOA = 2\pi R^2 \times V_{alias} / V_{max}$

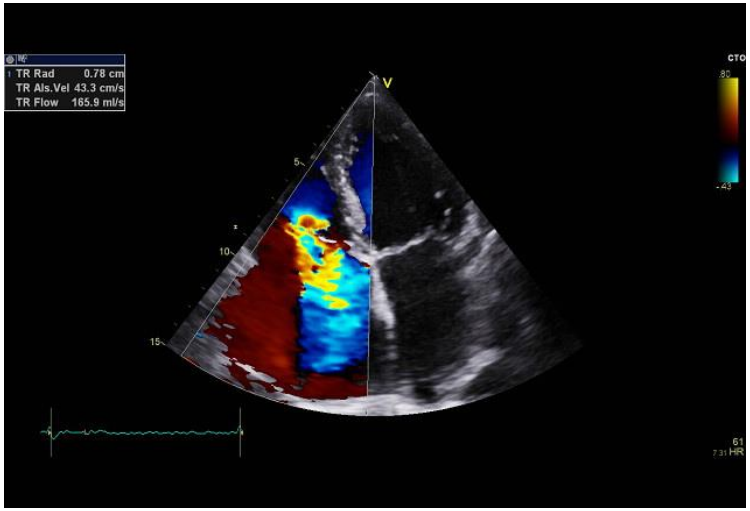

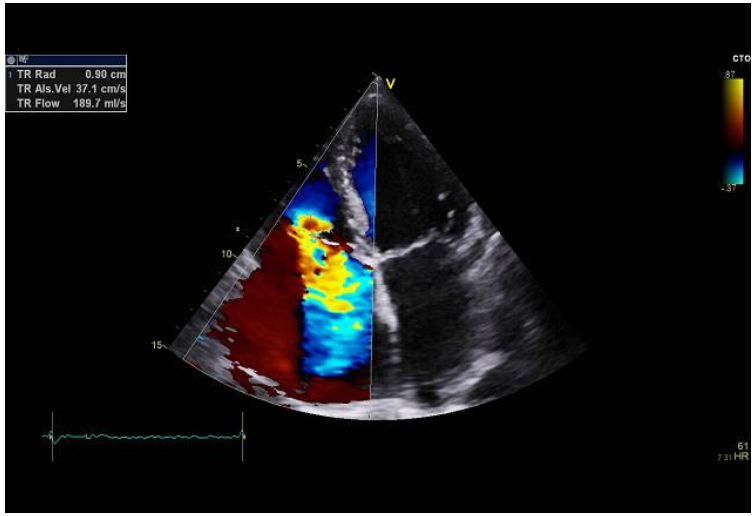

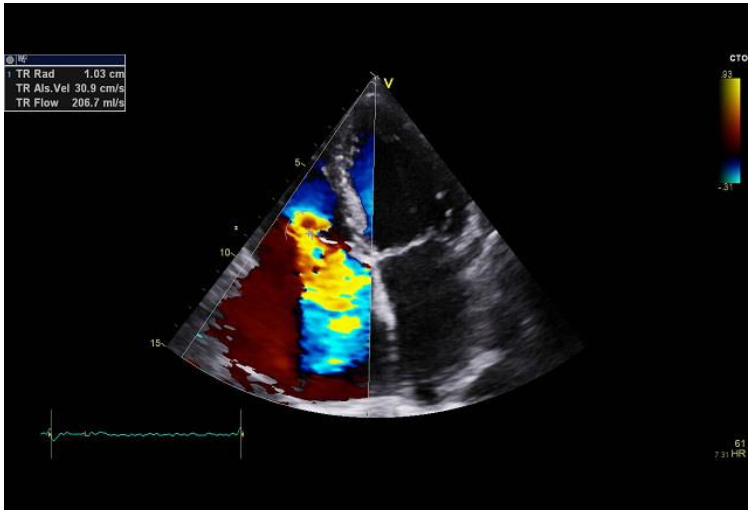

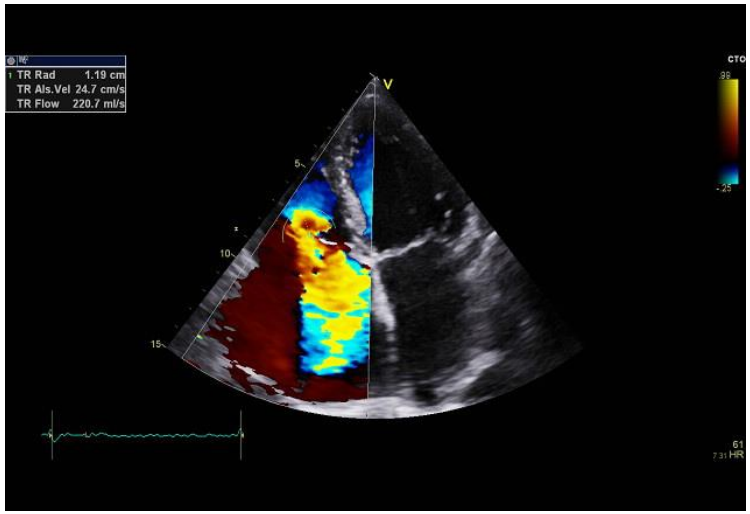

Nyquist – Radius	
cm/sec	cm
28	0.9cm
25	1.0cm
31	0.8cm
37	0.68cm
43	0.59cm

Hepatic Vein Reversal

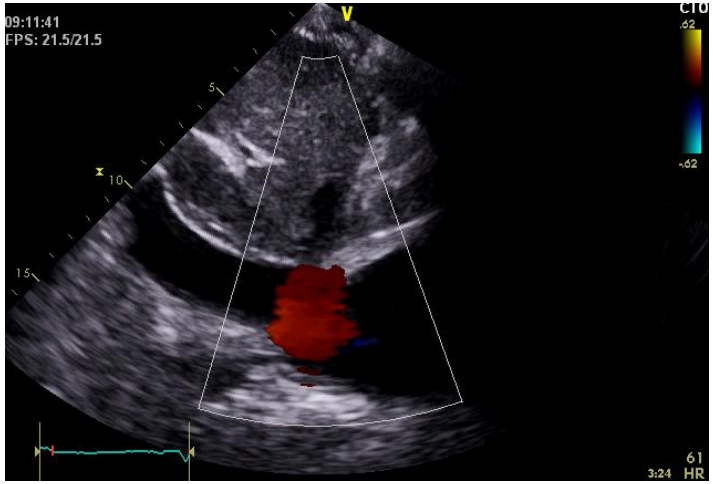

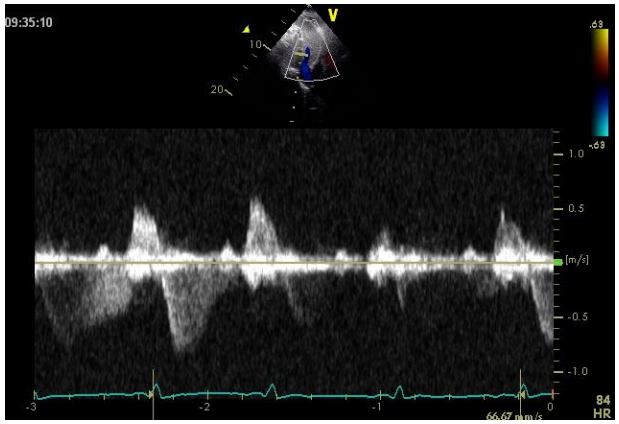

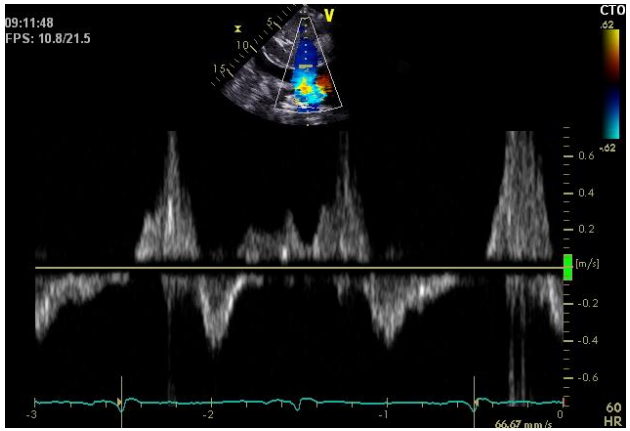

TR signal – density and shape

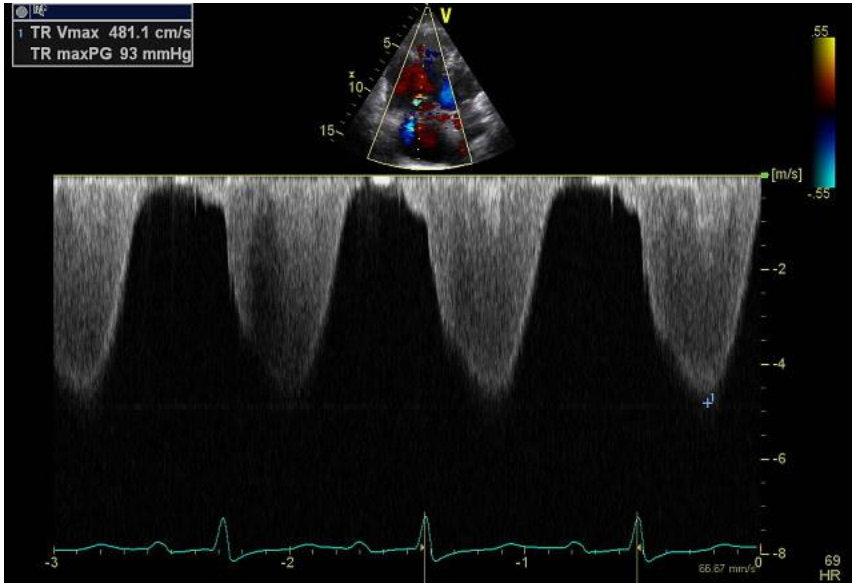

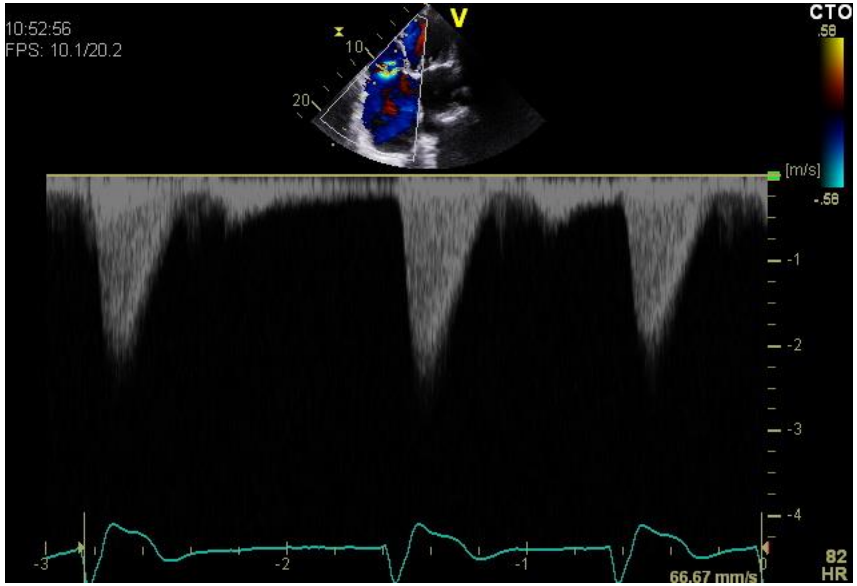

Effect on RV (and vice versa)

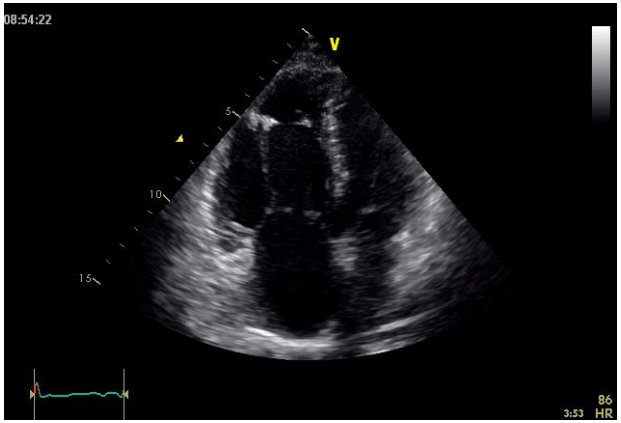

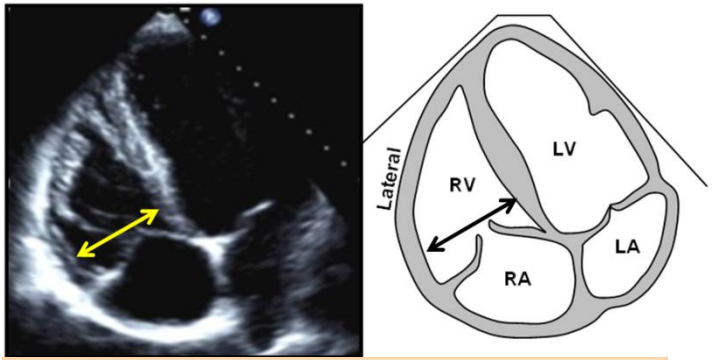

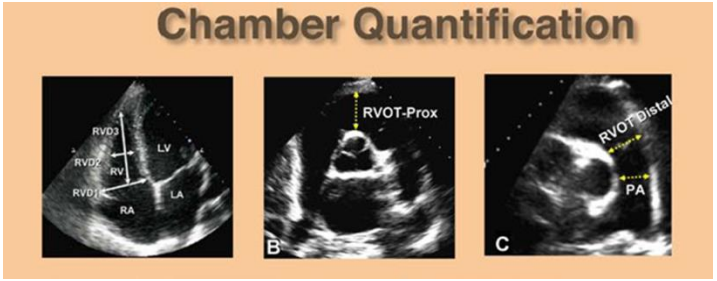

Variable	Abnormal
A. RV Basal (RVD1)	> 4.2 cm
RV Mid (RVD2)	> 3.5 cm
RV Longitudinal (RVD3)	> 8.6 cm
B. RVOT PLAX proximal	> 3.3 cm
C. RVOT PSAX distal	> 2.7 cm

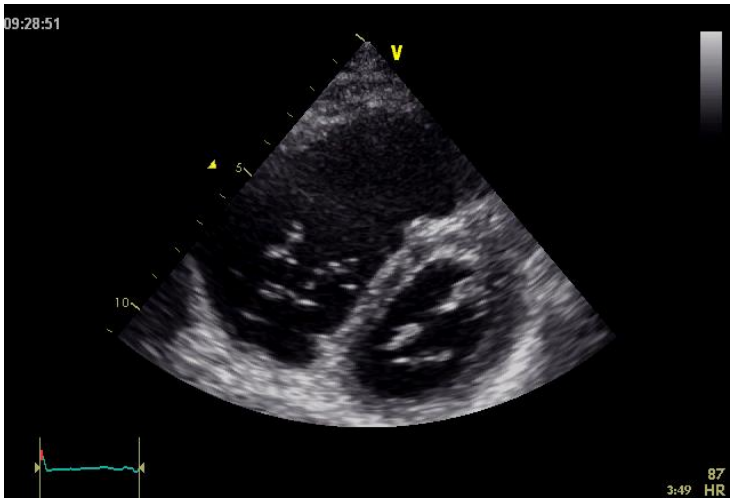

Paradoxical Septum – D-Diastole

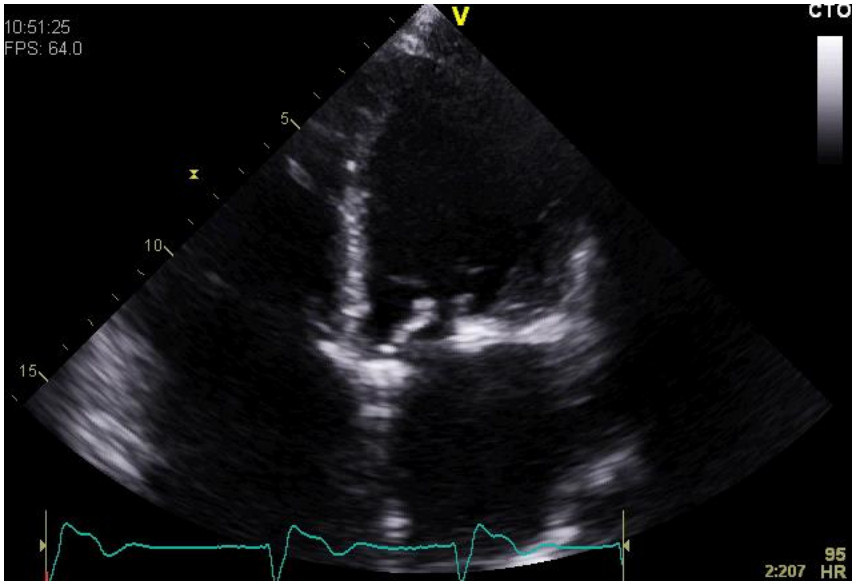

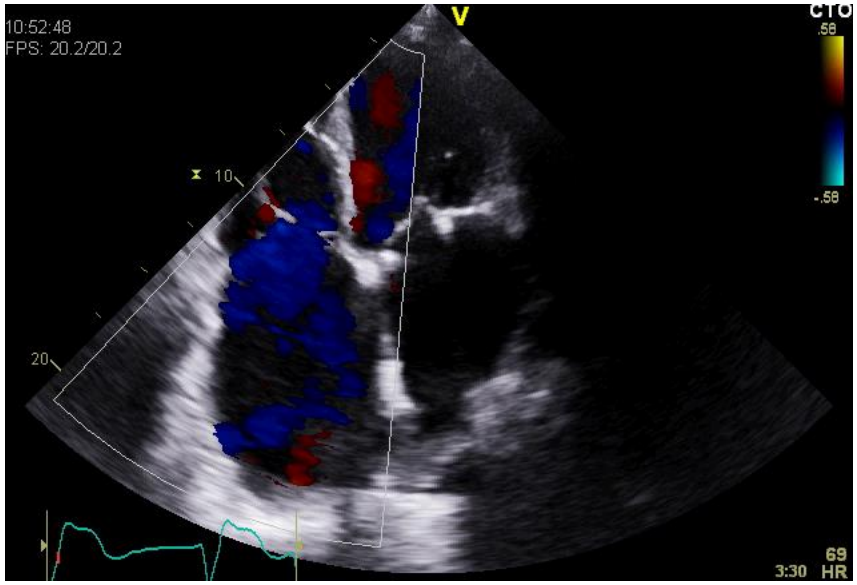

RA Size

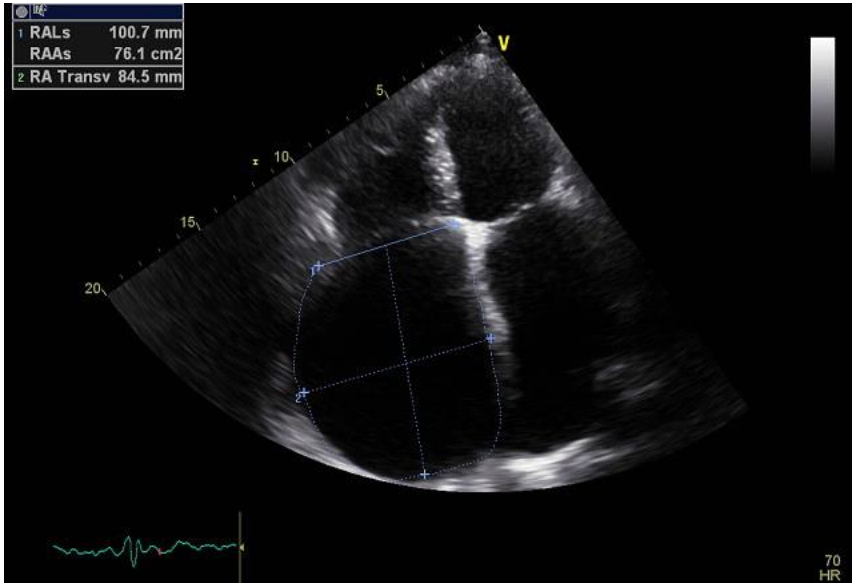
1 RALs 100.7 mm
RAAs 76.1 cm2
2 RA Transv 84.5 mm
V
5
10
15
20
70
HR

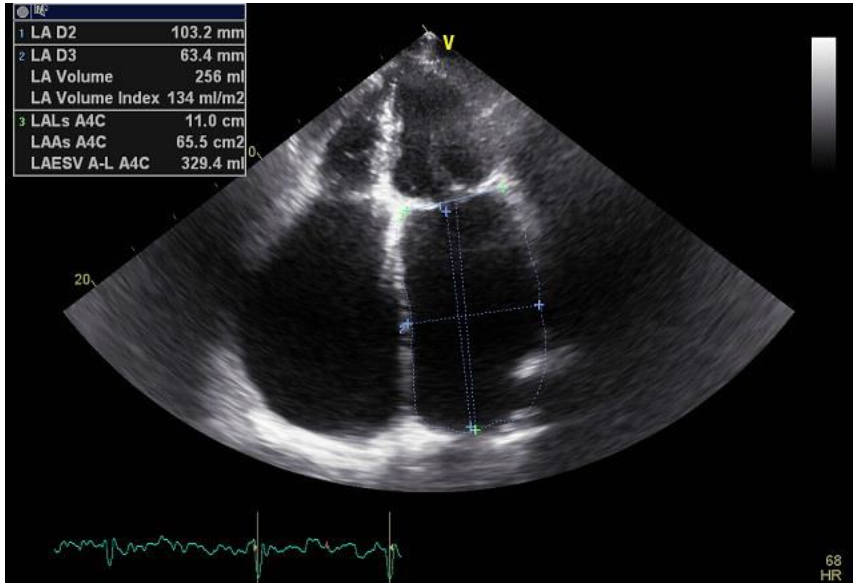
1 LA D2 103.2 mm
2 LA D3 63.4 mm
LA Volume 256 ml
LA Volume Index 134 ml/m2
3 LALs A4C 11.0 cm
LAAs A4C 65.5 cm2
LAESV A-L A4C 329.4 ml
V
20
68
HR

Parameter	Mild	Moderate	Severe
Tricuspid valve	Usually normal	Normal or abnormal	Abnormal/ flail leaflet/ poorcoaptation
RV/RA/IVC size	Normal	Normal or dilated	Usually dilated
Jet area-central jets (cm^2)*	<5	5-10	>10
VC width (cm)*	Not defined	< 0.7	> 0.7
PISA radius (cm)**	<0.5	0.6-0.9	>0.9 *
Jet density and contour-CW	Soft and parabolic	Dense, variable contour	Dense, triangular with early peaking
Hepatic vein flow	Systolic dominance	Systolic blunting	Systolic reversal

IVC - inferior vena cava; RA - right atrium; RV - right ventricle; VC - vena contracta width; PISA - Proximal isovelocity surface area. *At a Nyquist limit of 50-60 cm/s **Baseline shift with Nyquist limit of 28 cm/s. Adapted from: Masani N, Wharton G, Allen J, Chambers J, Graham J, Jones R, *et al.* Echocardiography: Guidelines for Valve Quantification. British Society of Echocardiography Education Committee. http://www.bsecho.org/Guidelines%20for%20Valve%20Quantification.pdf

Tricuspid Stenosis

Etiology

- Rheumatic
- Infiltration – Carcinoid
- Compression – Rare – external (clot/tumor)/aorta

TS Gradients and TV Area

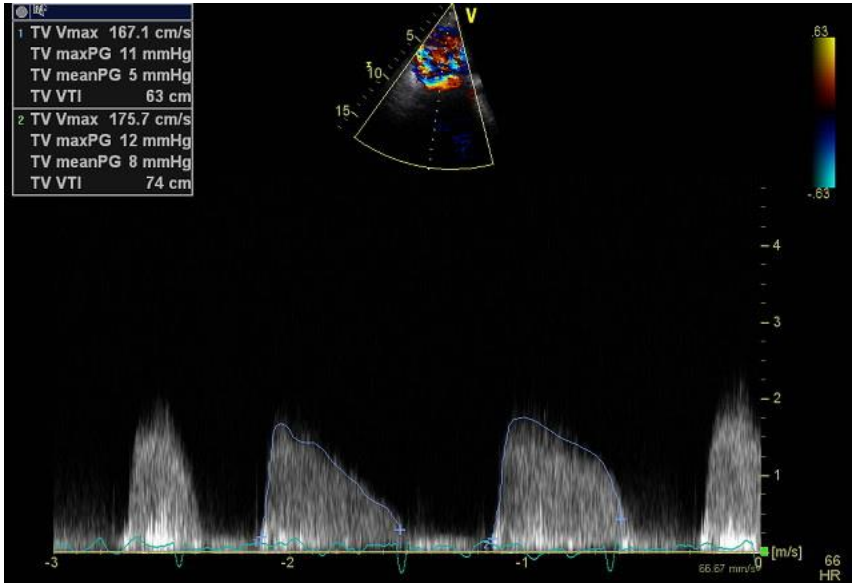

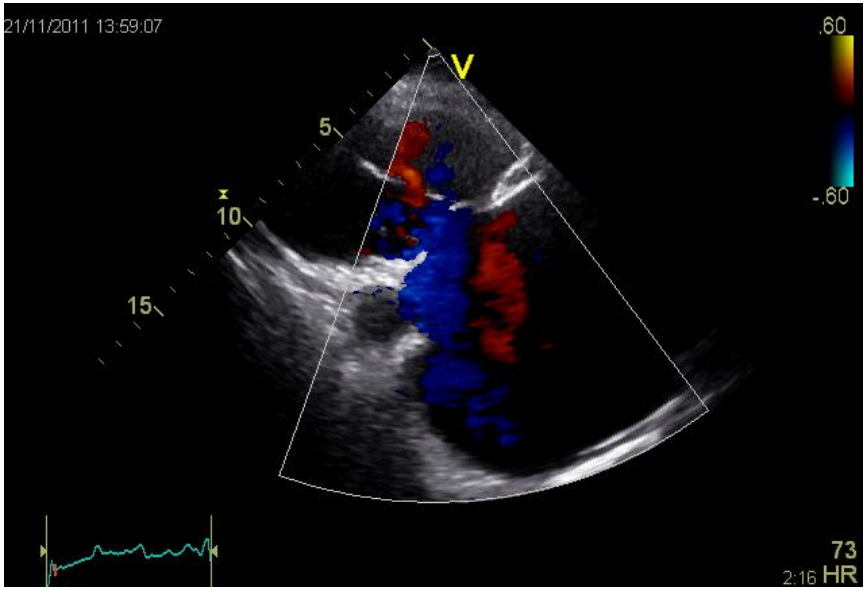

VTI 63-74 cm

- TVA cm^2 = 190/PHT

Calculation of TVA

$$A_2 = \frac{A_1 \cdot v_1}{v_2}$$

- A1 = LVOT CSA or RVOT CSA
- V1 = LVOT V1 or RVOT V1 (PW)
- V2 = Vmax of Tricuspid Inflow by CW Doppler

CW Doppler

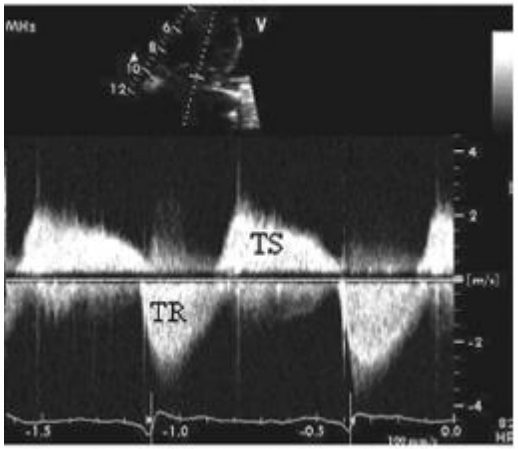

TVI = 60 cm; mean grad = 9 mmHg
$P1/2t$ = 173 ms

Table 10 Findings indicative of haemodynamically significant tricuspid stenosis

Specific findings	
Mean pressure gradient	≥5 mmHg
Inflow time–velocity integral	>60 cm
$T_{1/2}$	≥190 ms
Valve area by continuity equation[a]	≤1 cm^{2a}
Supportive findings	
Enlarged right atrium ≥moderate	
Dilated inferior vena cava	

[a]Stroke volume derived from left or right ventricular outflow. In the presence of more than mild TR, the derived valve area will be underestimated. Nevertheless, a value ≤1 cm^2 implies a significant haemodynamic burden imposed by the combined lesion.

Pulmonic Valve << Tricuspid Valve

- Stenosis – Valvar, Sub-, Supra
  - Congenital
  - Infiltrative
  - Iatrogenic – post Ross e.g.
- Regurgitation
  - PH
  - Congenital Surgery – Repaired Tetralogy
  - Endocarditis
  - Infiltrative

Normal PV

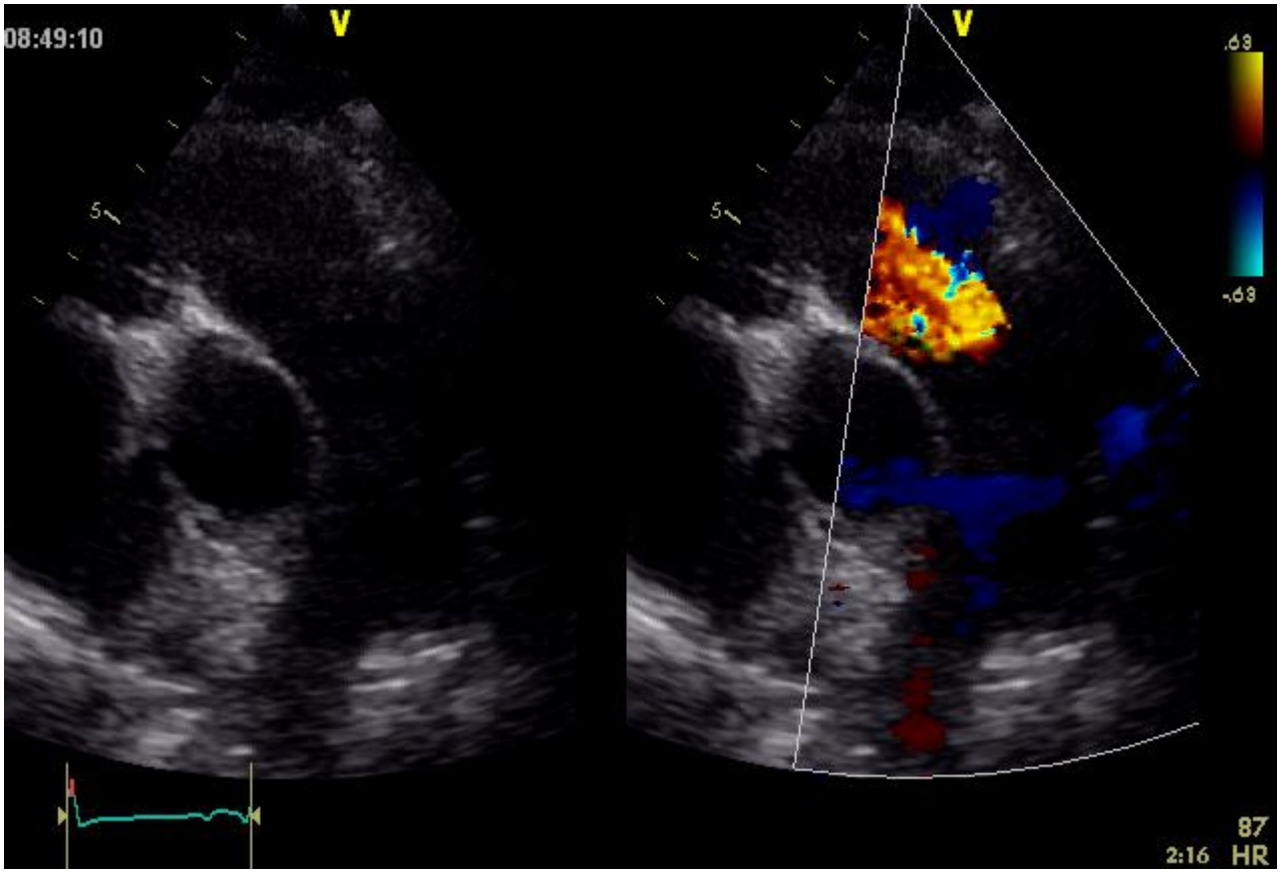

PS

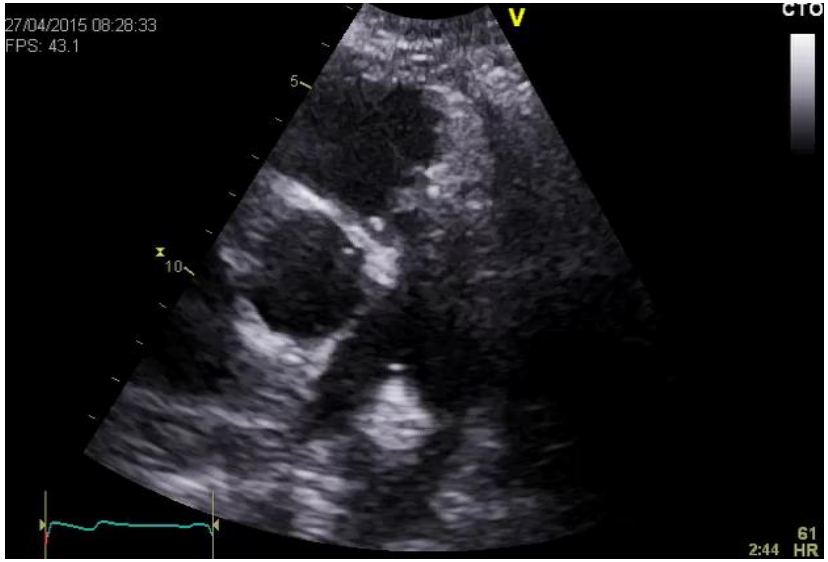
27/04/2015 08:28:33
FPS: 43.1
V
CTO
5
10
61
2:44
HR


27/04/2015 08:28:51
FPS: 53.0
V
CTO
5
10
63
2:53
HR

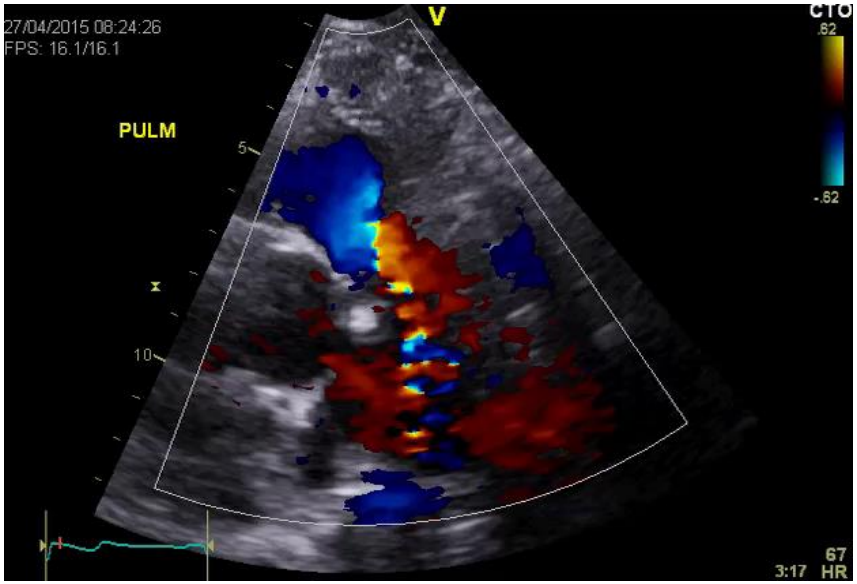
27/04/2015 08:24:26
FPS: 16.1/16.1
V
CTO
PULM
.62
-.62
5
10
67
3:17
HR

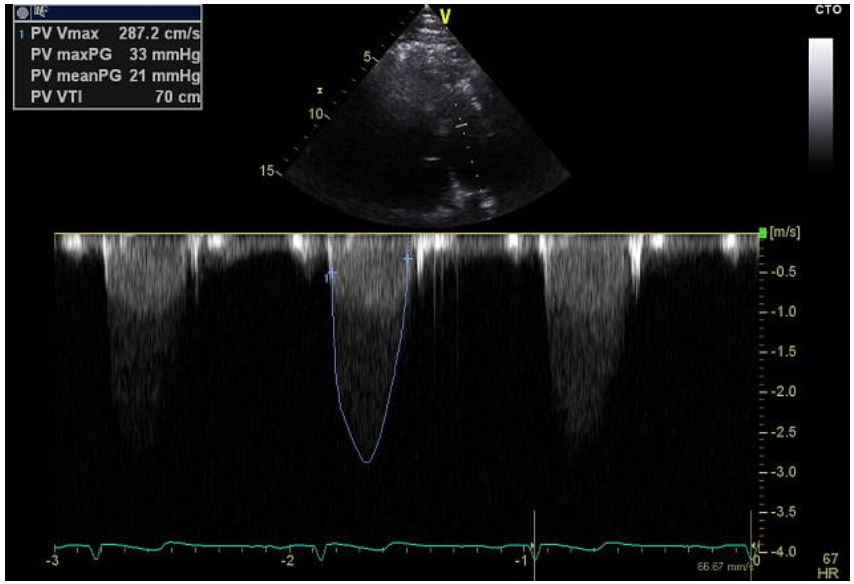
PV Vmax 287.2 cm/s
PV maxPG 33 mmHg
PV meanPG 21 mmHg
PV VTI 70 cm
V
CTO
5
10
15
[m/s]
-0.5
-1.0
-1.5
-2.0
-2.5
-3.0
-3.5
-4.0
-3
-2
-1
0
67
HR

Pulmonic Valve Disease-Carcinoid

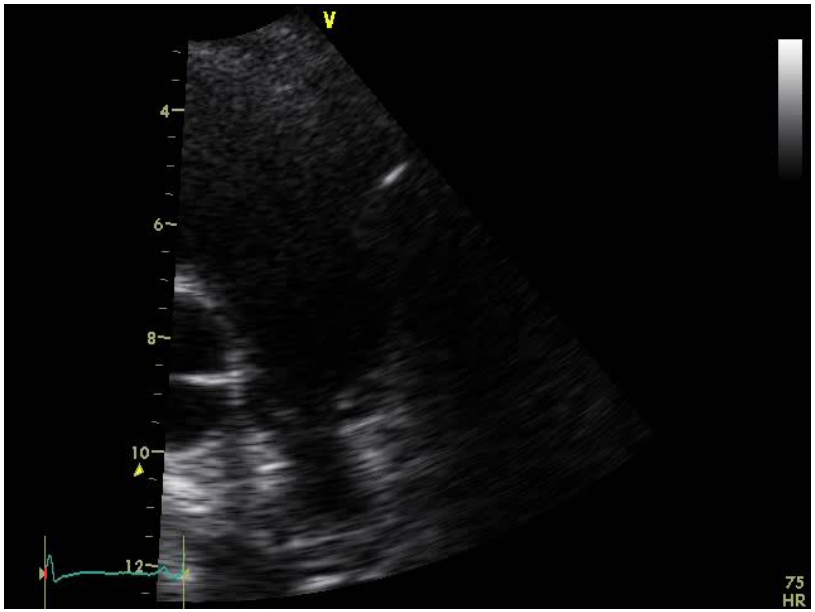

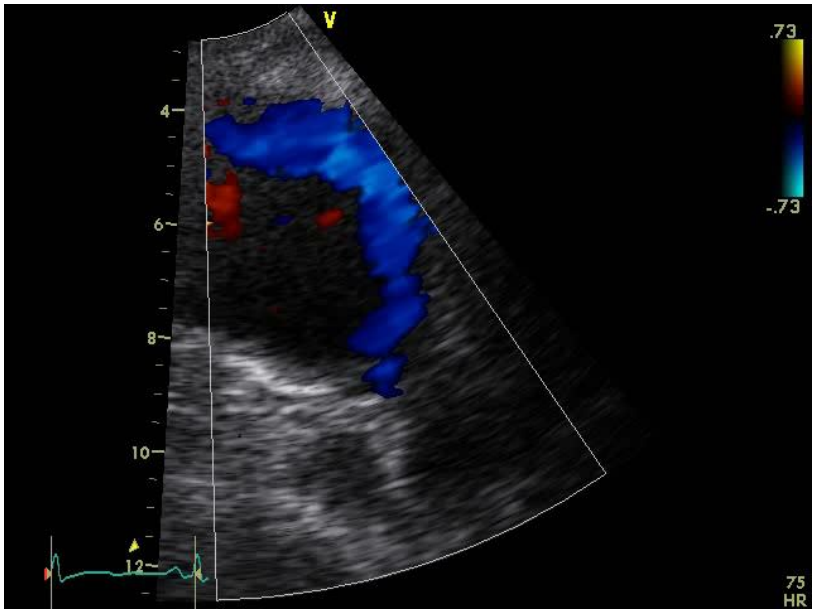

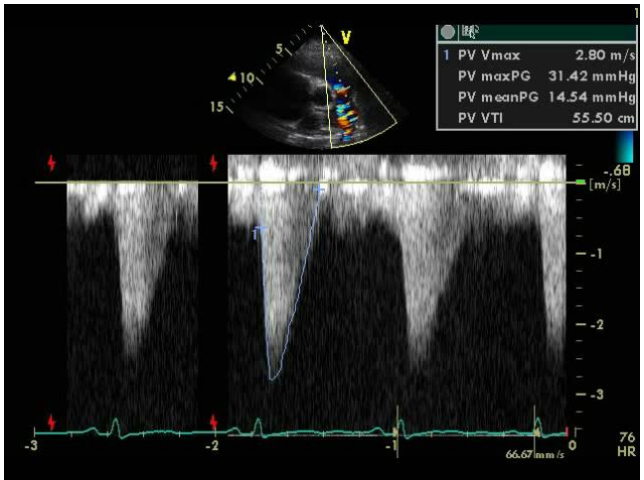

Table 11 Grading of pulmonary stenosis

	Mild	Moderate	Severe
Peak velocity (m/s)	<3	3–4	>4
Peak gradient (mmHg)	<36	36–64	>64

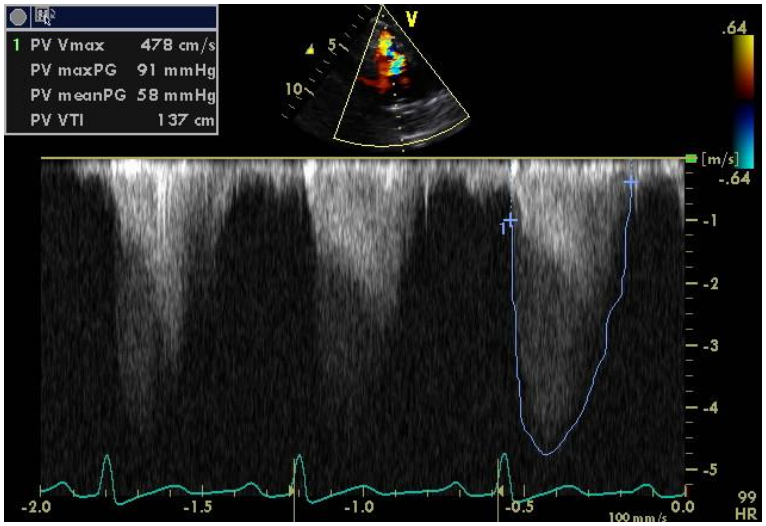

PR Severity

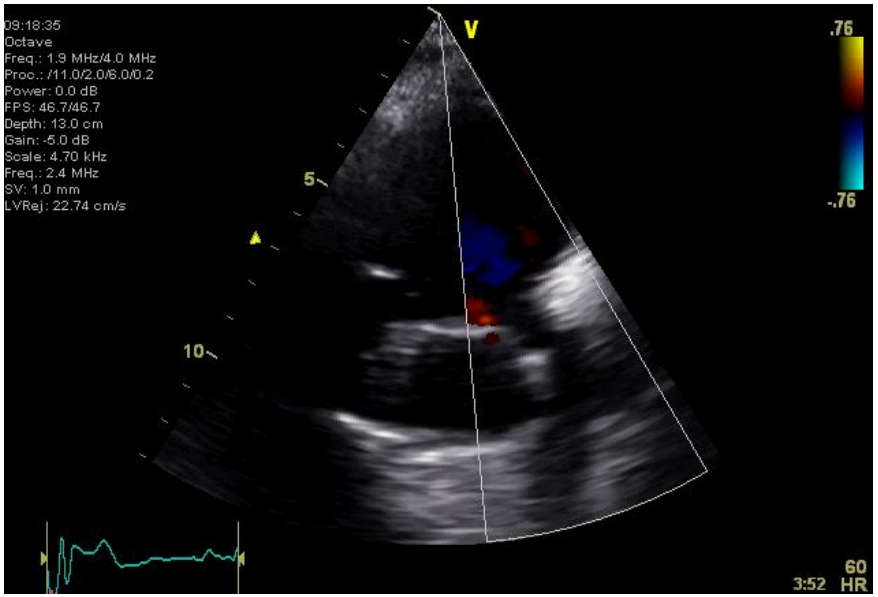
09:18:35
Octave
Freq.: 1.9 MHz/4.0 MHz
Proc.: /11.0/2.0/6.0/0.2
Power: 0.0 dB
FPS: 46.7/46.7
Depth: 13.0 cm
Gain: -5.0 dB
Scale: 4.70 kHz
Freq.: 2.4 MHz
SV: 1.0 mm
LVRej: 22.74 cm/s
V
.76
-.76
5
10
60
3:52 HR

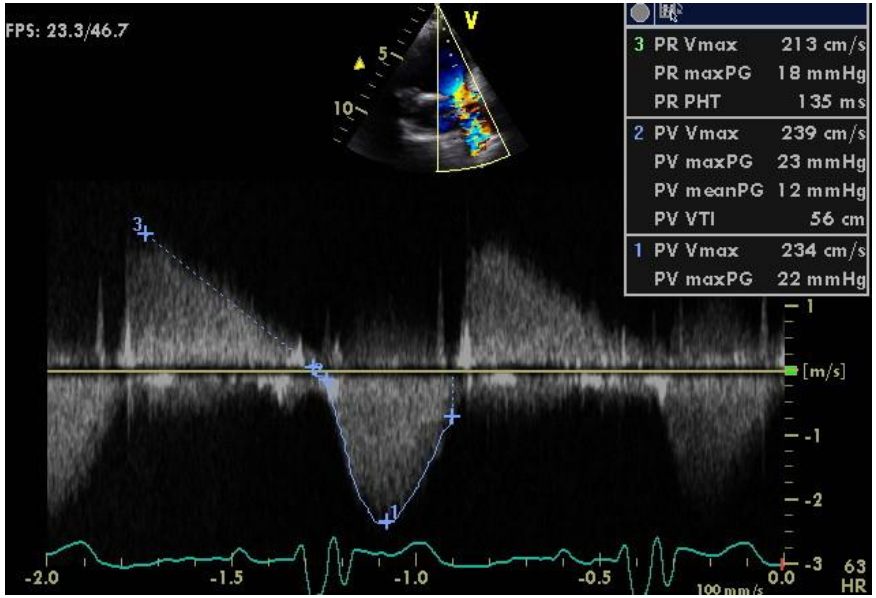
FPS: 23.3/46.7
V
3 PR Vmax 213 cm/s
PR maxPG 18 mmHg
PR PHT 135 ms
2 PV Vmax 239 cm/s
PV maxPG 23 mmHg
PV meanPG 12 mmHg
PV VTI 56 cm
1 PV Vmax 234 cm/s
PV maxPG 22 mmHg
[m/s]
1
-1
-2
-3
-2.0
-1.5
-1.0
-0.5
0.0
100 mm/s
63
HR

Table 9 Echocardiographic and Doppler parameters used in the evaluation of pulmonary regurgitation severity: Utility, advantages, and limitations

Parameter	Utility/Advantages	Disadvantages
RV size	RV enlargement sensitive for chronic significant PR. Normal size virtually excludes significant PR	Enlargement seen in other conditions.
Paradoxical septal motion (volume overload pattern)	Simple sign of severe PR	Not specific for PR
Jet length –Color flow	Simple	Poor correlation with severity of PR
Vena contracta width	Simple quantitative method that works well for other valves	More difficult to perform; requires good images of pulmonary valve; lacks published validation
Jet deceleration rate –CW	Simple	Steep deceleration not specific for severe PR
Flow quantitation –PW	Quantitates regurgitant flow and fraction	Subject to significant errors due to difficulties of measurement of pulmonic annulus and a dynamic RVOT; not well validated

CW, Continuous wave; *RV*, right ventricle; *PR*, pulmonic regurgitation; *RVOT*, right ventricular outflow tract.

Table 10 Echocardiographic and Doppler parameters used in grading pulmonary regurgitation severity

Parameter	Mild	Moderate	Severe
Pulmonic valve	Normal	Normal or abnormal	Abnormal
RV size	Normal*	Normal or dilated	Dilated
Jet size by color Doppler§	Thin (usually < 10 mm in length) with a narrow origin	Intermediate	Usually large, with a wide origin; May be brief in duration
Jet density and deceleration rate –CW†	Soft; Slow deceleration	Dense; variable deceleration	Dense; steep deceleration, early termination of diastolic flow
Pulmonic systolic flow compared to systemic flow –PW♀	Slightly increased	Intermediate	Greatly increased

CW, Continuous wave Doppler; *PR*, pulmonic regurgitation; *PW*, pulsed wave Doppler; *RA*, right atrium; *RF*, regurgitant fraction; *RV*, right ventricle.
* Unless there are other reasons for RV enlargement. Normal 2D measurements from the apical 4-chamber view; RV medio-lateral end-diastolic dimension ≤ 4.3 cm, RV end-diastolic area ≤ 35.5 cm^2(89).
** Exception: acute PR
§ At a Nyquist limit of 50-60 cm/s.
♀ Cut-off values for regurgitant volume and fraction are not well validated.
† Steep deceleration is not specific for severe PR.

Not many numbers
RV enlargement with PR jet and not much else
Very broad vena contracta
Short PHT

Impact

- Same as for TR
  - Assess RV size, RA size, RV function

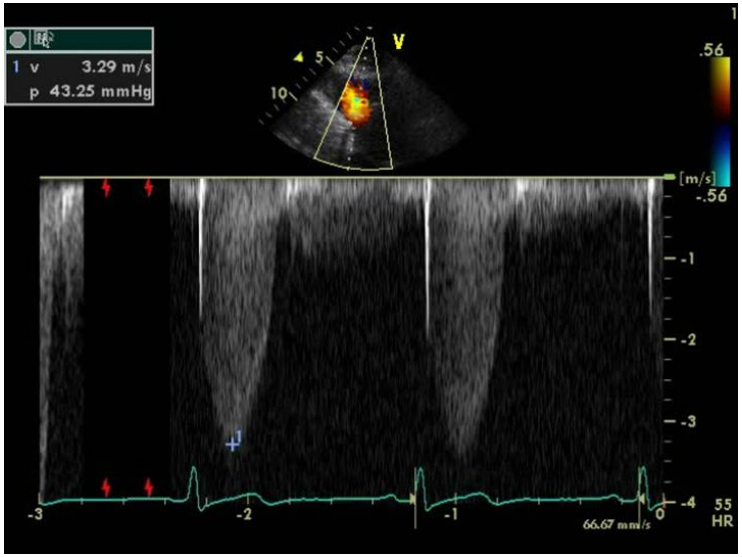

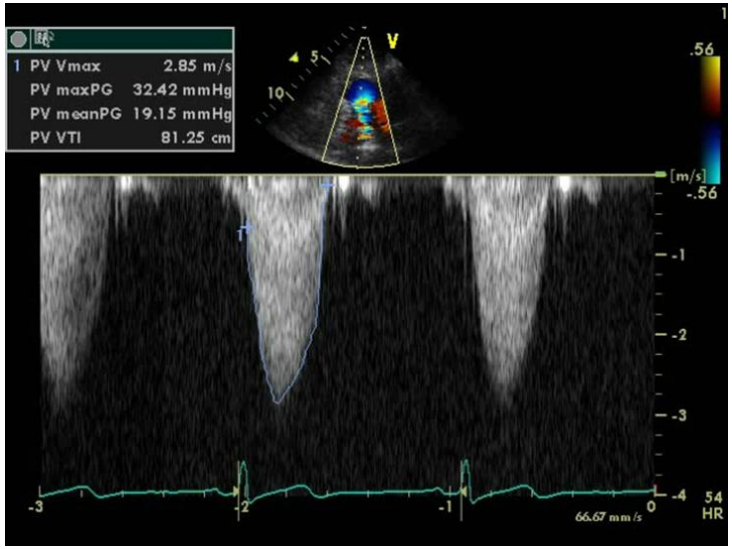

  - PAP Calculation Caveat – Subtract the PS Gradient**
  - SPAP = (TR gradient + RAP) – PV PG

    = (43 + 15) – 32 = 26 mmHg

Summary

More than eyeball of color jet

- Tricuspid
  - Morphology, Degree of dysfunction, Impact on cardiac size and function
- Pulmonic
  - Same as above
- Implications for Clinical therapy
  - When to intervene in primary and secondary TR, PR
  - When to intervene for TS and PS

CMR – So 1990's

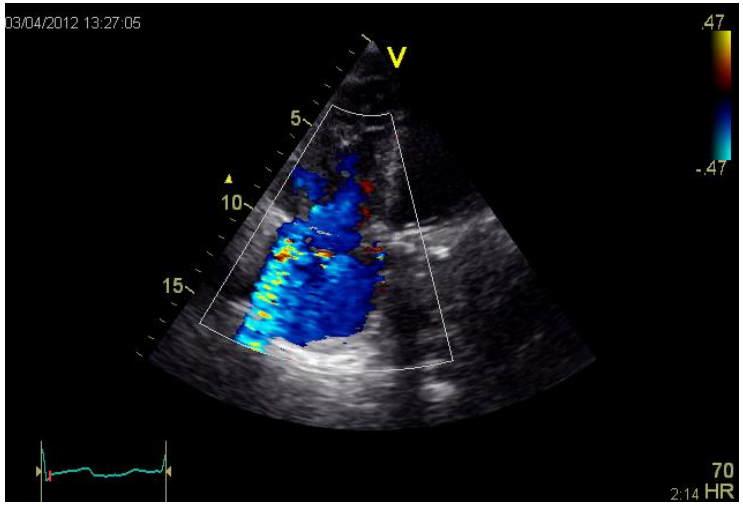

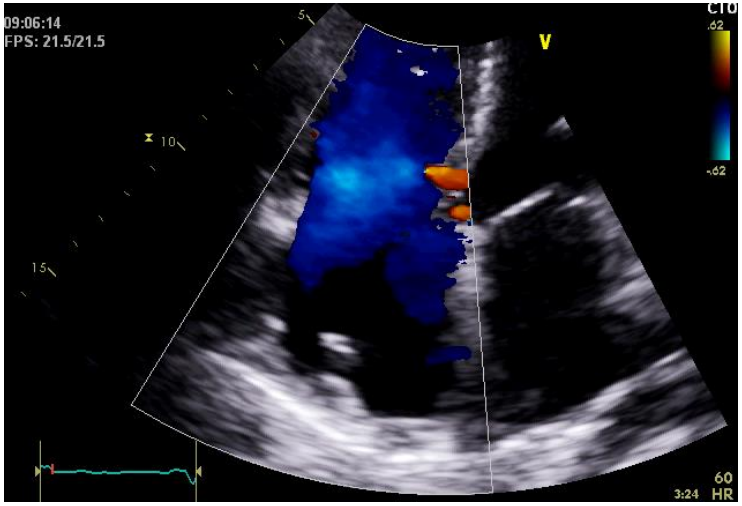

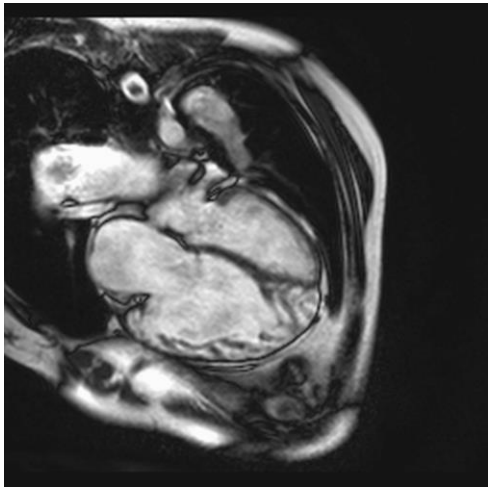

MRI

Echo

Watch RAP !

Echo, echocardiography; RAP, right atrial pressure; TR, tricuspid regurgitation.

Images can be deceptive! – Integrate detail with the BIG PICTURE

Question 1

- All of the following are compatible with severe Tricuspid Regurgitation except:
- A RV basal dimension measuring 50mm
- B Flow reversal in the hepatic veins after the P wave
- C PISA radius of 10 mm at an aliasing velocity of 30 cm/s
- D Non-parabolic TR CW Doppler signal with an early peak

Answer - B

- The flow reversal representing severe TR is after the QRS – i.e. in systole

Question 2

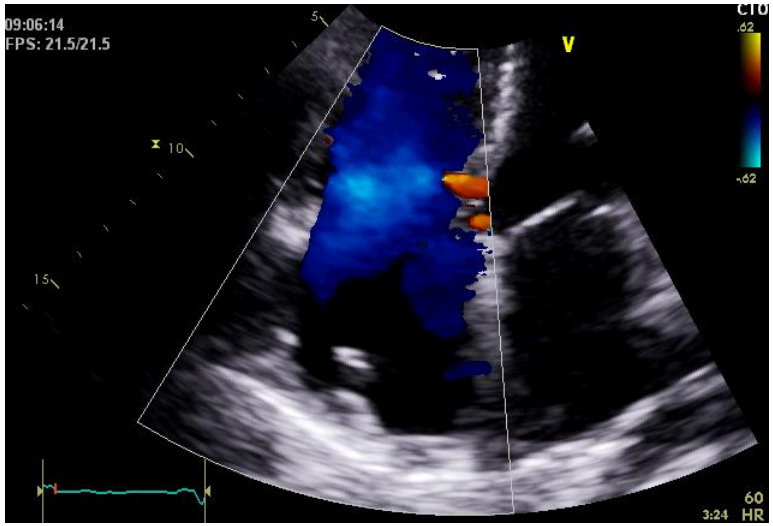

All of the following are true except:

A) The simplified Bernoulli equation is not valid

B) The septum is D-shaped in diastole

C) The PAP may be overestimated due to the presence of laminar flow

D) The RA pressure is likely > 15 mmHg

Answer - C

- Laminar flow is likely to underestimate severity of TR. The Simplified Bernoulli equation is predicated on turbulent flow

Question 3

Which of the following is least likely

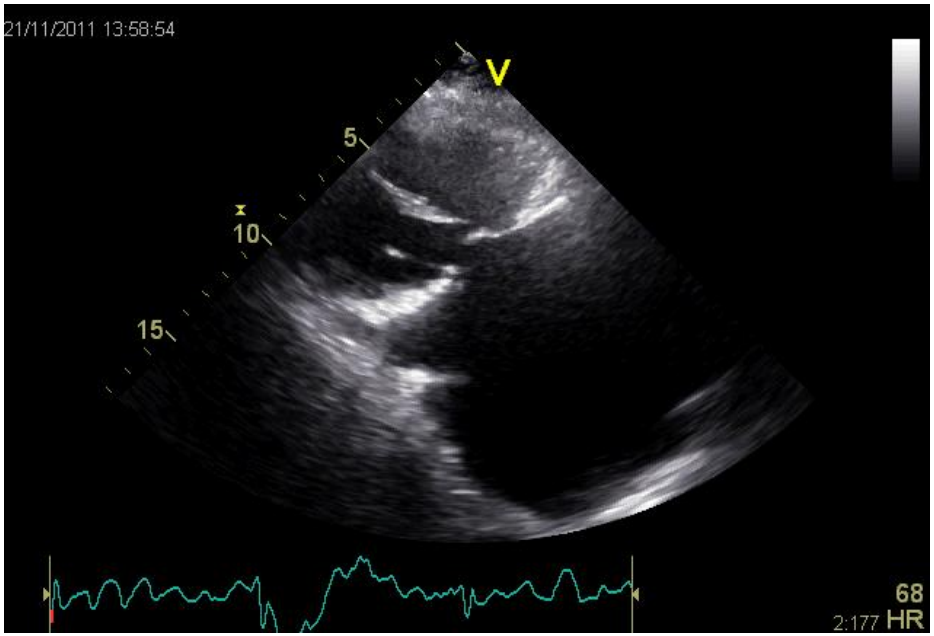

- A) A diastolic rumble will be heard over the apex
- B) The IVC will be markedly dilated
- C) Mitral inflow pulsed Doppler will demonstrate E:A reversal
- D) The RV systolic pressure will be significantly elevated

Answer - C

- This patient has rheumatic TS, and therefore likely also has rheumatic mitral valve disease
- There is severe RA enlargement and therefore likely marked elevation of RA pressure
- The patient is in atrial fibrillation, so there will not be much of an A wave present