

EXPEDITED PUBLICATION

Impact of Contrast Echocardiography on Evaluation of Ventricular Function and Clinical Management in a Large Prospective Cohort

Mustafa Kurt, MD, Kamran A. Shaikh, MD, Leif Peterson, PhD, Karla M. Kurrelmeyer, MD, FACC, Gopi Shah, MD, FACC, Sherif F. Nagueh, MD, FACC, Robert Fromm, MD, Miguel A. Quinones, MD, FACC, William A. Zoghbi, MD, FACC

Houston, Texas

Objectives	The aim of this study was to evaluate the impact of echocardiographic contrast utilization on patient diagnosis and management.
Background	Contrast echocardiography (CE) has improved visualization of endocardial borders. However, its impact on patient management has not been evaluated previously.
Methods	We prospectively enrolled 632 consecutive patients with technically difficult echocardiographic studies who received intravenous contrast (Definity, Lantheus Medical Imaging, Billerica, Massachusetts). Quality of studies, number of left ventricular (LV) segments visualized, estimated ejection fraction, presence of apical thrombus, and management decisions were compared before and after contrast.
Results	After CE, the percent of uninterpretable studies decreased from 11.7% to 0.3% and technically difficult studies decreased from 86.7% to 9.8% ($p < 0.0001$). Before contrast, 11.6 ± 3.3 of 17 LV segments were seen, which improved after CE to 16.8 ± 1.1 ($p < 0.0001$). An LV thrombus was suspected in 35 patients and was definite in 3 patients before CE. After contrast, only 1 patient had a suspected thrombus, and 5 additional patients with thrombus were identified ($p < 0.0001$). A significant impact of CE on management was observed: additional diagnostic procedures were avoided in 32.8% of patients and drug management was altered in 10.4%, with a total impact (procedures avoided, change in drugs, or both) observed in 35.6% of patients. The impact of contrast increased with worsening quality of nonenhanced study, the highest being in intensive care units. A cost-benefit analysis showed a significant savings using contrast (\$122/patient).
Conclusions	The utilization of CE in technically difficult cases improves endocardial visualization and impacts cardiac diagnosis, resource utilization, and patient management. (J Am Coll Cardiol 2009;53:802-10) © 2009 by the American College of Cardiology Foundation

In the last decade, contrast echocardiography (CE) media have rapidly evolved and are now widely used clinically to optimize ultrasound image quality. Several studies have shown that CE improves the assessment of global and regional left ventricular (LV) function, enhances the detection of LV thrombi, and decreases variability of interpretation (1-13). It has been estimated that 10% to 15% of routine echocardiograms have incomplete endocardial resolution, reaching 25% to 30% in critically ill patients in the intensive care unit (ICU) (14).

Although there is a wealth of information regarding the benefit of CE with regard to improving image quality and assessment of LV function, there are limited published data regarding the impact of contrast agents on patient management. The present study was therefore designed to prospectively evaluate the impact of contrast use on cardiac diagnosis and management compared with noncontrast studies in a large cohort of consecutive patients who have undergone both unenhanced and contrast-enhanced echocardiograms as part of routine care.

Methods

Patient population. We prospectively enrolled consecutive patients with technically difficult studies who underwent a rest echocardiogram and received echocardiographic contrast for image enhancement at the Methodist DeBakey

From the Department of Cardiology, The Methodist Hospital, and The Methodist DeBakey Heart and Vascular Center Imaging Institute, Houston, Texas. This study was presented in part at the 57th Annual Scientific Sessions of the American College of Cardiology, March 31, 2008, Chicago, Illinois.

Manuscript received September 18, 2008; revised manuscript received January 6, 2009, accepted January 12, 2009.

Heart and Vascular Center from June 2007 to October 2007. The stop date represented the release of the Federal Drug Administration warning on the use of echocardiographic contrast (15). The study was approved by the Institutional Review Board of the Methodist Hospital Research Institute. A total of 65 primary physicians were involved in the care of the cohort of patients, and all physicians gave permission to review their patients' medical records. All patients who had received contrast during routine echocardiograms in the time frame of this study were included, with no patient drop-out. Studies on myocardial perfusion and stress echocardiography with contrast are not included in this report.

Unenhanced and contrast-enhanced echocardiographic studies. Before performing the echocardiography study, baseline clinical characteristics were recorded. A complete 2-dimensional and Doppler echocardiographic study was then performed using standardized protocols from the parasternal and apical windows (Sonos 5500/7500, Philips Medical Systems, Bothell, Washington; and Vivid 7, General Electric Medical Systems, Milwaukee, Wisconsin). Baseline images were obtained using second harmonic imaging and high mechanical index (1.0 to 1.5), with other settings tailored to optimize image quality.

If the echocardiography study was deemed technically difficult by the sonographer, contrast was given according to the American Society of Echocardiography guidelines (16,17). The contrast agent used was Definity (Lantheus Medical Imaging, Billerica, Massachusetts) as follows: 1.5 ml of activated Definity was diluted in 8.5 ml of saline (total solution of 10 ml), and administered in 1- to 2-ml boluses followed by a saline flush as needed to optimize image quality. The CE images were obtained using a mechanical index between 0.3 and 0.5. The contrast images were appended at the end of the noncontrast study, and all images were stored on a central server and interpreted within a few hours on an off-line workstation (Digiview 6.0, Digisonics, Houston, Texas).

Image interpretation. The noncontrast-enhanced images were interpreted first by one observer, followed by interpretation of the contrast-enhanced images and full study by another independent observer. The observers who were the assigned readers on the day of the studies were from a pool of 6 experienced echocardiographers. Both sets of images were interpreted independently by the 2 observers with special attention to: 1) the number of LV segments visualized (normal vs. abnormal wall motion); 2) estimating left ventricular ejection fraction (LVEF); 3) the suspicion or presence of an LV thrombus; and 4) image quality. Image quality was scored as: 1 = adequate; 2 = technically difficult; and 3 = uninterpretable. A technically difficult study was defined as a study in which >2 myocardial segments were not visualized at baseline from any imaging window. An uninterpretable study was defined as a study in which >50% of the endocardium was not visualized from any window and no reliable information regarding LVEF

could be reported. The LVEF was estimated, when feasible, in incremental ranges of 5% (e.g., 35% to 39%, 40% to 45%, and so on) between 20% and 70%, and as <20% and >70% when it exceeded this range. Regional LV function was assessed using the 17-segment model (16). The number of segments with normal and abnormal wall motion adequately visualized was noted. An assessment of presence, absence, or suspicion of apical thrombus was also determined.

Assessment of impact of contrast on clinical management.

After the separate interpretations of the noncontrast and full study with contrast were performed, the 2 interpretations were compared. Immediately afterward, and before electronically finalizing the report, the primary physician was contacted and given the echocardiographic results without contrast, and was asked about his or her management plan. Specifically, each physician was asked a set of questions by the same individual (M.K.) regarding whether he or she planned to order any more cardiac diagnostic tests (e.g., transesophageal echocardiography [TEE], radionuclide ventriculogram, stress testing, or coronary angiography) and/or alter the patient's cardiovascular medication regimen. The results of CE images were then revealed and the primary physician was then asked by the same individual (M.K.) how these results would alter the initial management plan, if any. Cardiovascular management impact focused on initiation or discontinuation of hemodynamically active drugs (diuretics, intravenous fluids, inotropic agents, vasodilators, and so on), anticoagulation therapy, and/or the need for further diagnostic studies such as TEE, radionuclide imaging, stress testing, or coronary angiography. The management plan identified was checked with the subsequent hospital record. If other tests were performed, the results of ventricular function were compared with those of the echocardiographic study.

The above protocol approach and timing of the contact with the referring physician was done so that: 1) the referring physician had no access to the final report and diagnosis before we asked about impact on management; 2) each patient could serve as his/her own control, thus allowing evaluation of contrast impact; and 3) this approach did not hinder routine patient care because the final report was available soon after contact with the physician was established.

Assessment of safety. The contrast study, although prospective, did not include a prospective assessment of safety, because it was initiated and conducted before the U.S. Food and Drug Administration warning. To assess safety of contrast in this population, which included many patients with later contraindications to contrast use by the U.S. Food and Drug Administration (the majority were changed sub-

Abbreviations and Acronyms

- CE** = contrast echocardiography
- ICU** = intensive care unit
- LV** = left ventricle/ventricular
- LVEF** = left ventricular ejection fraction
- MICU** = medical intensive care unit
- SICU** = surgical intensive care unit
- TEE** = transesophageal echocardiogram/echocardiography

sequently to warnings), electronic hospital records were reviewed for all inpatients and a telephone call was given for the outpatients. The safety end points sought were any significant hypotension noted in the nurses' notes, the occurrence of an anaphylactoid reaction, new chest pain, acute myocardial infarction, cardiac arrhythmia requiring intervention, cardiac arrest, or death within the ensuing 24 h after contrast administration.

Cost-benefit and resource utilization patterns. For estimating the economic impact, the national average of the Medicare-allowable charges for cardiovascular testing for 2008 was used. Using the Medicare fee schedule (18), the total median global charges reimbursed by Medicare were: \$62.00 for echocardiographic contrast, \$490.18 for a TEE, \$426.30 for a resting radionuclide-gated ventriculogram, and \$847.20 for a radionuclide stress test. A cost-benefit analysis was performed using the cost of using echocardiographic contrast over the cost of procedures that would have been performed, had contrast not been used. Furthermore, a cost-effectiveness analysis also was performed using the cost of contrast over the number of procedures avoided.

Statistical analysis. Summary statistics for demographic variables are presented as mean ± SD for continuous

variables and count (%) for categorical variables. Separate McNemar tests were used to determine significantly different pre- and post-contrast proportions of subjects (summed over subgroups by locations) with uninterpretable and adequate scans (Fig. 1). Wilcoxon signed rank tests were used to test for significant differences in averages of pre- and post-contrast per-subject visualized segments and per-subject abnormal visualized segments (Fig. 2). We also tested the effects of contrast enhancement on detection of LV thrombi, for which we used the McNemar test.

Separate 1-sample tests of proportions ($H_0: p = 0$) were used for determining whether the fraction of patients having a positive impact for procedural change, medication change, or both was significantly different from zero. Two-sample tests of proportions were used to determine whether the proportion of patients having a positive impact (for procedural change, medication change, or both) were different across patient subgroups. Contingency table analysis (chi-square test) was used for testing heterogeneity among frequencies of positive impact (yes/no) versus frequency of nonvisualized segments before contrast partitioned into categories based on the cut points 0 to 1, 2 to 6, 7 to 11, and >12 segments.

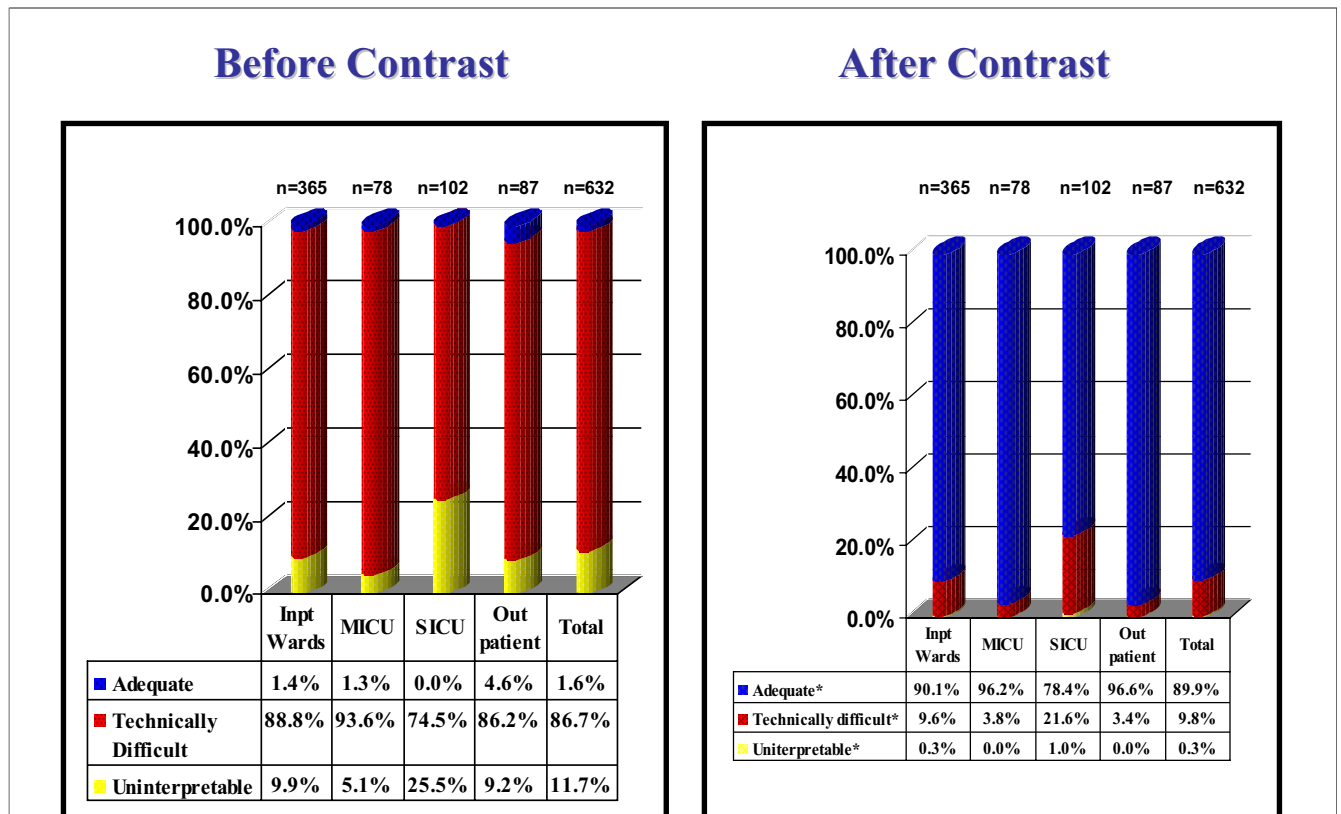


Figure 1. Impact of Contrast on Quality of Study

A significant increase in quality of echocardiograms is seen after contrast use across all locations. *p < 0.0001 comparing quality before and after contrast for total and all subgroups. Inpt = inpatient; MICU = medical intensive care unit; SICU = surgical intensive care unit.

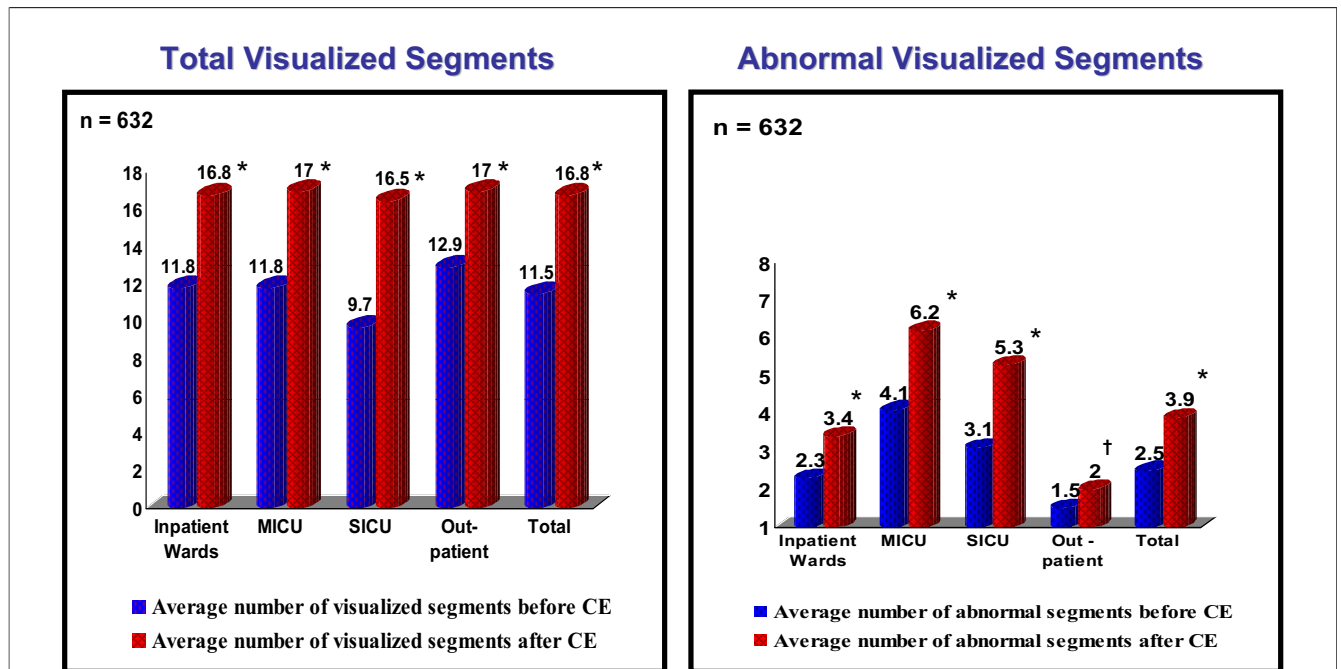


Figure 2 Impact of Contrast on Segments Visualized Per Patient

After contrast, a significant increase in visualization of total number of segments and of abnormal segments was observed. * $p < 0.0001$ comparing number of segments visualized before and after contrast. † $p = 0.0016$ comparing number of segments visualized before and after contrast. CE = contrast echocardiography; other abbreviations as in Figure 1.

Results

Patient characteristics. A total of 632 consecutive patients with technically difficult studies who underwent CE for endocardial enhancement constituted the study population. No patients were excluded from analysis. All management decisions conformed to the response of the physicians and were verified by chart review. The cohort comprised 14.5% of the total routine transthoracic echocardiograms performed during the study period (4,362 total studies). Con-

trast utilization was 19% in all inpatients (545 of 2,857 examinations), with 18.2% in the inpatient wards (365 of 2,005 examinations) and 21.1% in the ICUs (180 of 852 examinations), and 5.8% in outpatients (87 of 1,505 of examinations).

Baseline patient characteristics are listed in Table 1. The majority of patients were inpatients (86.2%), with 28.4% residing in the ICUs (180 of 632 of examinations). The clinical indications for the echocardiographic studies that required contrast are shown in Table 2. The majority of indications were for heart failure and for evaluation of chest pain, coronary artery disease, or acute coronary syndromes, collectively accounting for 362 (59%) of the total studies.

Impact of contrast on the overall quality of the echocardiographic studies. Before CE, 548 studies (86.7%) were technically difficult and a total of 74 studies (11.7%) were

Table 1 Patient Characteristics

Parameter	Value
N	632
Age (yrs)	63.6 ± 14
Male	396 (62.7%)
Body surface area (m ²)	2.09 ± 0.28
Past medical history	
Hypertension	416 (65.8%)
Diabetes mellitus	192 (30.4%)
Coronary artery disease	243 (38.4%)
Chronic obstructive pulmonary disease	72 (11.4%)
Location	
Inpatients	545 (86.2%)
Wards	365 (57.8%)
Surgical intensive care units	102 (16.1%)
Medical intensive care units	78 (12.3%)
Outpatients	87 (13.8%)

Data are reported as mean ± SD or n (%).

Table 2 Indications for Rest Echocardiograms Who Required Contrast Enhancement

Clinical Indication	n (%)
Congestive heart failure	190 (30.1)
Chest pain/acute coronary syndrome	111 (17.6)
Coronary artery disease	71 (11.2)
Valvular assessment	61 (9.7)
Hypertension	57 (9)
Pericardial effusion	28 (4.4)
Stroke	27 (4.3)
Other	87 (13.7)

deemed uninterpretable (Fig. 1). After review by the observers, 10 studies (1.6%) were considered adequate before contrast to make a reliable assessment of LV function. The largest group of uninterpretable studies was seen in the surgical intensive care unit (SICU), comprising almost 26% of that group. After CE, the percent of uninterpretable studies decreased from 11.7% to 0.3% and technically difficult studies decreased from 86.7% to 9.8%, with a resultant increase in adequate studies from 1.6% to 89.9% (McNemar, all $p < 0.0001$). The greatest degree of improvement in quality was seen in the SICU cohort. Thus, overall, there was a salvage of 558 studies (88.3%) from technically difficult or uninterpretable studies to adequate studies.

Effect of contrast on interpretation of regional and global ventricular function. The total number of segments visualized before contrast was 7,358 segments, equating to an average of 11.6 segments per patient or 68% of the LV myocardium. The lowest average number of segments visualized was seen in the SICU and the highest in the outpatient group (Fig. 2). After contrast administration, the total number of segments visualized increased to 10,617 segments, equating to 16.8 segments per patient or 98.8% of the LV myocardium (Wilcoxon, $p < 0.0001$). Again, the largest degree of improvement was seen in the SICU.

The effect of contrast on the extent of abnormal wall motion is also shown in Figure 2. The total number of abnormal segments visualized increased after CE from 2.54 ± 4.8 segments to 3.87 ± 6.5 segments (Wilcoxon, $p < 0.0001$). This increase was seen in all patient subgroups, but was most pronounced in the ICUs, where patients also had the greatest extent of wall motion abnormality (Wilcoxon, $p < 0.0001$) (Fig. 2). New wall motion abnormalities visualized after CE, and not present on the unenhanced study were detected in 156 patients (28% of studies), excluding studies initially classified as uninterpretable ($H_0: p = 0, p < 0.0001$). Conversely, wall motion

abnormality interpreted in the unenhanced study that no longer was present after contrast was seen in 5 patients (0.9% of studies).

The addition of contrast also had a significant effect on the assessment of LVEF (Fig. 3). Interpretation of CE images produced a change in ejection fraction (defined as an absolute difference between interpretations of $\geq 10\%$ based on previous studies of reproducibility), in a total of 93 (16.7%) patients. The vast majority of these were underestimations of LVEF on the unenhanced contrast images (88 studies or 94.5%). If uninterpretable studies were also included, the SICU had the greatest portion of patients with a change in LVEF after CE (36 patients or 35.3%) and the outpatient group had the lowest (12 patients or 13.7%).

Effect of contrast on diagnosis of LV thrombus. Before contrast administration, 35 patients were suspected to have an apical thrombus, whereas 3 patients were thought to definitely have a thrombus. After contrast enhancement, an apical thrombus was diagnosed in 5 more patients and excluded in all others except 1 patient in whom thrombus was still suspected but could not be confirmed. Thus, the number of suspected thrombi decreased from 35 patients to only 1 patient after contrast utilization (McNemar, $p < 0.0001$).

Impact of contrast on patient management. DIAGNOSTIC PROCEDURES. Based on the response of the treating physicians, contrast led to avoidance of further diagnostic procedures in 207 patients (32.8%) because of improved assessment of LV function ($H_0: p = 0, p < 0.0001$) (Fig. 4). The avoided procedures were either a TEE (67 patients, 32.4%) or a nuclear imaging study (140 patients or 67.7%: resting gated studies in 84 and stress nuclear in 56), both of which were originally planned to better assess LV function. A total of 56 patients (55%) in the SICU group had a procedure avoided, whereas 114 patients (31%) and 26 patients (33%) had procedures avoided in the inpatient ward and medical intensive care unit (MICU) groups, respectively. The SICU group had a greater degree of procedures avoided relative to the inpatient ward and outpatient groups ($H_0: p_1 = p_2, p < 0.0001$ for both).

From the cohort of 632 patients, 86 patients ultimately underwent coronary angiography, 36 had stress nuclear imaging, and 3 had CT angiography for evaluation of coronary artery disease. All of these patients had the additional procedures to evaluate for ischemia or coronary artery disease based on an abnormal echocardiogram. Fifty-eight of the 86 patients (67%) underwent the further testing because of CE: images were previously uninterpretable and subsequently showed LV dysfunction ($n = 22$ patients) or new wall motion abnormalities were noted ($n = 36$ patients). The LVEF after CE was within 5% of LVEF by the other modalities in 113 of 125 patients (90.4%), within 10% in 10 patients (8%), and discordant by $>10\%$ in 2 patients (1.6%).

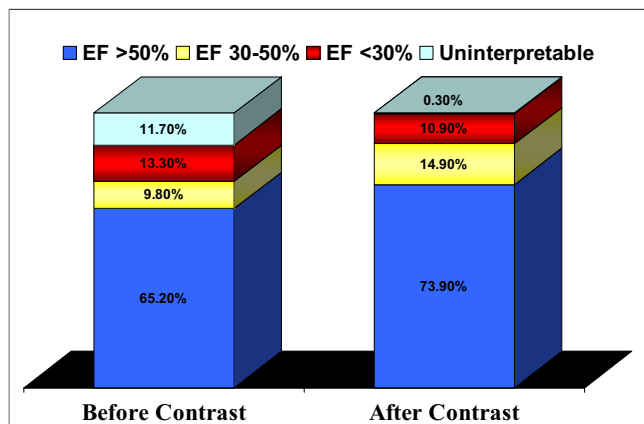


Figure 3 Impact of Contrast on Left Ventricular EF Assessment

After contrast, a significant decrease in the number of uninterpretable studies was seen, with overall higher left ventricular ejection fraction (EF).

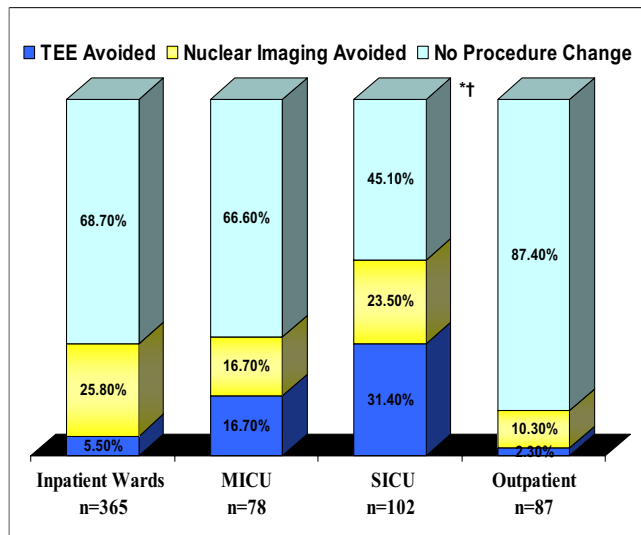


Figure 4 Impact of Contrast on Additional Planned Diagnostic Procedures

The use of contrast avoided further planned diagnostic procedures, the highest observed in the SICU setting. * $p < 0.0001$ comparing SICU with inpatients. † $p < 0.0001$ comparing SICU with outpatients. TEE = transesophageal echocardiogram; other abbreviations as in Figure 1.

DRUG MANAGEMENT. The patients' medical regimen was altered in 67 patients (10.6%) after interpretation of CE images ($H_0: p = 0, p < 0.0001$) (Fig. 5). Specifically, the change in medical regimen included the addition or discontinuation of hemodynamically active drugs (i.e., diuretics, vasopressors, inotropes, intravenous fluids, and vasodilators) and the addition or cessation of anticoagulation after confirmation or exclusion of an LV thrombus. Twenty-six patients in the SICU (25.5%), 34 patients in inpatient wards (9.3%), and 7 patients in the MICU (8.9%) had such medication changes. The largest impact was seen in the SICU relative to the inpatient, MICU, and outpatient groups ($H_0: p_1 = p_2, p < 0.0001$).

OVERALL IMPACT. The total impact of contrast (change in drugs, procedures, or both) was seen in 225 patients or 35.6% of suboptimal quality studies (Fig. 6). The highest impact by location of patients was seen in the SICU ($n = 64$; 62.7% of SICU contrast studies), followed by MICU and inpatient wards, and least in the outpatient setting ($H_0: p = 0, \text{all } p < 0.0001$) (Fig. 6). Importantly, the degree of impact was related to the extent of endocardial visualization (excluding patients with suspected thrombi): as the number of nonvisualized segments increased, the degree of impact increased, with the highest impact of 93.6% seen in patients with >12 nonvisualized segments on unenhanced images (chi-square, $p < 0.0005$) (Fig. 7).

Cost benefit and cost-effectiveness analysis. According to the Medicare fee schedule for 2008, the total charges of contrast administration for the entire cohort of 632 patients was \$39,184. The total cost of the diagnostic procedures that were avoided (both TEE and nuclear testing) in the

cohort was \$116,094. Thus a savings of \$76,910 in the 632 patients was realized with utilization of contrast, with an average savings or diagnostic cost-benefit of \$122 per patient. When evaluating diagnostic cost effectiveness, a total of 207 procedures were avoided; thus, \$189 was spent to avoid 1 additional diagnostic procedure of TEE or nuclear testing.

Safety. Of the 545 hospitalized inpatients and 87 outpatients, 5 complained of back pain after contrast administration. There were no anaphylactoid reactions, hypotension, chest pain, acute myocardial infarction, or significant reported arrhythmias requiring intervention in the ensuing 24 h. There was 1 death in a 78-year-old patient who had a large acute myocardial infarction after knee replacement, severe hypotension, and recurrent ventricular tachycardia within the 24 h before the echocardiographic study. Contrast echocardiography to evaluate ventricular function showed severe LV dysfunction. After contrast administration, there was no change in the patient's vital signs or electrocardiogram. He died 5 h later of continued severe heart failure.

Discussion

The present investigation shows that, in addition to improving overall study quality and LV function assessment, contrast enhancement results in a significant impact on patient management. This was evident in both the reduction in the number of additional diagnostic procedures and in the significant alteration in medical management. The impact of contrast enhancement is inversely related to the

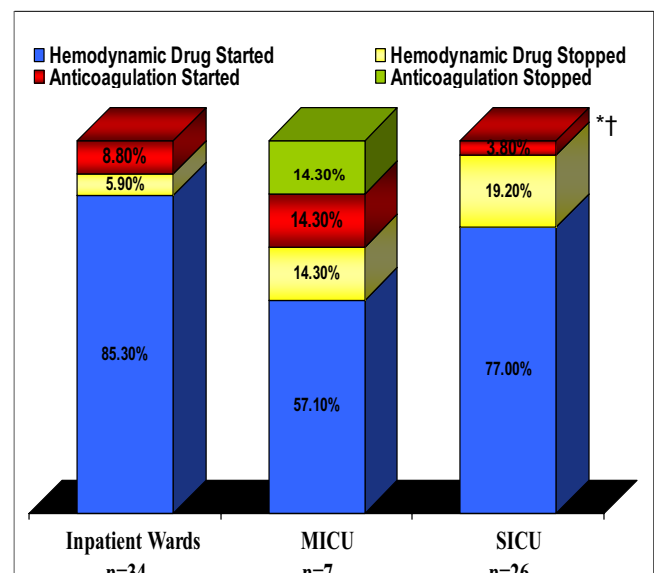


Figure 5 Impact of Contrast on Medication Changes

Frequency of changes in hemodynamic drugs and anticoagulation observed by patient location. * $p < 0.0001$ comparing SICU with inpatients. † $p < 0.0001$ comparing SICU with MICU. Abbreviations as in Figure 1.

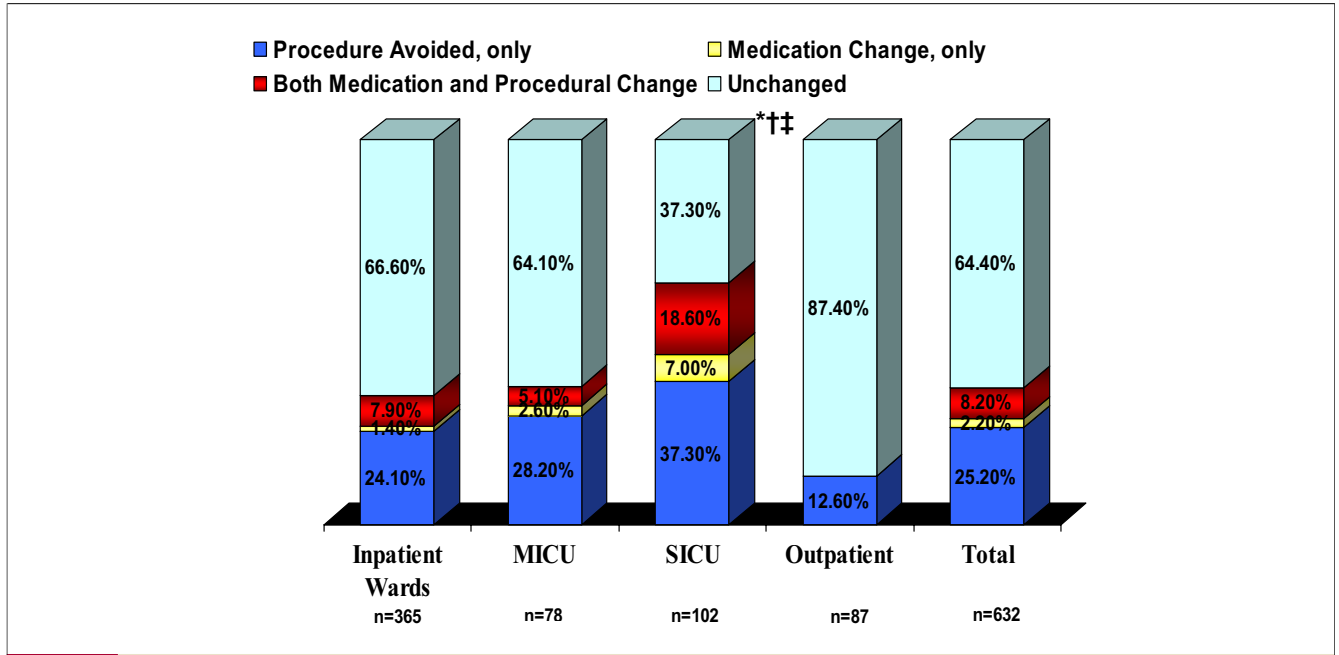


Figure 6 Total Impact of Contrast on Patient Management

Frequency of total impact of contrast use on patient management. The highest impact was observed in inpatients, particularly in the SICU. *p < 0.0001 comparing SICU with inpatient ward. †p < 0.0001 comparing SICU with outpatients. ‡p = 0.0004 comparing SICU and MICU. Abbreviations as in Figure 1.

quality of the unenhanced echocardiographic study and is most pronounced in critically ill and hospitalized patients. **Impact of contrast on study quality and evaluation of LV function.** Several studies have shown that the use of contrast improves image quality and allows for a more accurate assessment of LV volumes and ejection fraction, thrombus detection, and a decrease in both intraobserver

and interobserver variability (5,7-9). Improvement in evaluation of LV function is most pronounced in populations in which the baseline echocardiograms are technically very difficult, specifically in the ICU setting (12,13). One study showed an increase in the level of confidence of LVEF assessment from 56% to 91% after CE (10). Costa et al. (11) showed a salvage rate of 77% of nondiagnostic studies. Furthermore, 16.7% of patients had a change of more than 10% in LVEF after contrast enhancement. The present study corroborates these findings, showing a significant decrease in uninterpretable studies from 11.7% to 0.3% after contrast utilization. There was a salvage of 558 studies (88.3%) from technically difficult or uninterpretable studies to adequate studies. Our data also showed a significant change in LVEF in 16.7% of patients with the addition of contrast. Contrast enhancement also allowed the diagnosis of new wall motion abnormalities previously unseen on unenhancement images in 28% of the cohort. As expected, the patient subgroups that received the most benefit from contrast were those with the most suboptimal images at baseline, that is, the critically ill patients, particularly after surgery.

Impact of contrast on patient management. There are very limited data regarding the impact of contrast on patient management and clinical decision making. Thanigaraj et al. (19) evaluated the impact of contrast on management and its cost effectiveness in stress echocardiography, showing a significant decrease in downstream use of nuclear stress testing when contrast was used. To our knowledge, the current study is the first to show the clinical impact of CE

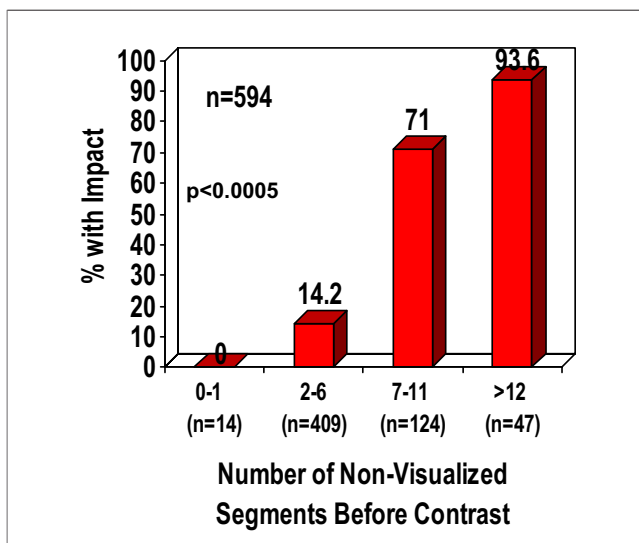


Figure 7 Relation of Extent of Nonvisualized Left Ventricular Segments to Impact of Contrast on Management

The higher the number of segments that could not be visualized, the higher was the impact of contrast echocardiography on management.

in patients with resting echocardiograms used in the routine clinical setting. Similar to Thanigaraj et al. (19), there were no additional procedures ordered to evaluate LV function or segmental wall analysis after contrast enhancement. In addition to avoidance of additional diagnostic procedures such as TEE or radionuclide testing in 32.4% of patients, the impact of contrast also was seen in 10.4% of patients with regard to altering cardiovascular drug regimens, including alteration of anticoagulation in patients with suspected apical thrombus. Thus, a total of 35.6% of patients receiving contrast for technically difficult studies had a significant impact on their clinical care, in terms of avoidance of additional procedures, alteration of medical management, or both.

Patients who are difficult to image with echocardiography are often referred for additional testing to obtain accurate information. Although these modalities can provide accurate information, they may be associated with additional risks, time delays, and costs. Thus, in these technically difficult to image patients, a rapid, simple, inexpensive, and safe test that results in accurate information is desirable. Cost-effective analysis of contrast use has been evaluated previously (19–21). We have previously shown the cost effectiveness of using contrast compared with TEE in select patients referred for TEE because of technically very difficult studies in the ICU (13). Our current results on the impact of contrast on management in consecutive patients requiring CE are concordant with prior data, showing a savings of \$122/patient. Importantly, this cost–benefit analysis is conservative because it addresses downstream utilization of diagnostic procedures alone and does not include the potential effects of adjusting and correcting the initial medical therapy on patient outcome.

Impact of contrast varies with baseline quality of study. An interesting finding from this study is that the impact of contrast on patient management was inversely related to the quality of the baseline study. The greatest degree of improvement in evaluation of LVEF and regional function was seen in the ICU population, especially in the SICU. This same group also had the highest impact of CE on management (62.7%). This finding is important because it supports the use of contrast in patients whose baseline study is suboptimal, using the standard American Society of Echocardiography definition of >2 nonvisualized myocardial segments. Furthermore, it also underlines the importance of contrast use, particularly in hospitalized patients, because the recent initial contraindications to use of contrast outlined by the Federal Drug Administration excluded patients with cardiovascular instability—essentially a majority of patients in the ICUs—from receiving contrast for endocardial enhancement. On May 13, 2008, however, those contraindications were changed to warnings, as more data supporting the safety of CE surfaced (22). The current study further supports the safety and the risk–benefit ratio of contrast agents even in the critically ill setting, where the

majority of contrast utilization in rest echocardiograms is seen.

Study advantages and limitations. The study was performed with a relatively large group of consecutive patients with no patient dropout. In addition, each patient served as their own control, as all patients were evaluated both before and after contrast administration. The assessment of impact was obtained immediately before releasing the pre- and post-contrast image results to the primary physician, and then reviewing the medical chart to confirm these findings. One limitation with the design of this study is a bias from the primary physician. It is conceivable that a given physician may alter his or her responses to the question of patient management the more times he or she were contacted. This bias was unavoidable, but was thought to be small given the large number of physicians (n = 65) involved in the cohort over an extended period of time.

Conclusions

The utilization of CE in technically difficult patients significantly improves endocardial visualization and impacts cardiac diagnosis, resource utilization, and patient management. The improvement in assessment of LV function and impact on management was more pronounced with increasing technical difficulty of the studies, which was more often seen in hospitalized and critically ill patients.

Reprint requests and correspondence: Dr. William A. Zoghbi, Cardiovascular Imaging Institute, The Methodist DeBakey Heart and Vascular Center, 6550 Fannin Street SM677, Houston, Texas 77030. E-mail: wzoghbi@tmhs.org.

REFERENCES

1. Kirkpatrick JN, Lang RM, Fedson SE, Anderson AS, Bednarz J, Spencer KT. Automated border detection on contrast enhanced echocardiographic images. *Int J Cardiol* 2005;103:164–7.
2. Hundley WG, Kizilbash AM, Afridi I, Franco F, Peshock RM, Grayburn PA. Administration of an intravenous perfluorocarbon contrast agent improves echocardiographic determination of left ventricular volumes and ejection fraction: comparison with cine magnetic resonance imaging. *J Am Coll Cardiol* 1998;32:1426–32.
3. Hundley WG, Kizilbash AM, Afridi I, Franco F, Peshock RM, Grayburn PA. Effect of contrast enhancement on transthoracic echocardiographic assessment of left ventricular regional wall motion. *Am J Cardiol* 1999;84:1365–9.
4. Thomson HL, Basmadjian AJ, Rainbird AJ, et al. Contrast echocardiography improves the accuracy and reproducibility of left ventricular remodeling measurements: a prospective, randomly assigned, blinded study. *J Am Coll Cardiol* 2001;38:867–75.
5. Lester SJ, Askew JW, Hurst RT, et al. Contrast echocardiography: experience in a clinical echocardiography laboratory. *J Am Soc Echocardiogr* 2006;19:919–23.
6. Nanda NC, Kitzman DW, Dittrich HC, Hall G. Imagent improves endocardial border delineation, inter-reader agreement, and the accuracy of segmental wall motion assessment. *Echocardiography* 2003;20:151–61.
7. Mansencal N, Nasr IA, Pilliere R, et al. Usefulness of contrast echocardiography for assessment of left ventricular thrombus after acute myocardial infarction. *Am J Cardiol* 2007;99:1667–70.
8. Lafitte S, Dos SP, Kerouani A, Robhan T, Roudaut R. Improved reliability for echocardiographic measurement of left ventricular vol-

- ume using harmonic power imaging mode combined with contrast agent. *Am J Cardiol* 2000;85:1234-8.
9. Lang RM, Mor-Avi V, Zoghbi WA, Senior R, Klein AL, Pearlman AS. The role of contrast enhancement in echocardiographic assessment of left ventricular function. *Am J Cardiol* 2002;90:28J-34J.
 10. Reilly JP, Tunick PA, Timmermans RJ, Stein B, Rosenzweig BP, Kronzon I. Contrast echocardiography clarifies uninterpretable wall motion in intensive care unit patients. *J Am Coll Cardiol* 2000;35:485-90.
 11. Costa JM, Tsutsui JM, Nozawa E, et al. Contrast echocardiography can save nondiagnostic exams in mechanically ventilated patients. *Echocardiography* 2005;22:389-94.
 12. Makaryus AN, Zubrow ME, Gillam LD, et al. Contrast echocardiography improves the diagnostic yield of transthoracic studies performed in the intensive care setting by novice sonographers. *J Am Soc Echocardiogr* 2005;18:475-80.
 13. Yong Y, Wu D, Fernandes V, et al. Diagnostic accuracy and cost-effectiveness of contrast echocardiography on evaluation of cardiac function in technically very difficult patients in the intensive care unit. *Am J Cardiol* 2002;89:711-8.
 14. Senior R, Dwivedi G, Hayat S, Lim TK. Clinical benefits of contrast-enhanced echocardiography during rest and stress examinations. *Eur J Echocardiogr* 2005;6 Suppl 2:S6-13.
 15. New U.S. Food and Drug Administration prescribing information for Definity approved October 10th, 2007. Available at: <http://www.fda.gov/cder/foi/label/2007/021064s007lbl.pdf>. Accessed October 15, 2007.
 16. Lang RM, Bierig M, Devereux RB, et al. Recommendations for chamber quantification: a report from the American Society of Echocardiography's Guidelines and Standards Committee and the Chamber Quantification Writing Group, developed in conjunction with the European Association of Echocardiography, a branch of the European Society of Cardiology. *J Am Soc Echocardiogr* 2005;18:1440-63.
 17. Mulvagh SL, Rakowski H, Vannan MA, et al. American Society of Echocardiography consensus statement on the clinical applications of ultrasonic contrast agents in echocardiography. *J Am Soc Echocardiogr* 2008;21:1179-201.
 18. TrialBlazer Health Enterprises, LLC. Medicare Fee Schedule for Year 2008. Available at: <http://www.trialblazerhealth.com>. Accessed January 11, 2008.
 19. Thanigaraj S, Nease RF Jr., Schechtman KB, Wade RL, Loslo S, Perez JE. Use of contrast for image enhancement during stress echocardiography is cost-effective and reduces additional diagnostic testing. *Am J Cardiol* 2001;87:1430-2.
 20. Tardif JC, Dore A, Chan KL, et al. Economic impact of contrast stress echocardiography on the diagnosis and initial treatment of patients with suspected coronary artery disease. *J Am Soc Echocardiogr* 2002;15:1335-45.
 21. Shaw LJ. Impact of contrast echocardiography on diagnostic algorithms: pharmacoeconomic implications. *Clin Cardiol* 1997;20:139-48.
 22. Kusnetzky LL, Khalid A, Khumri TM, Moe TG, Jones PG, Main ML. Acute mortality in hospitalized patients undergoing echocardiography with and without an ultrasound contrast agent: results in 18,671 consecutive studies. *J Am Coll Cardiol* 2008;51:1704-6.

Key Words: contrast echocardiography ■ impact ■ outcome ■ cost-benefit ■ transesophageal echocardiography.